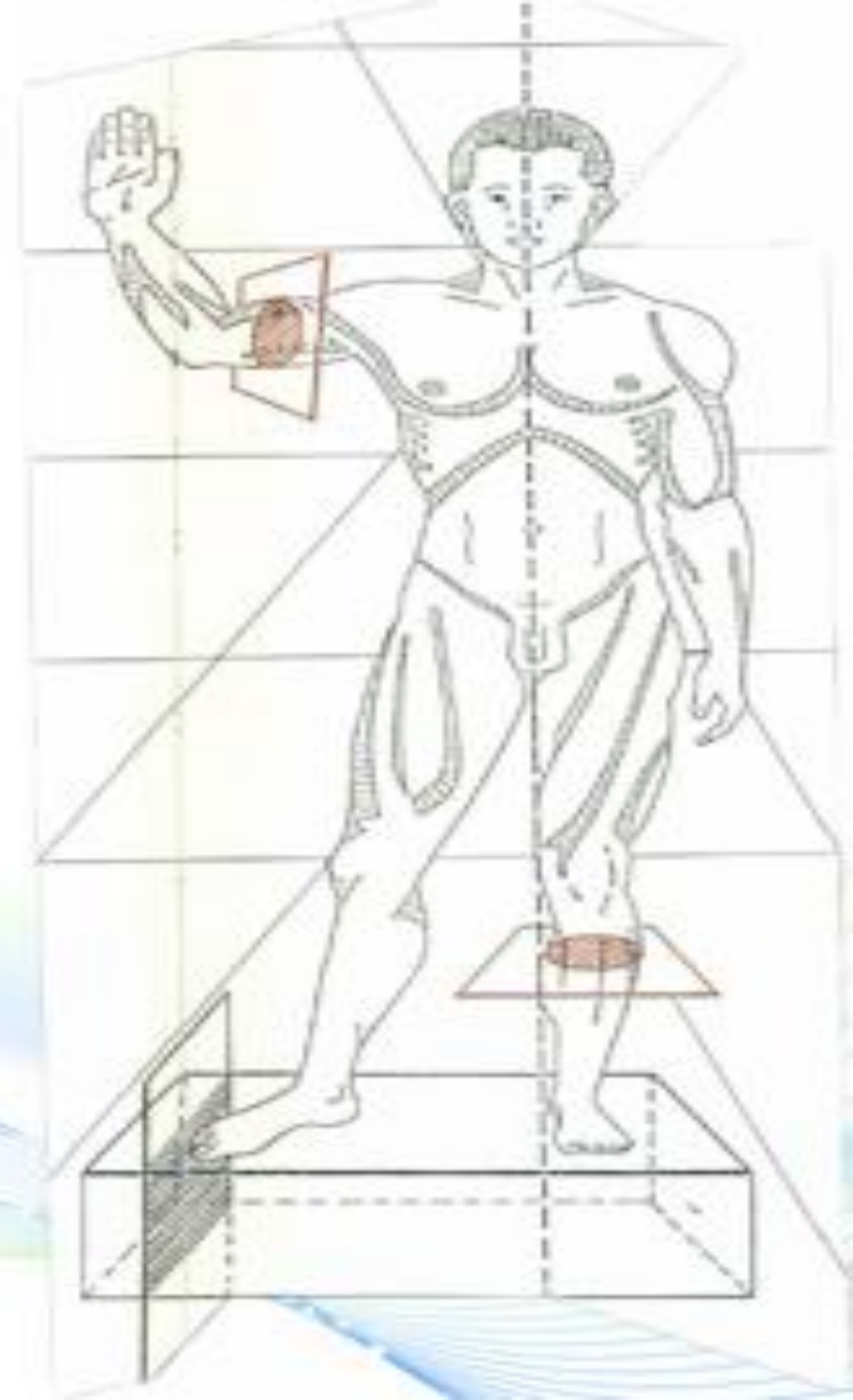


BROAD LIGAMENT

Pr M. D. EL AMRANI

Dr BENTALEB Oussama

Dr ERRAJI Imane



CONTENTS

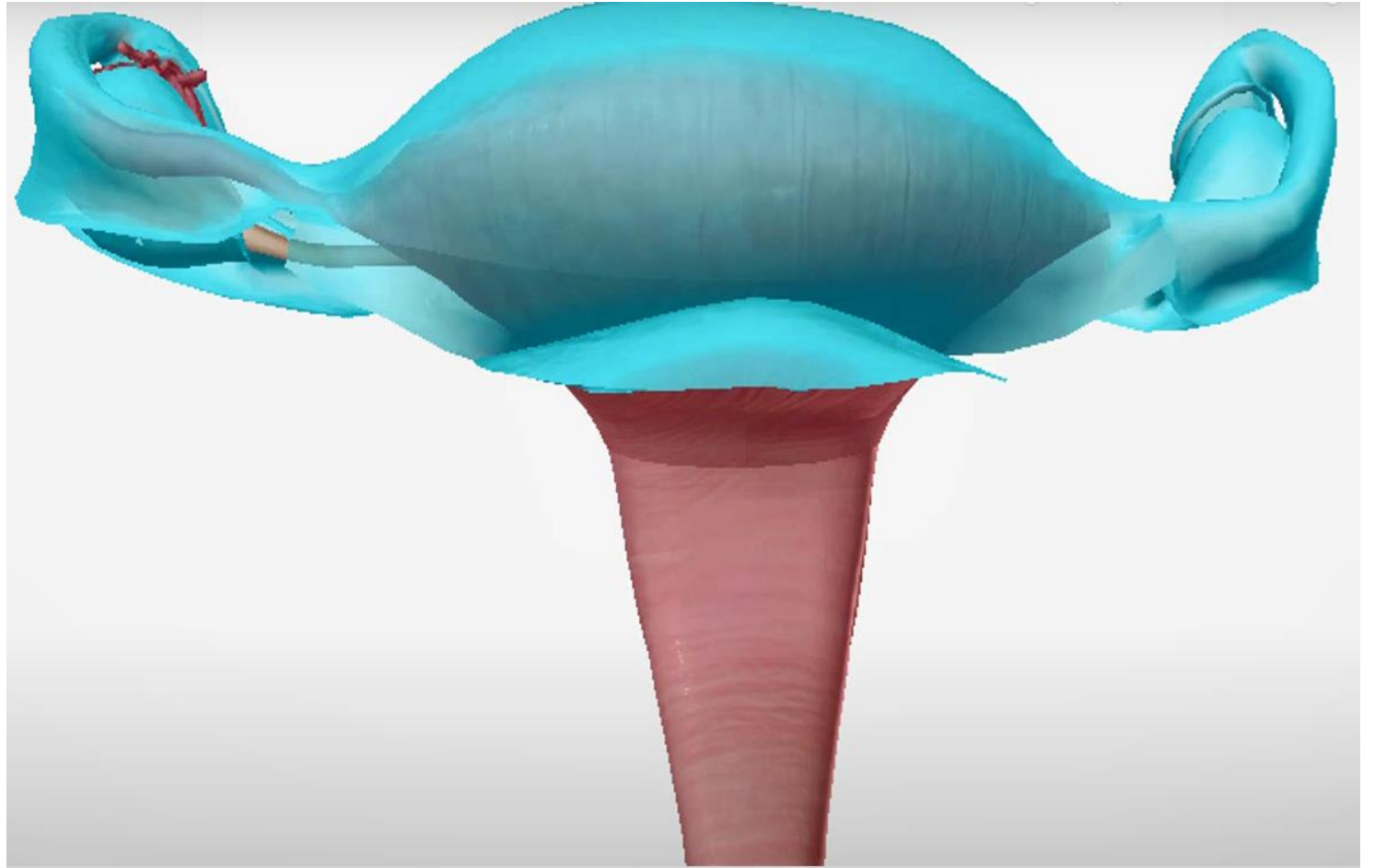
I. INTRODUCTION

II. DESCRIPTIVE ANATOMY

III. STRUCTURE

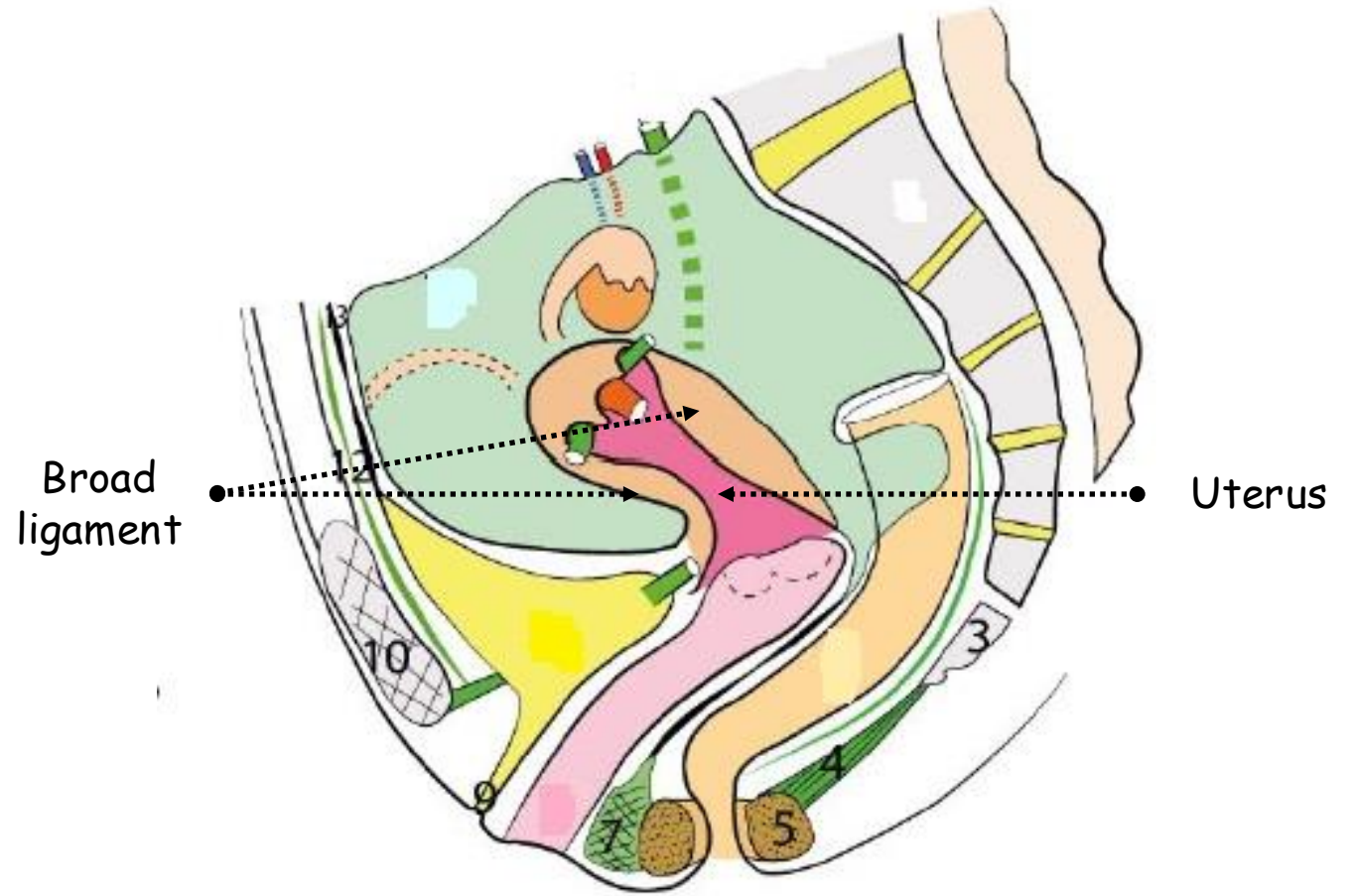
**IV. ANATOMICAL
RELATIONS**

V. CONCLUSION



I. INTRODUCTION

- Paired lax double fold of peritoneum
- Lateral to the uterus
- Little support function

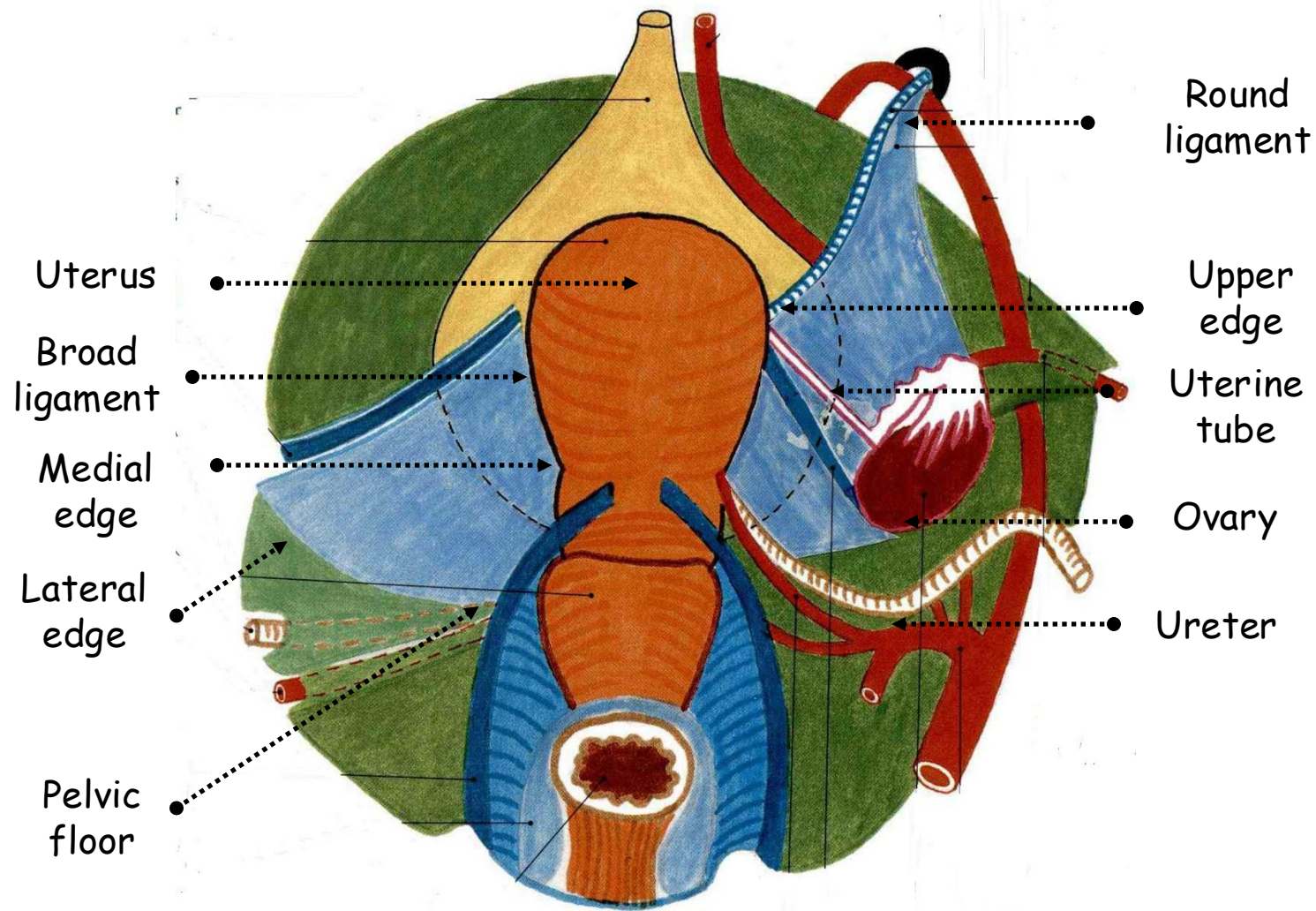


SAGITTAL SECTION OF THE FEMALE PELVIS MINOR
(ACCORDING TO KAMINA)

II. DESCRIPTIVE ANATOMY

A. GENERAL SHAPE

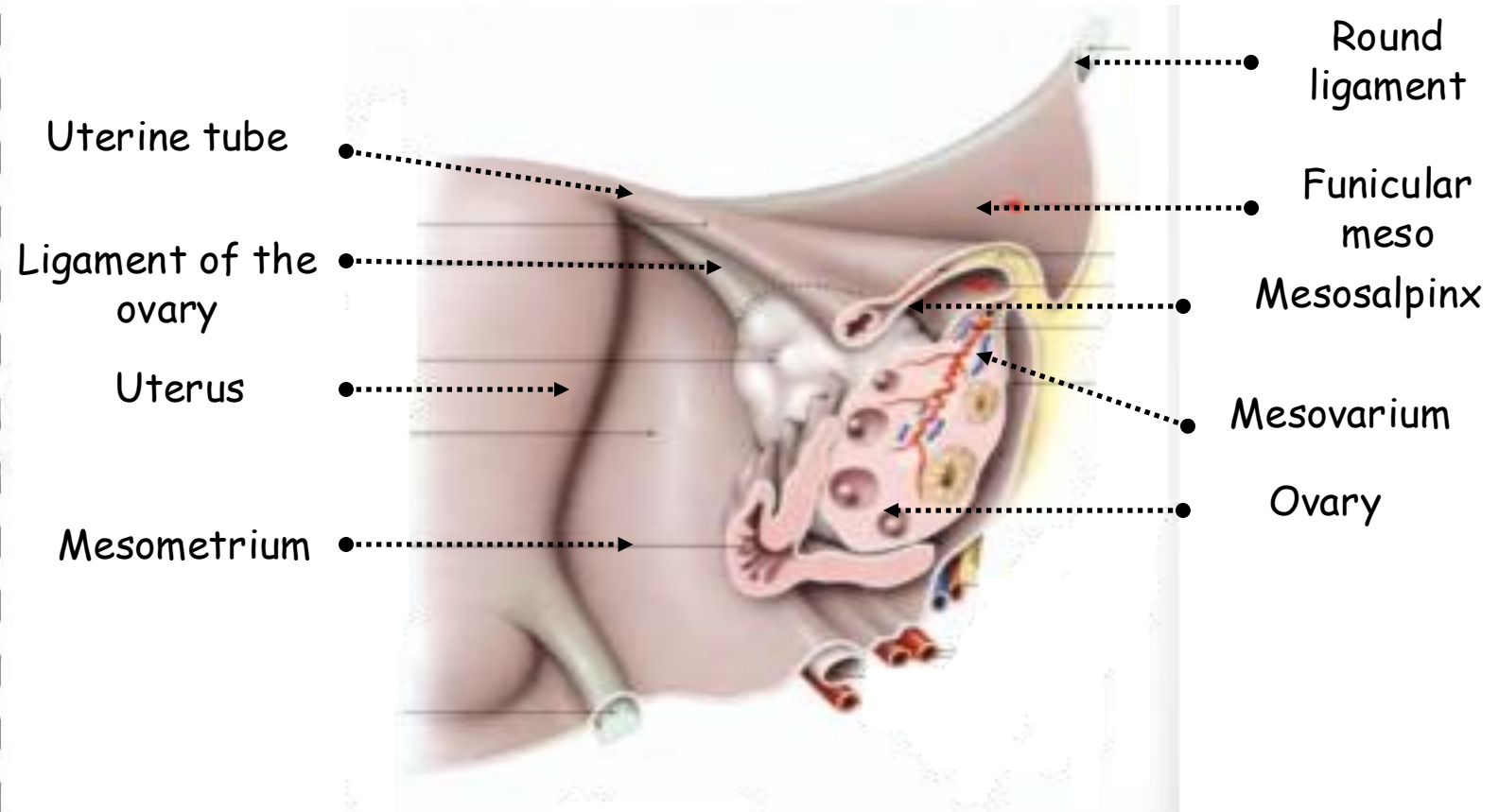
- Double fold of peritoneum lying sagittally from the lateral border of the uterus to the pelvic walls
- **Medial edge:** union of its vesical and intestinal surfaces serous coat at the side wall of the uterus
- **Lateral edge:**
 - Side wall of the pelvis
 - Crosses obturator nerve, umbilical and obturator vessels
- **Base:** lines the pelvic floor
- **Upper edge:**
 - Free
 - Uterine tube
- **Anterior fold:** round ligament
- **Posterior fold:** ovary and ureter



POSTERIOR VIEW OF THE FEMALE INTERNAL GENITAL ORGANS

B. PARTS OF THE BROAD LIGAMENT

- 4 fin-shaped folds
- From front to back
- **Funicular meso:**
 - Raised by the round ligament of uterus
 - Backwards: mesosalpinx
 - Forwards: anterior surface of mesometrium and lateral ligament of the bladder
- **Mesosalpinx:** upwards and lateral continuation of the mesometrium
- **Mesovarium:**
 - Subtended by the ovary and the ligament of the ovary
 - Forwards: mesosalpinx
 - Backwards: posterior surface of mesometrium
- **Mesometrium:** lateral continuation of the perimetrium following the orientation of uterus



POSTERIOR VIEW OF THE UTERUS AND OVARY SHOWING THE LEFT BROAD LIGAMENT (FROM KAMINA)

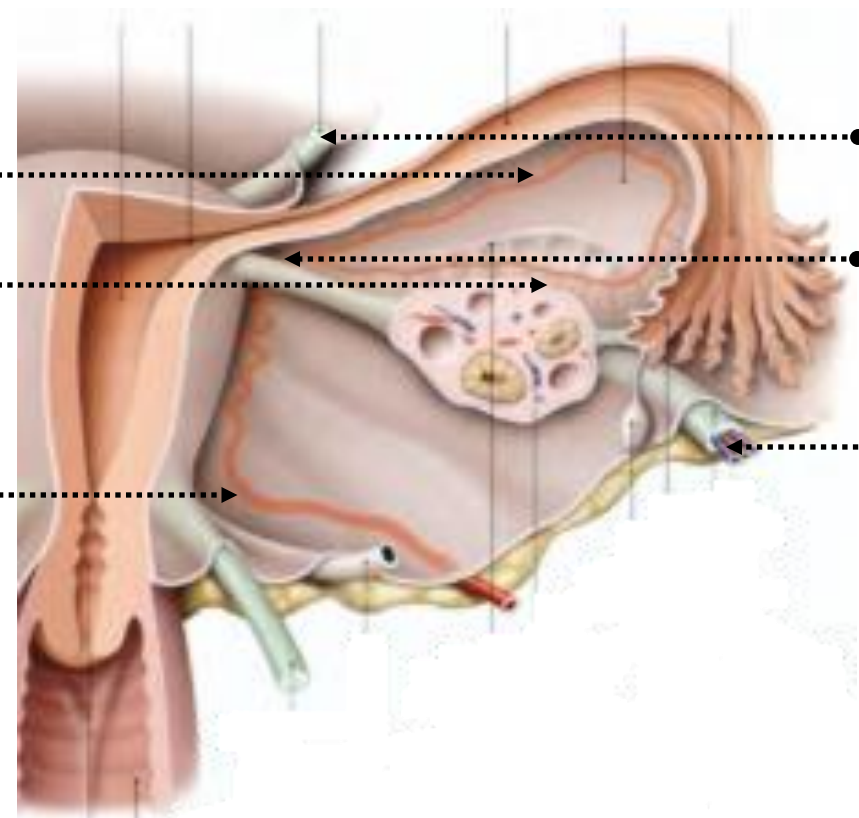
III. STRUCTURE

- Parametrium: areolar tissue
- **Vessels:**
 - Uterine
 - Ovarian
- Lymphatics
- **Ligaments:**
 - Round
 - Of the ovary
- **Embryonic remnants:**
 - Epoophoron
 - Paroophoron

Infratubal
arterial circle

Infra-ovarian
arterial circle

Uterine artery



Round
ligament

Ligament
of the
ovary

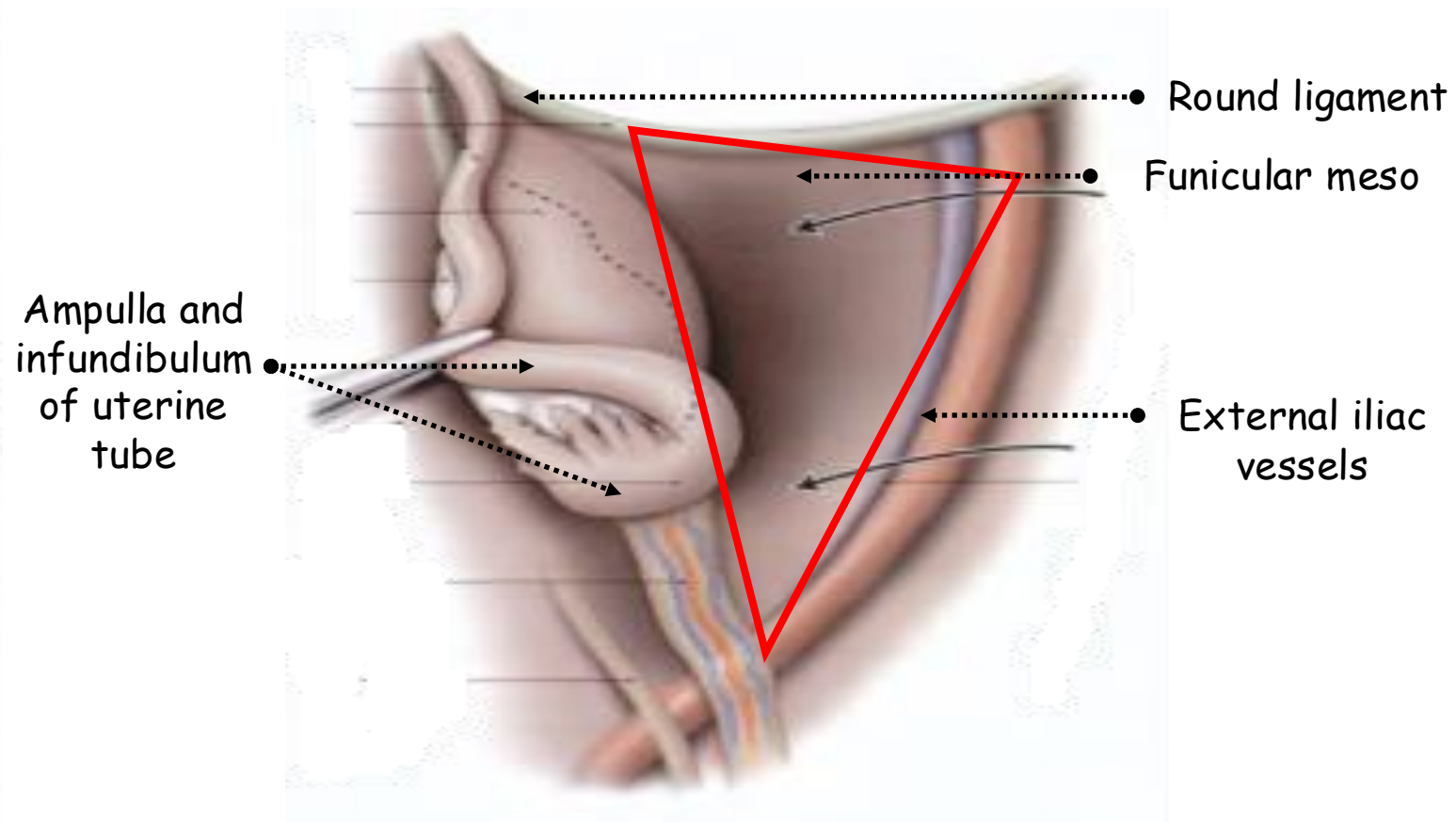
Ovarian
artery

SHEMATIC POSTERIOR VIEW OF THE UTERUS AND OVARY
SHOWING THE LEFT BROAD LIGAMENT (FROM KAMINA)

IV. ANATOMICAL RELATIONS

A. ANTERIOR INFERIOR SURFACE

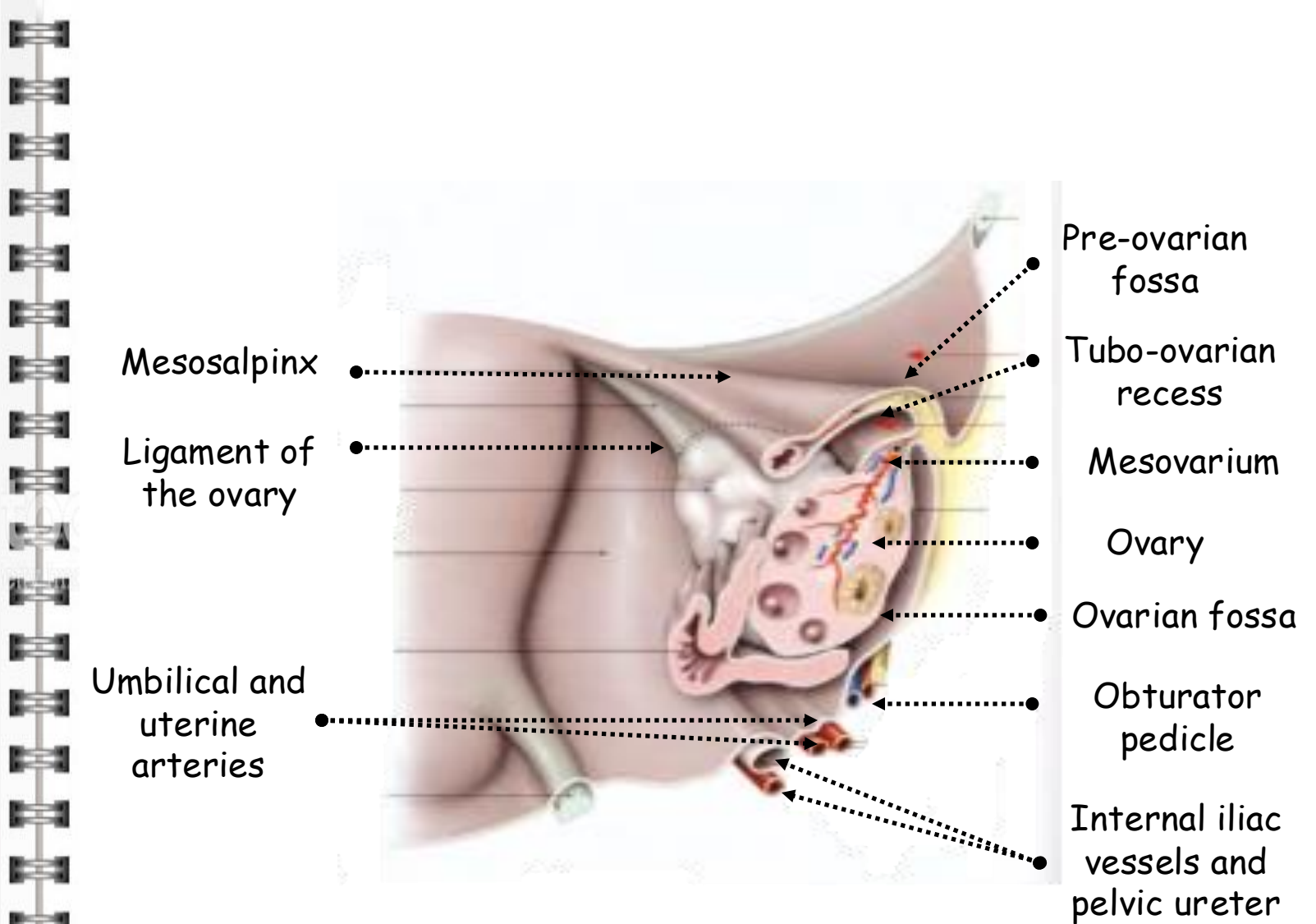
- **Funicular meso:** separates the paravesical fossa forwards from the pre-ovarian fossa backwards
- **Paravesical fossa:**
 - Lateral continuation of the supravesical fossa
 - Intestinal coils
 - Left: sigmoid colon
- **Pre-ovarian fossa:**
 - Triangular
 - Limited outside by external iliac vessels
 - Hidden by the ampulla and infundibulum of uterine tube
 - Pelvic continuation of the iliac fossa
 - Right: cecum and appendix
 - Left: sigmoid colon



POSTERIOR VIEW OF THE PRE-OVARIAN FOSSA (FROM KAMINA)

B. POSTERIOR SUPERIOR SURFACE

- Broader
- **Mesovarium:**
 - Contains the ligament of the ovary, the ovary and the infundibulopelvic ligament
 - Upwards: tubo-ovarian recess
 - Downwards: ovarian fossa
- **Tubo-ovarian recess:**
 - Upwards: mesosalpinx
 - Forwards: pre-ovarian fossa
 - Downwards: mesovarium
- **Ovarian fossa:**
 - Forwards: mesovarium
 - Upwards: external iliac vessels
 - Backwards: internal iliac vessels and pelvic ureter
 - Downwards: origin of umbilical and uterine arteries and obturator pedicle



POSTERIOR VIEW OF THE UTERUS AND OVARY SHOWING THE LEFT BROAD LIGAMENT (FROM KAMINA)

C. UPPER BORDER

- **Mesosalpinx:**
 - Backwards: ovarian fossa
 - Infratubal and infra-ovarian arterial circles
 - Lymphatics
 - Nerves
 - Epoophoron and Paroophoron

C. LOWER BORDER

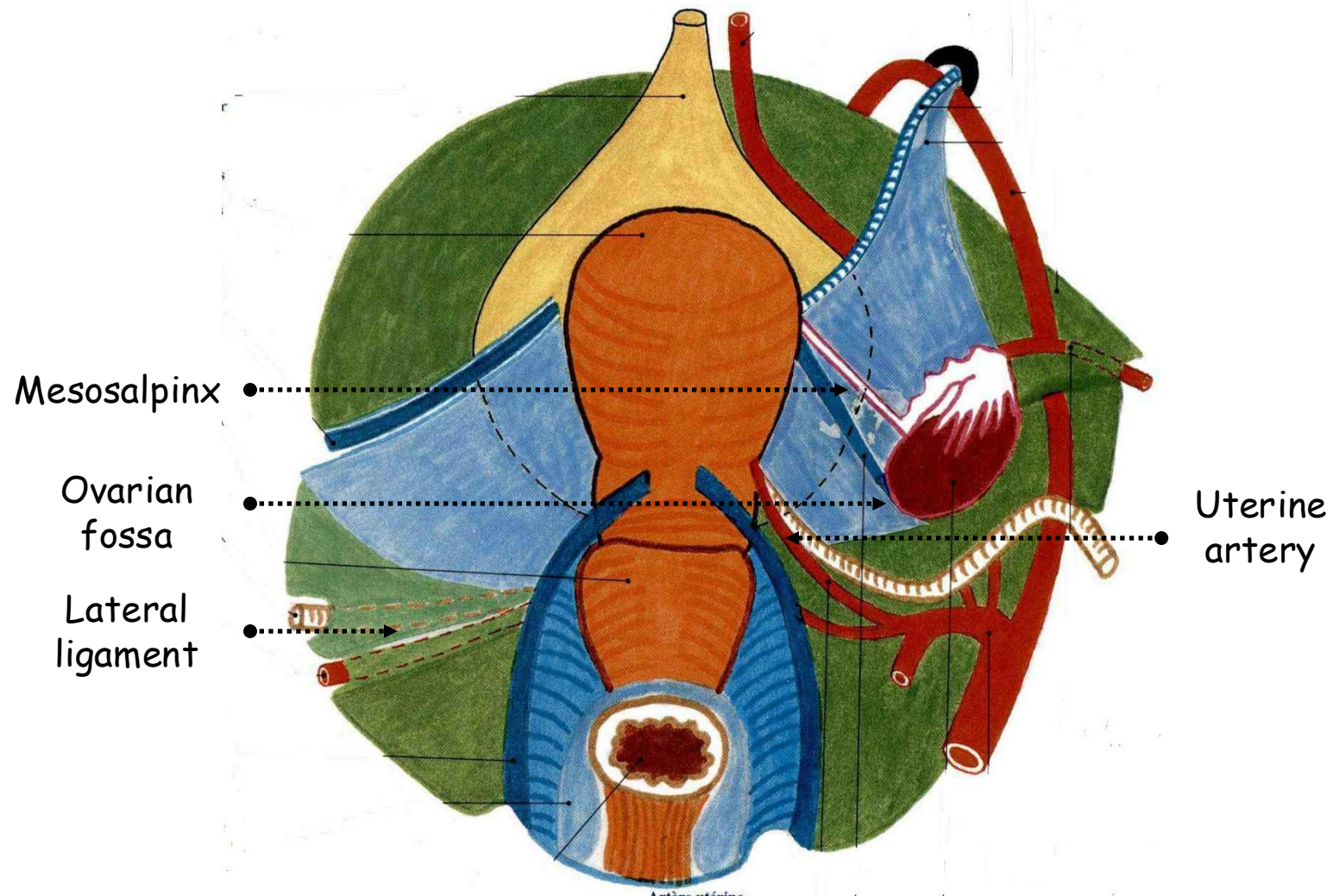
- Lateral ligament
- Pelvic extraperitoneal space

D. MEDIAL BORDER

- Uterine artery and its branches

E. LATERAL BORDER


- Parietal pelvic peritoneum



POSTERIOR VIEW OF THE FEMALE INTERNAL GENITAL ORGANS

VII. CONCLUSION

- Greater omentum of the pelvic cavity
- Rather **compartmenting the pelvic cavity** than supporting its viscera
- Surgical landmark





كلية الطب
والصيدلة - مراكش
FACULTÉ DE MÉDECINE
ET DE PHARMACIE - MARRAKECH

