PHARYNX

Pr M. D. EL AMRANI

Dr BENTALEB Oussama

Dr WAKRIM Hind

CONTENTS

I. INTRODUCTION

- Fibromuscular tube applied to the back of the face in the same way as a respirator is applied to the front of the face
- Its anterior wall is largely deficient so that it has wide communication with the nose, mouth and larynx
- Extends downwards from the base of the skull to the level of C6 vertebra, where it becomes continuous with the oesophagus
- Aerodigestive crossroads
- Communication with the middle ear through the auditory tube
- Main functions:

  -Deglutition

  -Respiration

  -Communication

  -Hearing

II. DESCRIPTIVE ANATOMY

A. SITUATION

- Situated in front of the prevertebral fascia
- Behind the nasal and oral cavities and the larynx
- At the midline
- Extends downwards from the base of the skull to the commencement of the oesophagus towards C6 vertebra and the lower border of cricoid cartilage

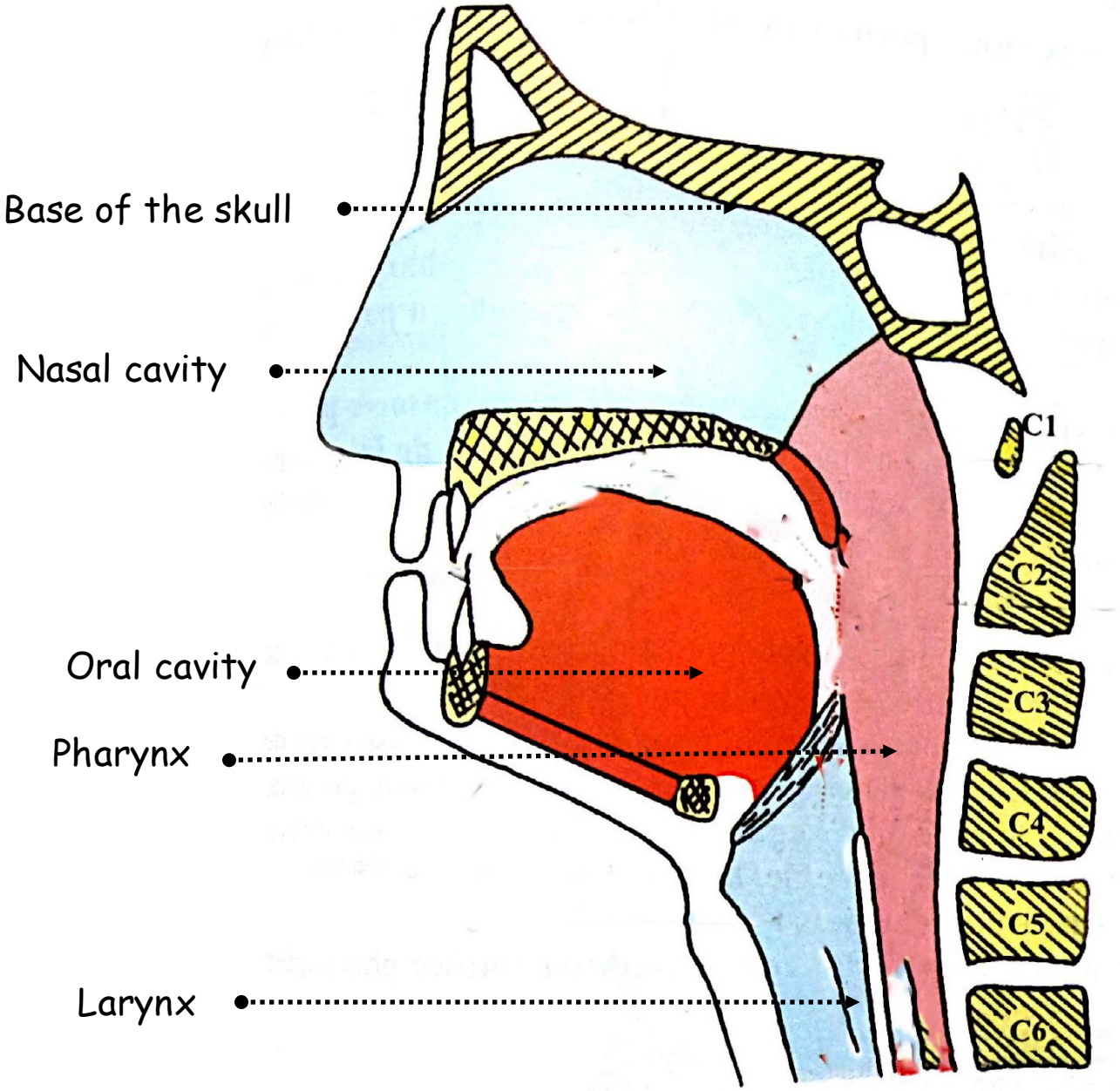

LATERAL VIEW OF THE HEAD AND NECK

B. SHAPE

- Unique and symmetrical
- Funnel-shaped opened in front
- Continuous with the oesophagus at its commencement

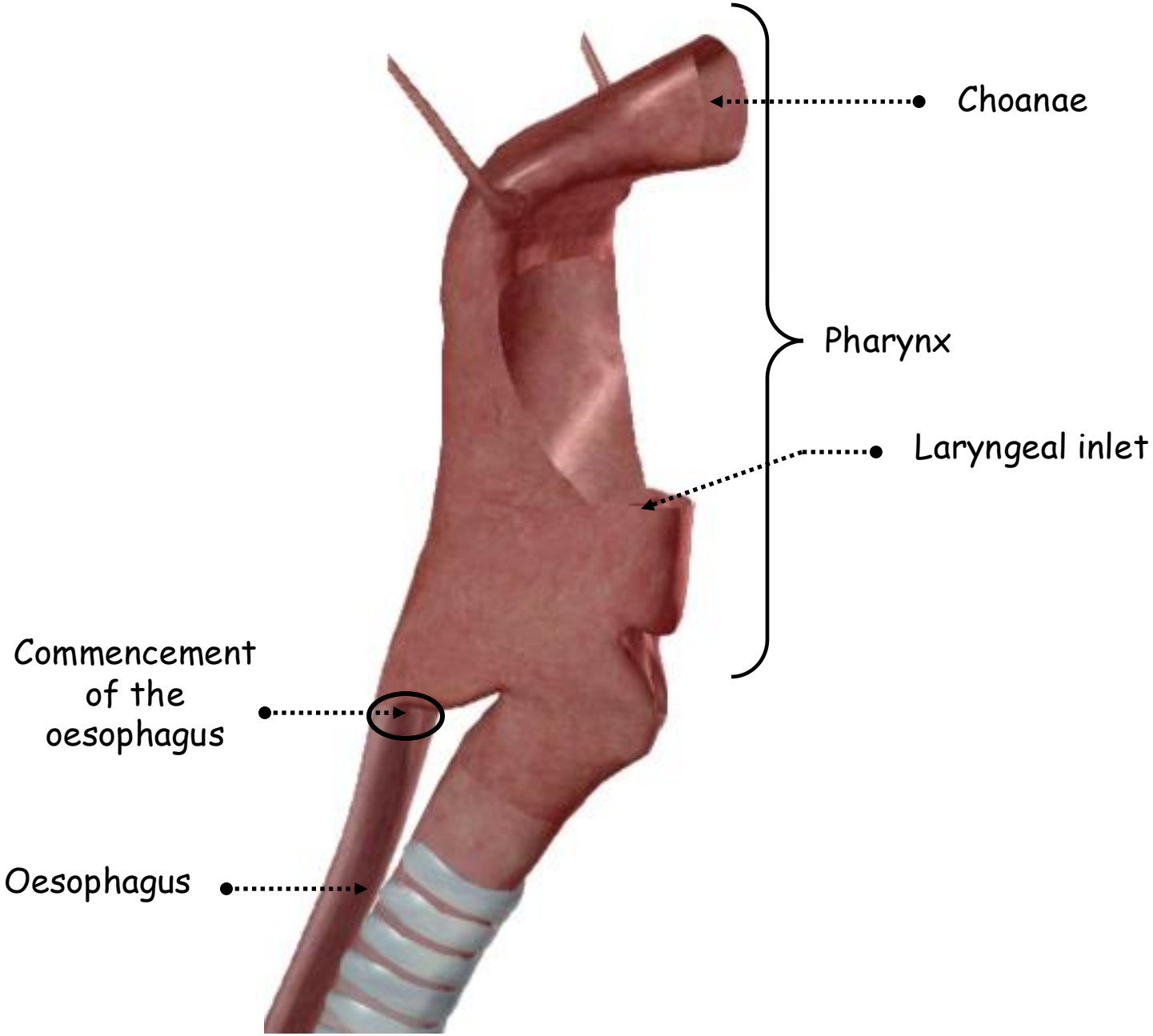

LATERAL VIEW OF THE PHARYNX

C. DIMENSIONS

- Length: 15 cm
- Anteroposterior diameter: at least 2 cm
- Width narrows from top to bottom
- Behind the nasal cavity: 5 cm
- Behind the oral cavity: 4 cm
- Behind the larynx: 2 cm

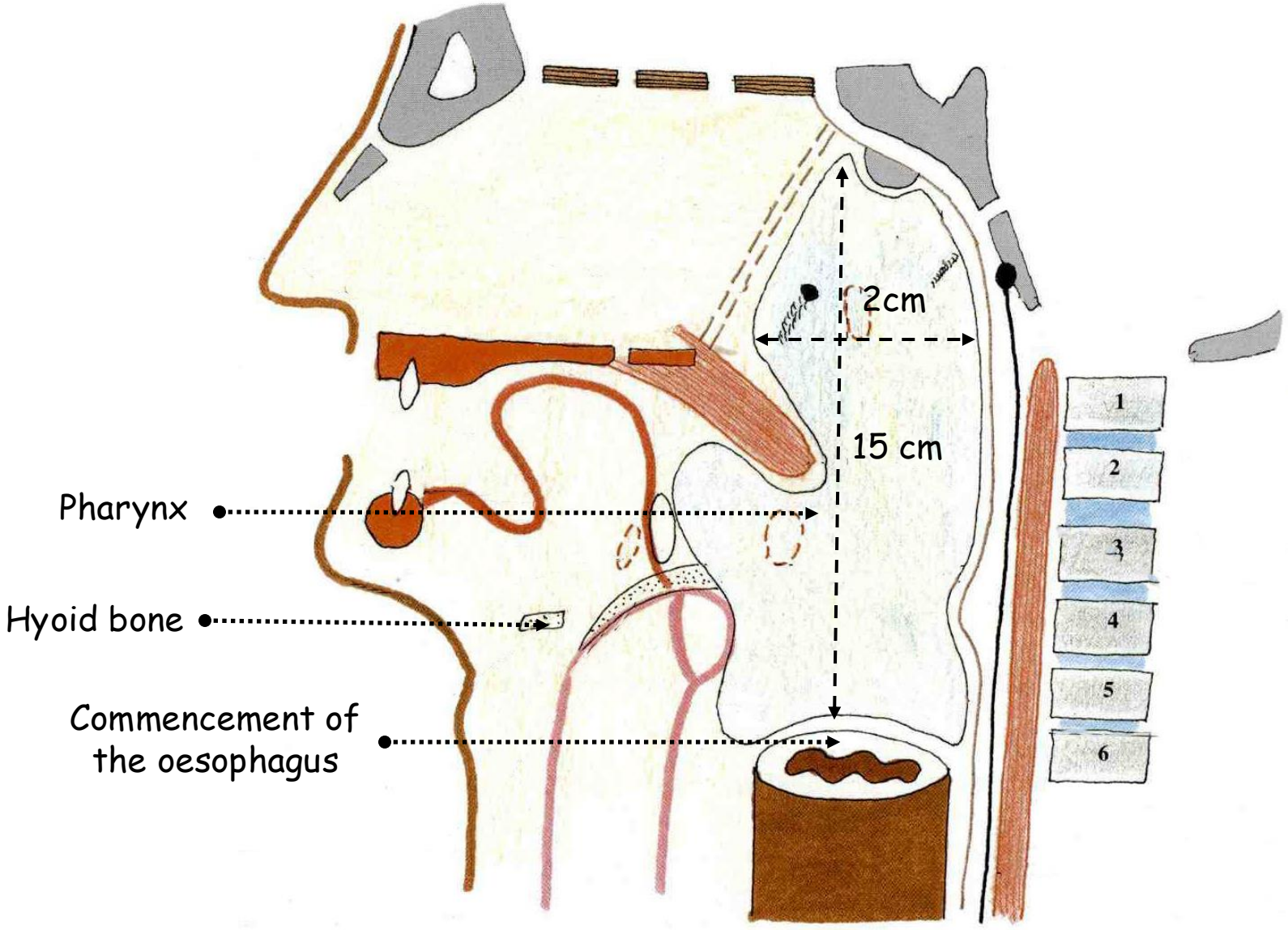

LATERAL VIEW OF THE HEAD AND NECK SHOWING THE PHARYNX

D. PARTS OF THE PHARYNX

- Inspection of the outside of the pharynx gives no hint of its division just as the blank and windowless wall of a tall building
- Soft palate and epiglottis
- 3 parts or levels:
- **Upper:** nasopharynx extends from the base of the skull to the lower border of the soft palate communicates with the nasal cavity
- **Middle:** oropharynx extends from the lower border of the soft palate to the upper border of the epiglottis towards the anterior arch of atlas and C2 and C3 vertebrae communicates with the oral cavity
- **Lower:** laryngopharynx extends from C4 to C6 vertebrae communicates with the larynx

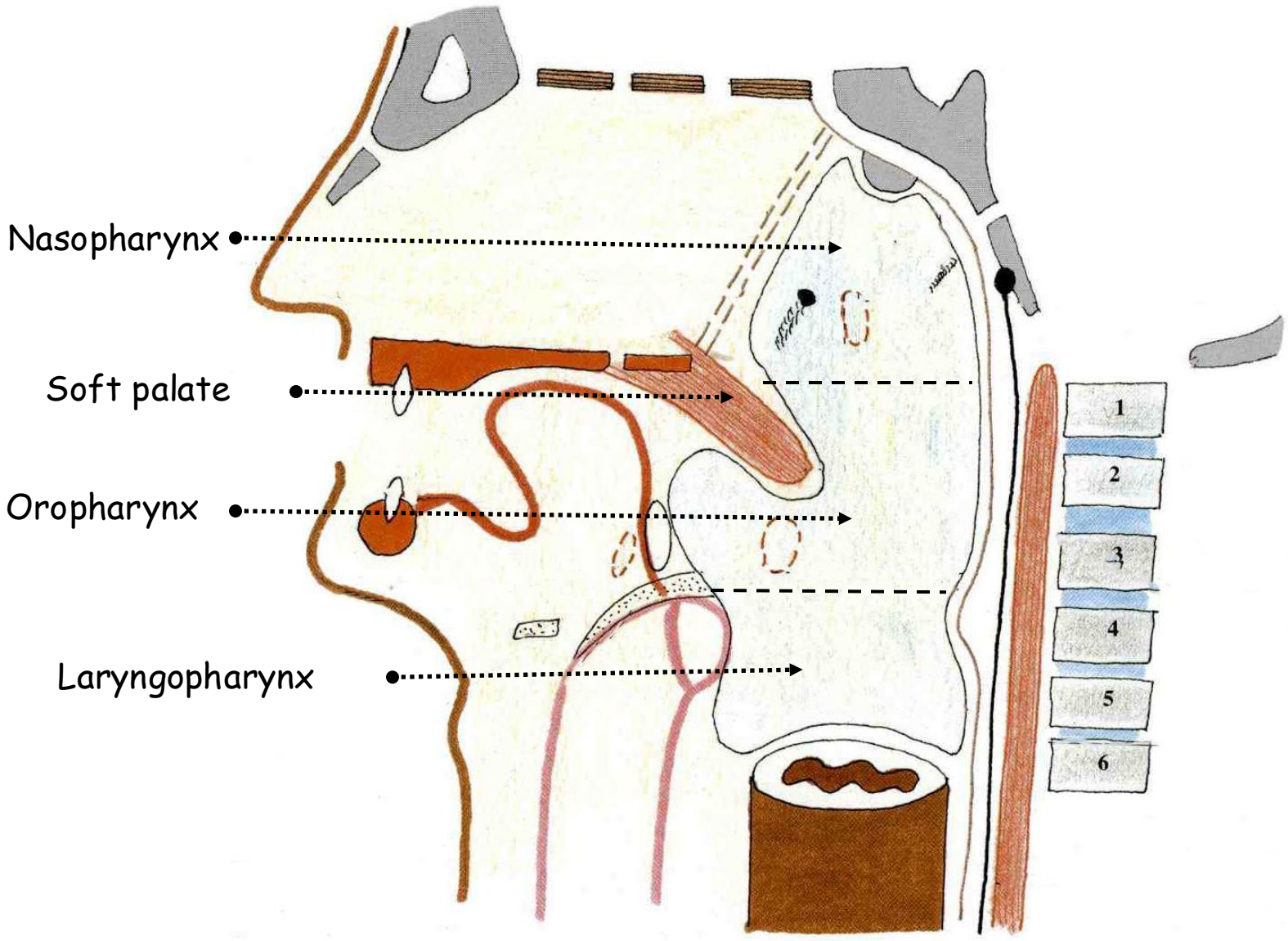

SAGITTAL SECTION OF THE PHARYNX SHOWING ITS THREE PARTS

1. Nasopharynx:

- Strictly aerial
- **Anterior wall:**

-Upper part communicates with the nose through the choanae

-2 oval 3 cm high and 1.5 cm wide openings separated by the vomer

-Below, the soft palate forms its anterior wall

-Oropharyngeal isthmus: space between the lower border of the soft palate and the posterior pharyngeal wall through which the nasopharynx joins the oral part of the pharynx

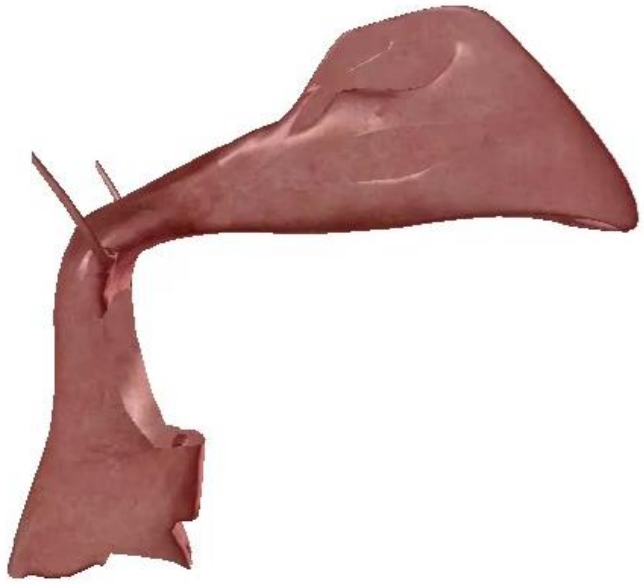

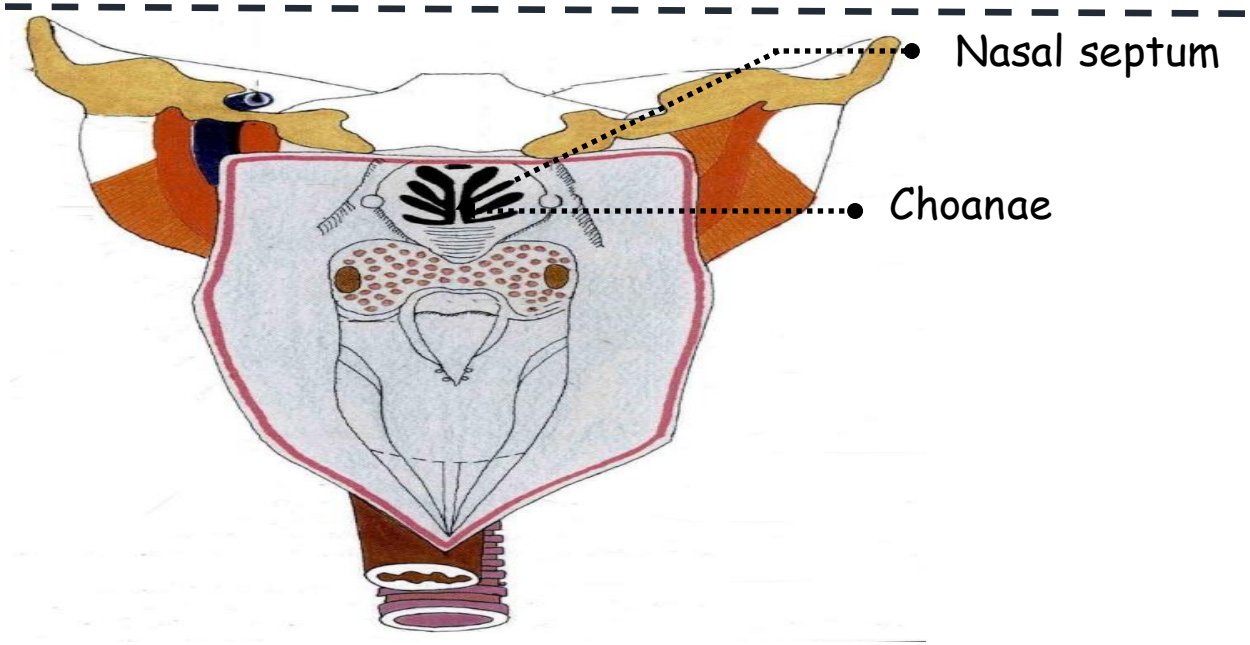

POSTERIOR VIEW OF THE PHARYNX

- **Superior and posterior walls:**
  - -Continuous
  - -Sloping backwards and downwards then vertical
  - -Pharyngeal tonsil: collection of lymphoid nodules prominent in children at the level of the basiocciput

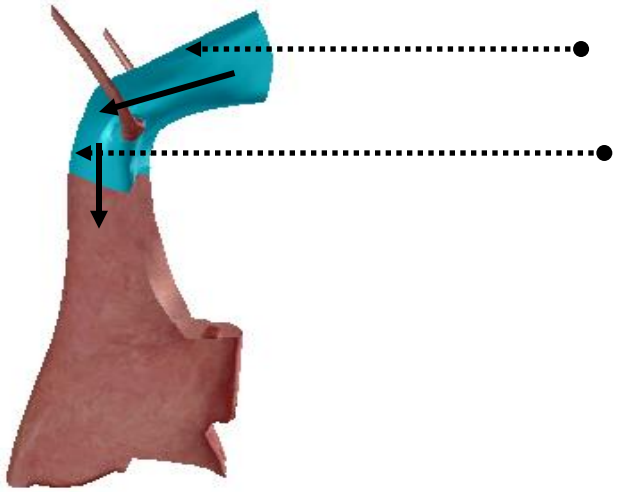

LATERAL VIEW OF THE PHARYNX

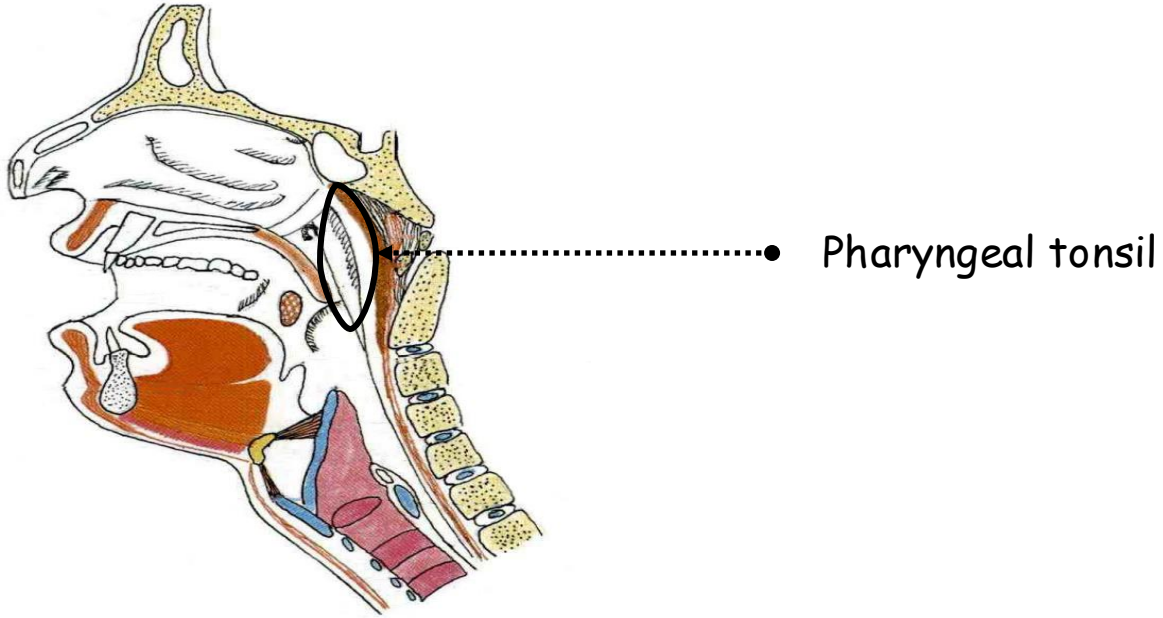

LATERAL VIEW OF THE HEAD AND NECK SHOWING THE PHARYNX

- **Lateral walls:**

  -Pharyngeal recess or fossa of Rossenmuller: narrow vertical slit behind the opening of the auditory tube

  -Opening of the auditory tube: lies above the soft palate guarded above, behind and in front by a prominent rounded ridge, the torus or tubal elevation in the shape of an inverted J, the long limb lying posteriorly and being continued downwards as the salpingopharyngeal fold and below there is a very slight bulge, the levator elevation

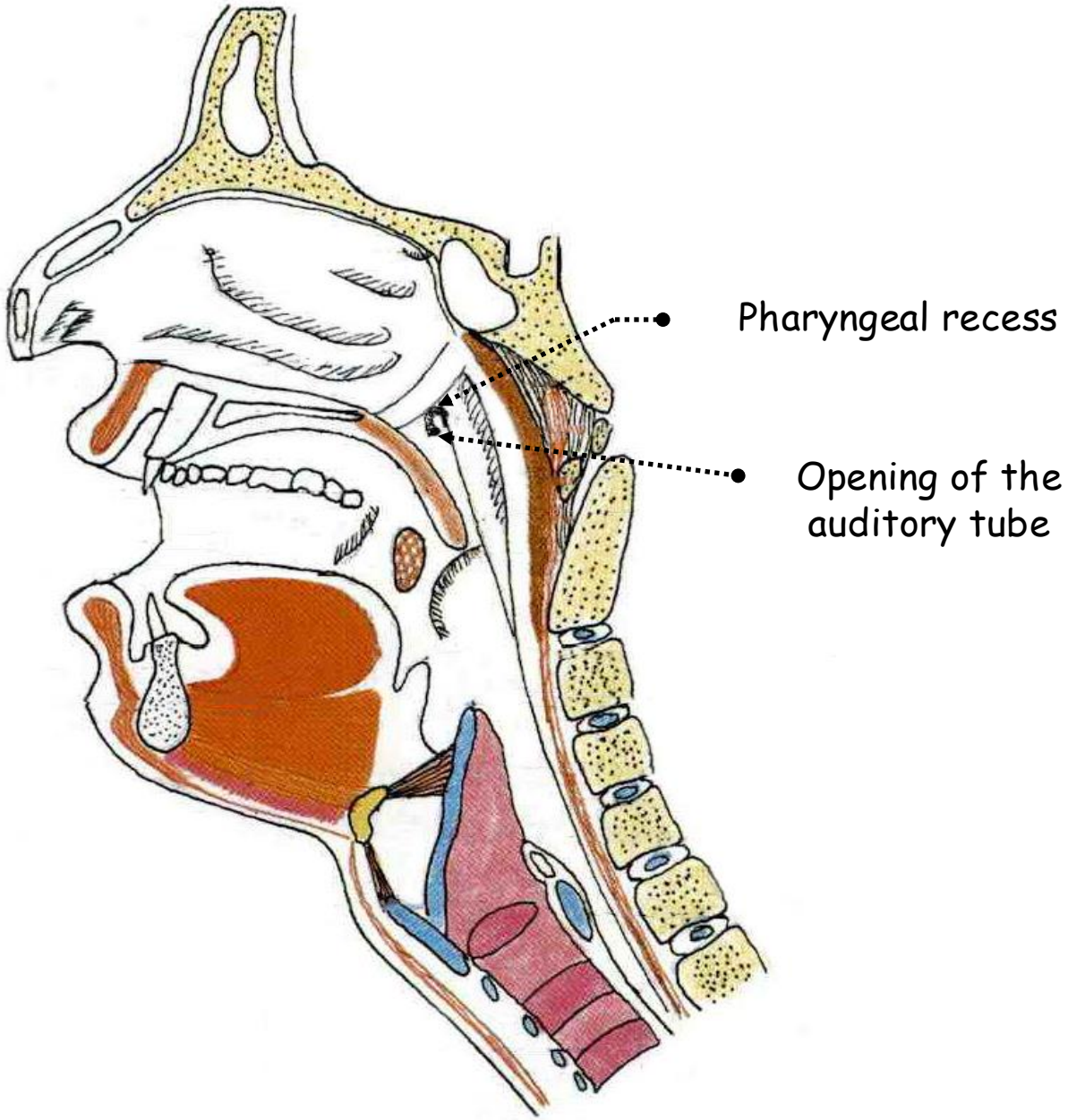

LATERAL VIEW OF THE HEAD AND NECK SHOWING THE PHARYNX

2. Oropharynx:

- Continuous with the oral cavity through the gap between the soft palate and epiglottis
- Limited downwards by the posterior part of the tongue, laterally by the palatoglossal and palatopharyngeal arches, the pillars of the fauces, with the palatine tonsil between them
- The palatoglossal arch constitutes the boundary between the pharynx and the mouth
- Palatine tonsil: paired large collection of lymphoid tissue in the tonsillar fossa opened in its medial face by some twenty crypts and covered by a capsule and a small semilunar fold of mucosa extending from the palatopharyngeal fold to the upper pole of the tonsil

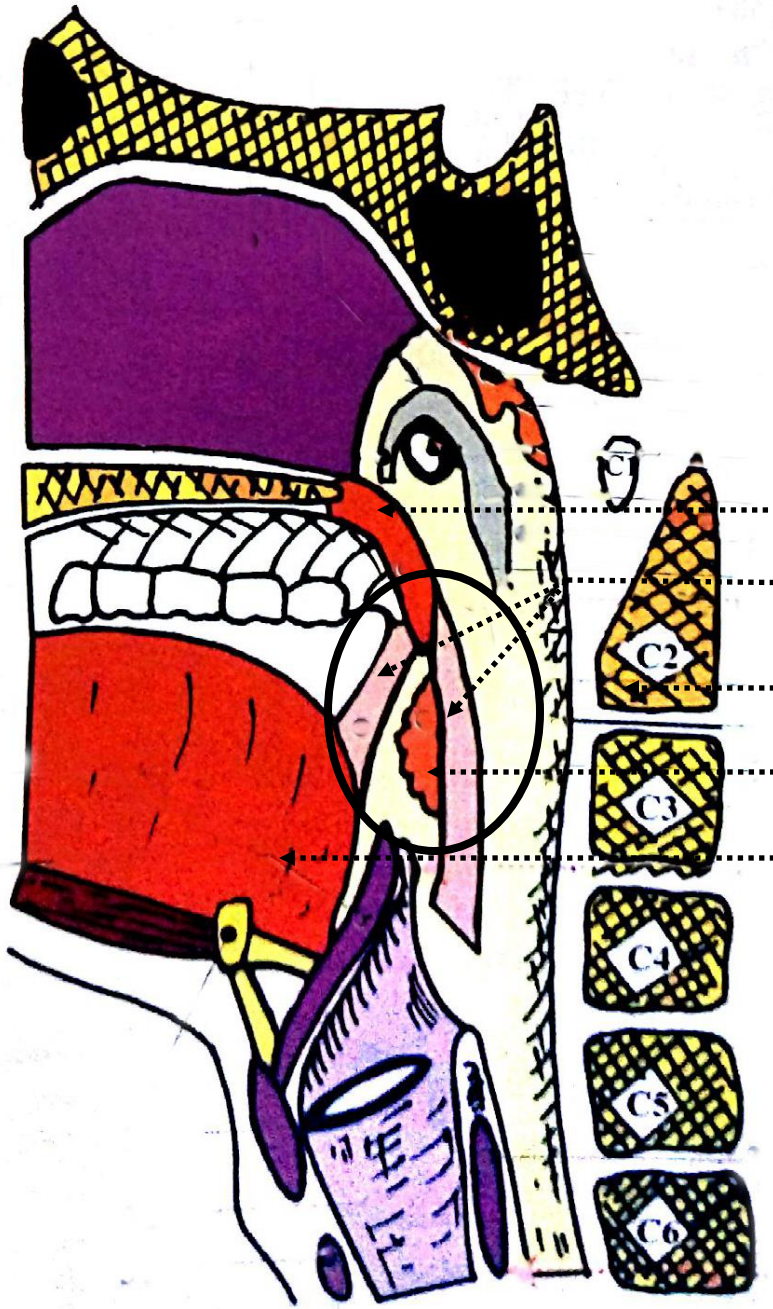

LATERAL VIEW OF THE HEAD AND NECK SHOWING THE PHARYNX

- Valleculae: two shallow pits between the epiglottis and the posterior surface of the tongue limited laterally by the glossoepiglottic folds and separated by the median glossoepiglottic fold
- Soft palate: hangs down from the back of the hard palate as a mobile fold that fuses at the sides with the lateral wall of the pharynx

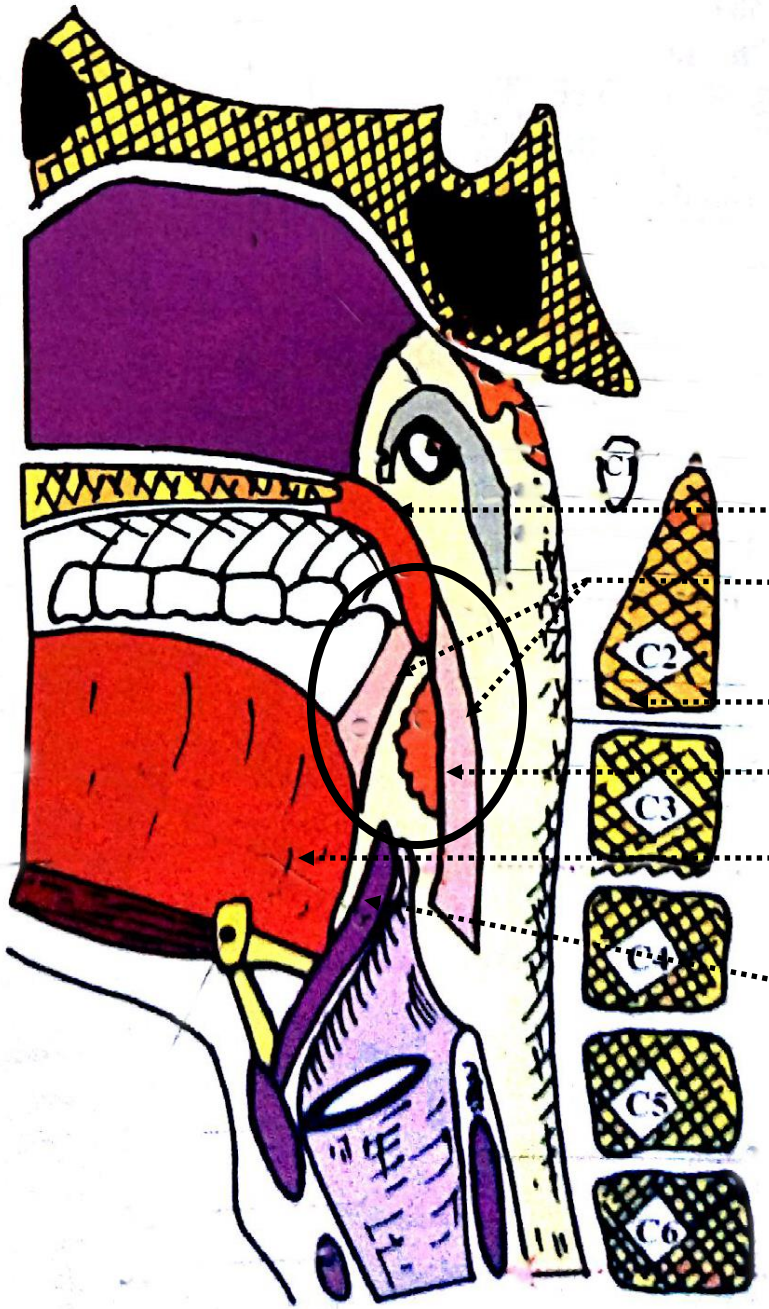

LATERAL VIEW OF THE HEAD AND NECK SHOWING THE PHARYNX

3. Laryngopharynx:

- Extends from the upper border of the epiglottis to the lower border of cricoid cartilage towards C6 vertebra
- Anterior wall: aditus formed of the epiglottis forwards, the aryepiglottic fold backwards and the lateral glossoepiglottic folds laterally separating the laryngopharynx from the oropharynx
- Lateral walls: piriform recesses on either side
- Lower part:
  - -Hypopharynx
  - -Anterior wall flat
  - -Posterior wall: transverse fold that obliterates the piriform recess and constitutes the commencement of the oesophagus

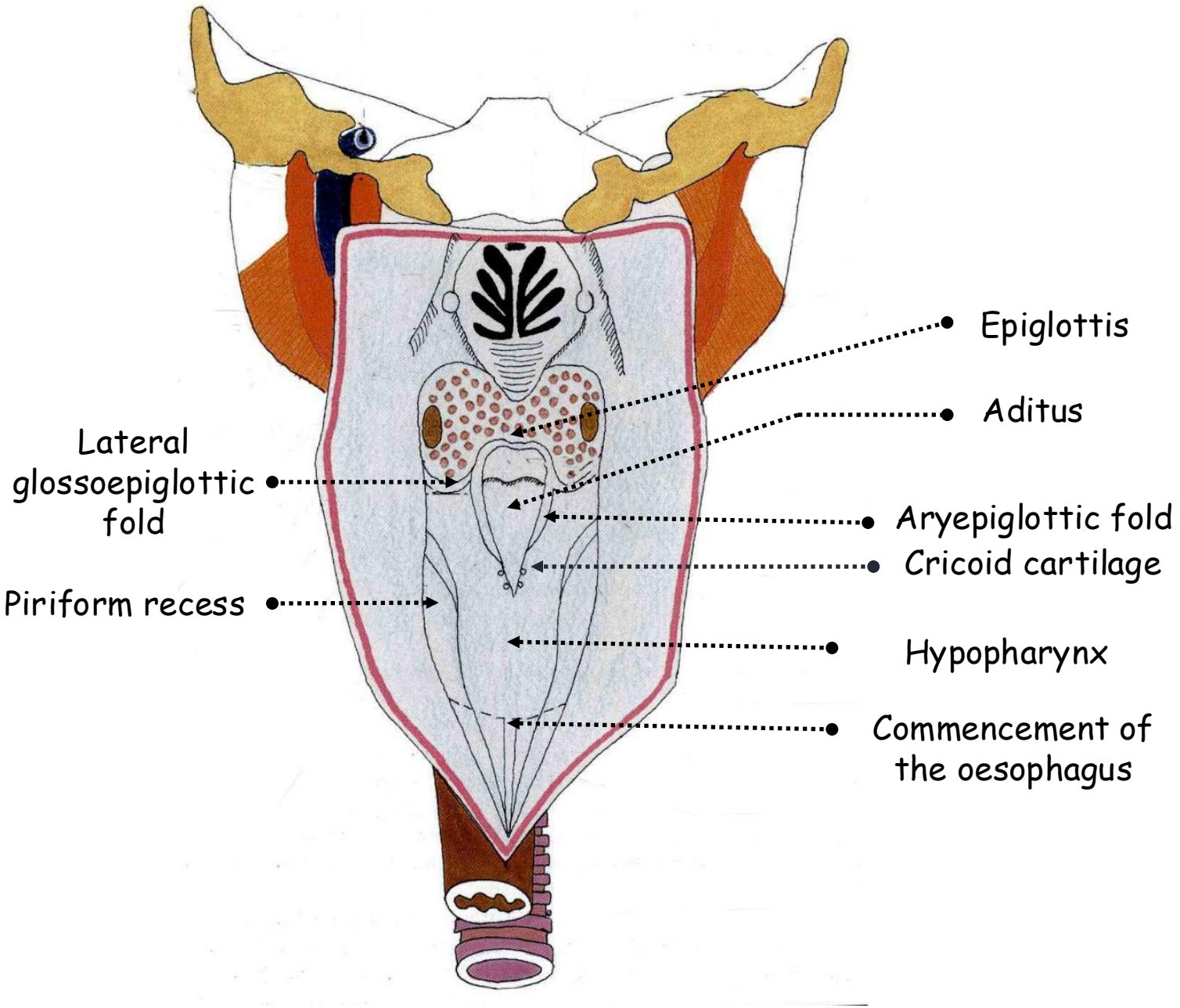

POSTERIOR VIEW OF THE PHARYNX

III. STRUCTURE

- 4 layers
- From outer to inner

A. MUCOUS MEMBRANE

- Squamous non-keratizing epithelium in the oropharynx and laryngopharynx and ciliated columnar epithelium in the nasopharynx
- Submucosa contains mucous glands and lymphoid follicles, pharyngeal tonsil and tubal tonsils towards the tubal elevation in the nasopharynx and lingual tonsils on both sides of the posterior part of the tongue and palatine tonsils in the oropharynx forming the Waldeyer's ring
- Tubal elevation is formed by the trumpet-shaped medial end of the tubal cartilage
- The pillars of the fauces are formed by underlying corresponding muscles
- The soft palate consists of an aponeurosis acted by the pillars muscles as well as the tensor palati, levator palati and muscle of the uvula

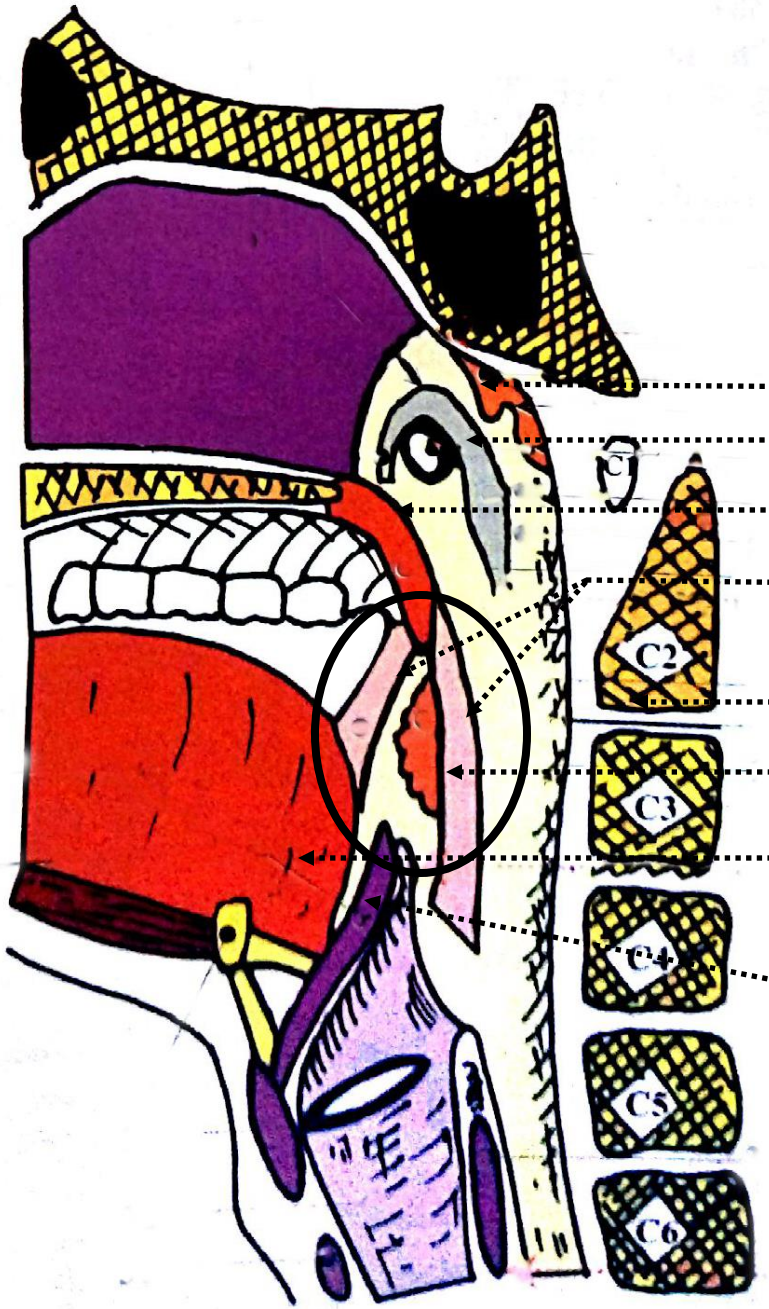

LATERAL VIEW OF THE HEAD AND NECK SHOWING THE PHARYNX

B. PHARYNGOBASILAR FASCIA

- Rigide immobile membrane
- Dense thickening of the submucosa
- Fills in the gap between the skull and the upper border of the superior constrictor
- Aponeurosis of the soft palate
- Keeps the pharynx always open for breathing
- Pharyngeal tubercle : midline thickening, the pharyngeal raphe, receives fibres from the constrictor muscles
- Front of the carotid canal in the petrous part of the temporal bone
- Large recess almost filled by levator palati muscle towards the pharyngeal recess
- Cartilaginous part of the auditory tube below it
- Sharp posterior border of the medial pterygoid plate down to the hamulus
- Site of Passavant's ridge
- Thyrohyoid membrane

C. MUSCULAR WALL

- Surprisingly thin
- Three curved sheets of muscle
- Overlap posteriorly, being telescoped into each other like three stacked cups
- Superior constrictor
- Middle constrictor
- Inferior constrictor
- Supplemented by three smaller muscles: stylopharyngeus, palatopharyngeus and salpingopharyngeus muscles
- Palatoglossus muscle rises the palatoglossal arch
- Palatopharyngeal muscle rises the palatopharyngeal arch

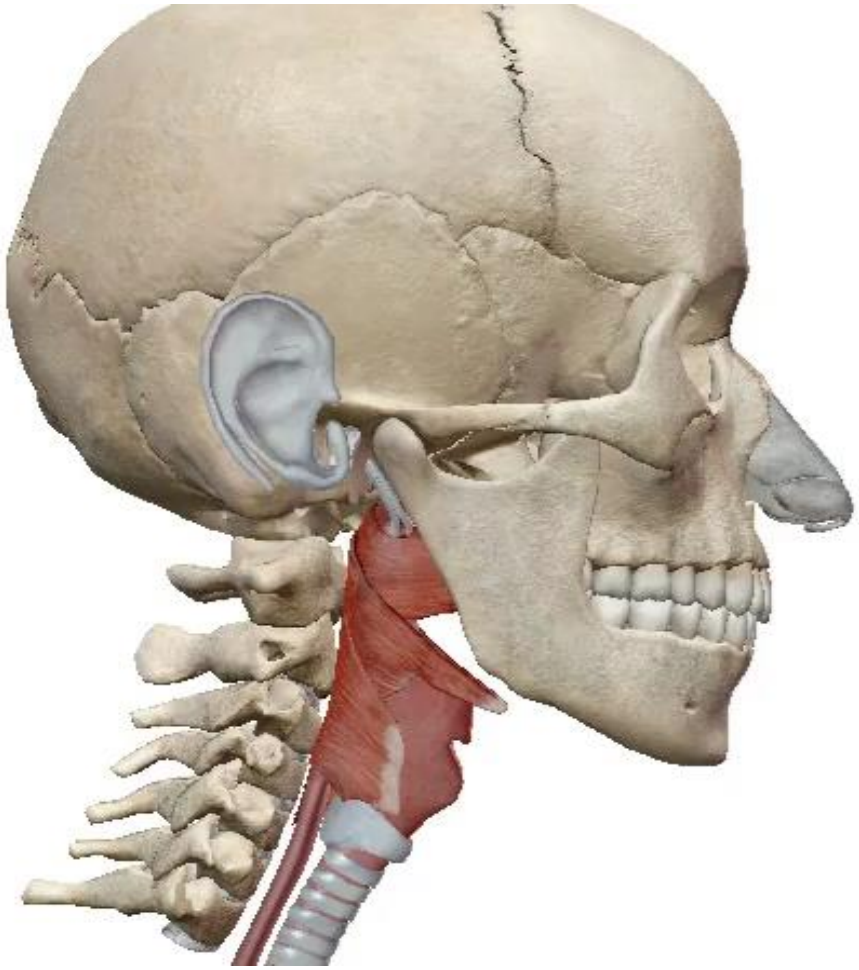

1. Superior constrictor muscle of pharynx:

- Sharp posterior border of the medial pterygoid plate just below the cartilaginous part of the auditory tube down to the hamulus
- The pterygomandibular raphe behind buccinator muscle
- Posterior end of the mylohyoid line towards the posterior border of the last molar tooth
- Sweeps around the pharynx, its fibres diverging mostly upwards to meet their opposite fellows at the midline pharyngeal raphe
- Gap laterally between the superior and middle constrictors plugged by the back of the tongue and traversed by structures that pass from outside the pharynx to inside the mouth, namely stylopharyngeus muscle, the glossopharyngeal nerve and the lingual nerve

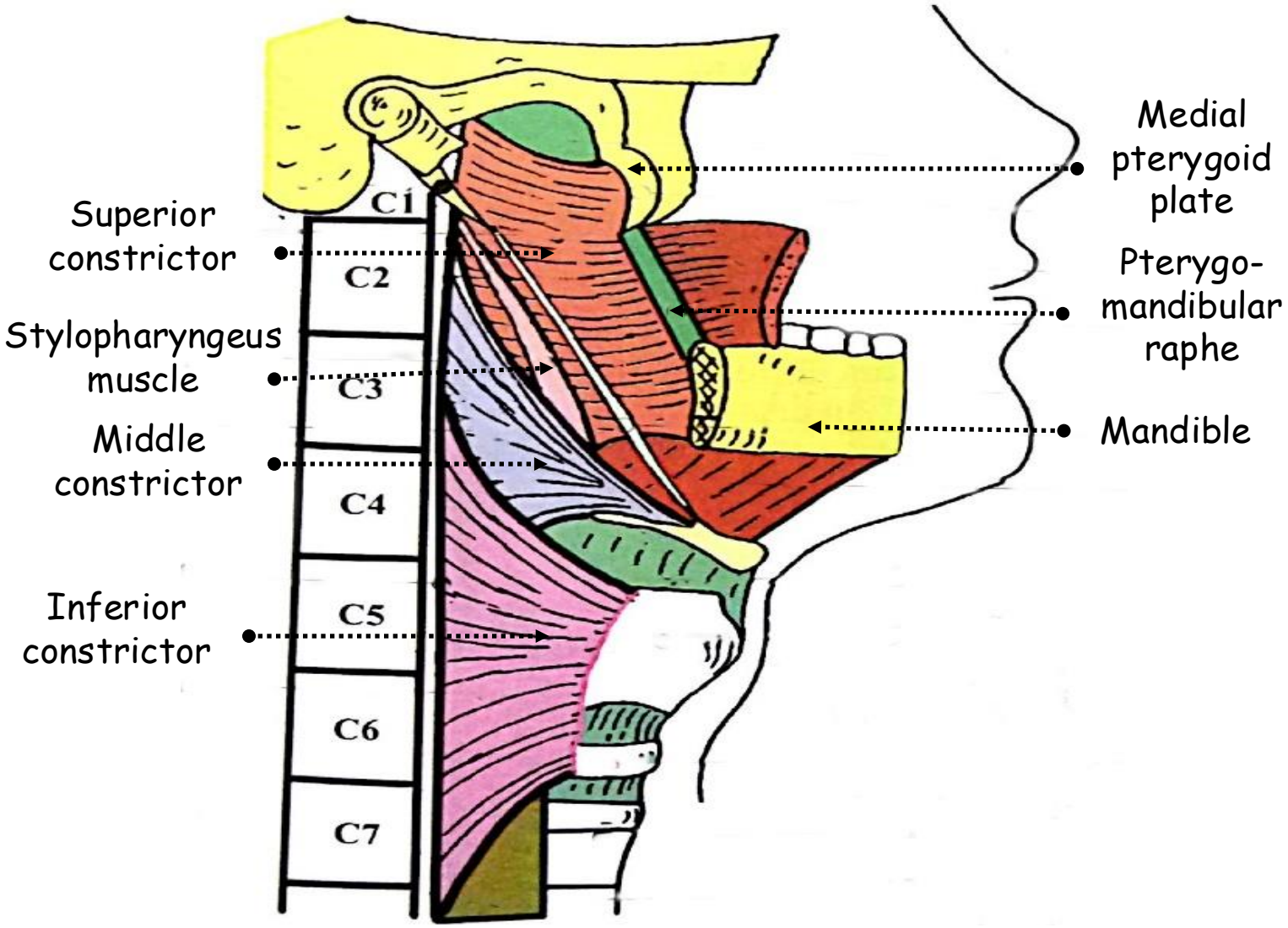

SAGITTAL SECTION OF THE PHARYNX SHOWING ITS MUSCLE WALL

2. Middle constrictor muscle of pharynx:

- Arises from the angle between the stylohyoid ligament on the lesser horn and the greater horn of hyoid bone
- Sweeps around the pharynx to end in the median raphe
- Encloses the superior constrictor and is enclosed by the inferior constrictor
- The gap between the middle and inferior constrictors is closed by the thyrohyoid membrane

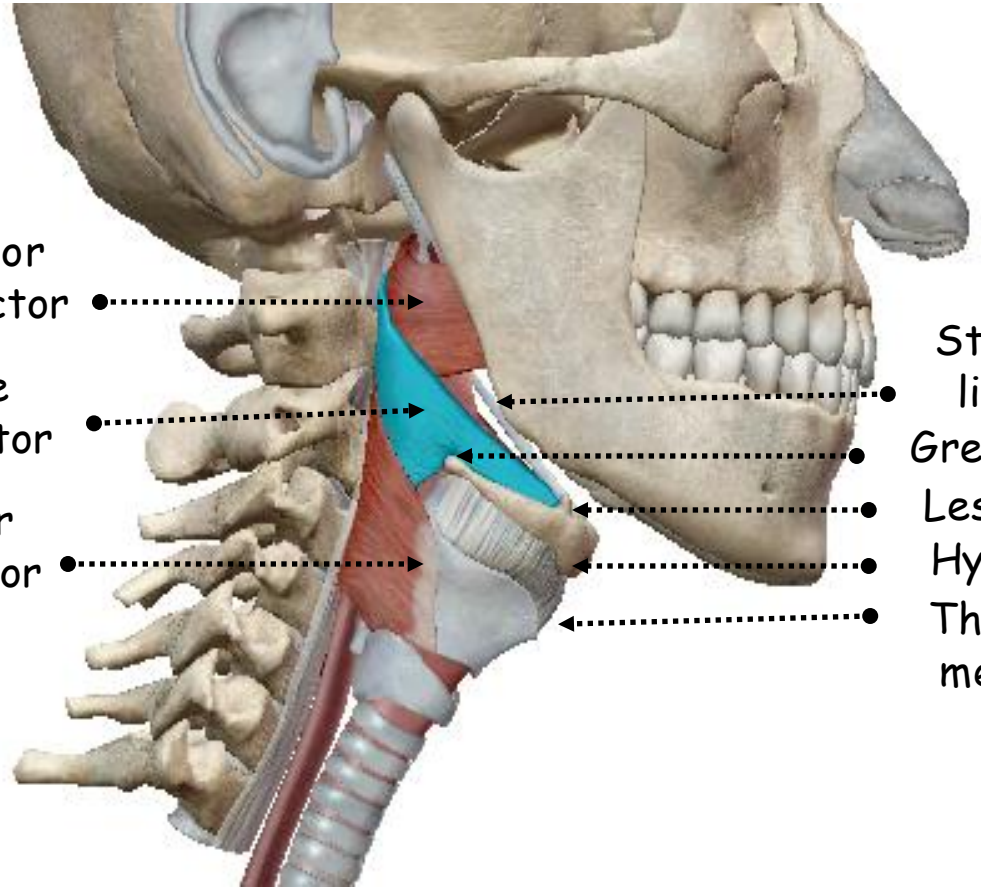

SAGITTAL SECTION OF THE PHARYNX SHOWING ITS MUSCLE WALL

3. Inferior constrictor muscle of pharynx:

- Two parts named from their origins
- Thyropharyngeus part: arises from the oblique line of the thyroid cartilage and in continuity below this from a fibrous arch that spans the cricothyroid muscle and encloses the middle and superior constrictors as its fibres curve around to the midline raphe
- Cricopharyngeus part: rounded and thicker, extends uninterruptedly from one side of the cricoid arch to the other around the pharynx with no raphe and is continuous with the circular muscular coat of the oesophagus for which it acts like a sphincter
- Weak zone between them: Killian's dehiscence

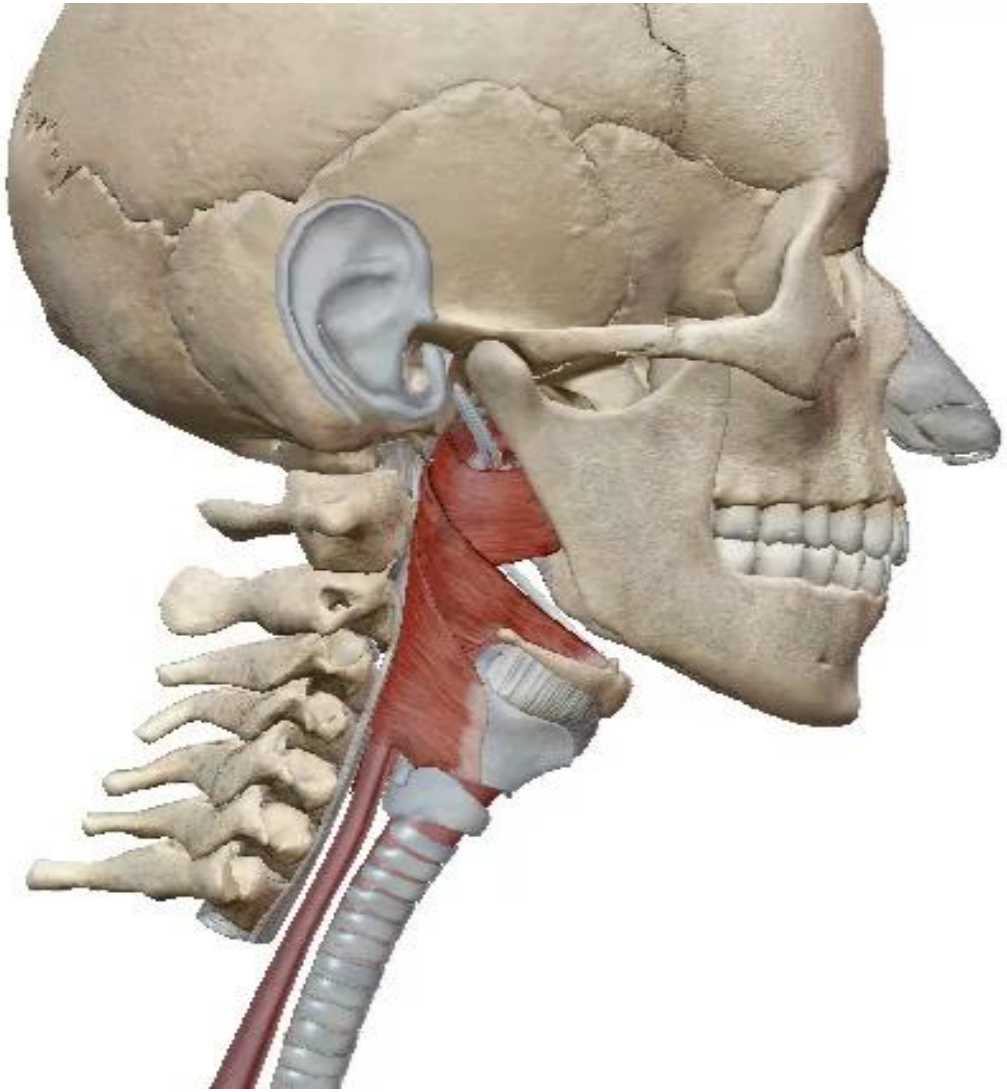

4. Stylopharyngeus muscle:

- Arises from the deep aspect of the styloid process high up
- Slopes down across the internal carotid artery, in front of which it crosses the lower border of the superior constrictor and passes down inside the middle constrictor
- Lies behind palatopharyngeus and is inserted into the posterior border of the thyroid lamina and the side wall of the pharynx

5. Salpingopharyngeus muscle:

- Very slender muscle that arises from the lower part of the cartilage of the auditory tube runs downwards to blend with palatopharyngeus

6. Palatopharyngeus muscle:

- Internal to superior constrictor muscle

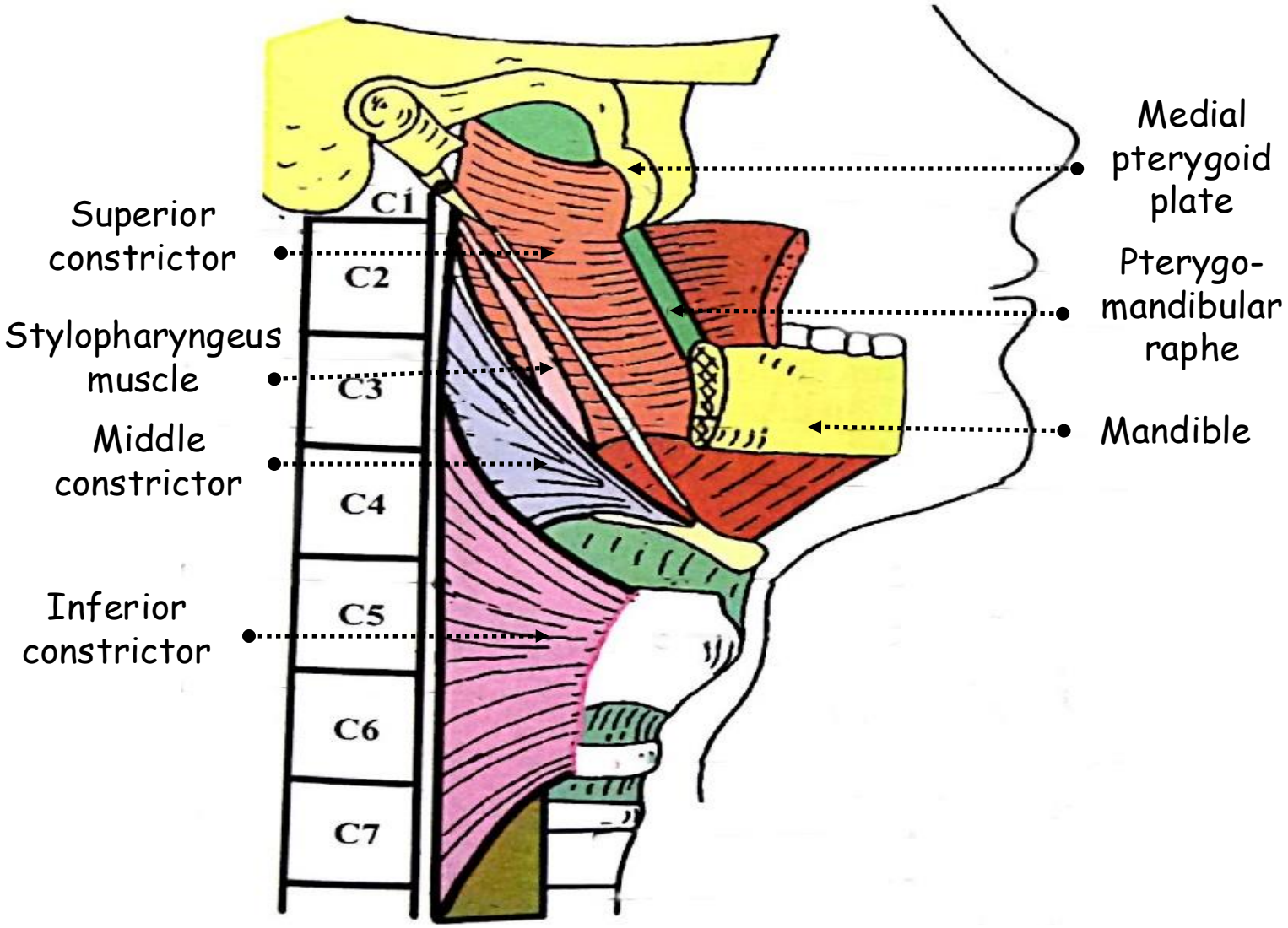

SAGITTAL SECTION OF THE PHARYNX SHOWING ITS MUSCLE WALL

D. BUCCOPHARYNGEAL FASCIA

- Thin
- Delicate epimysium of the pharyngeal constrictors
- Continuous over the pterygomandibular raphe with the epimysium over buccinator

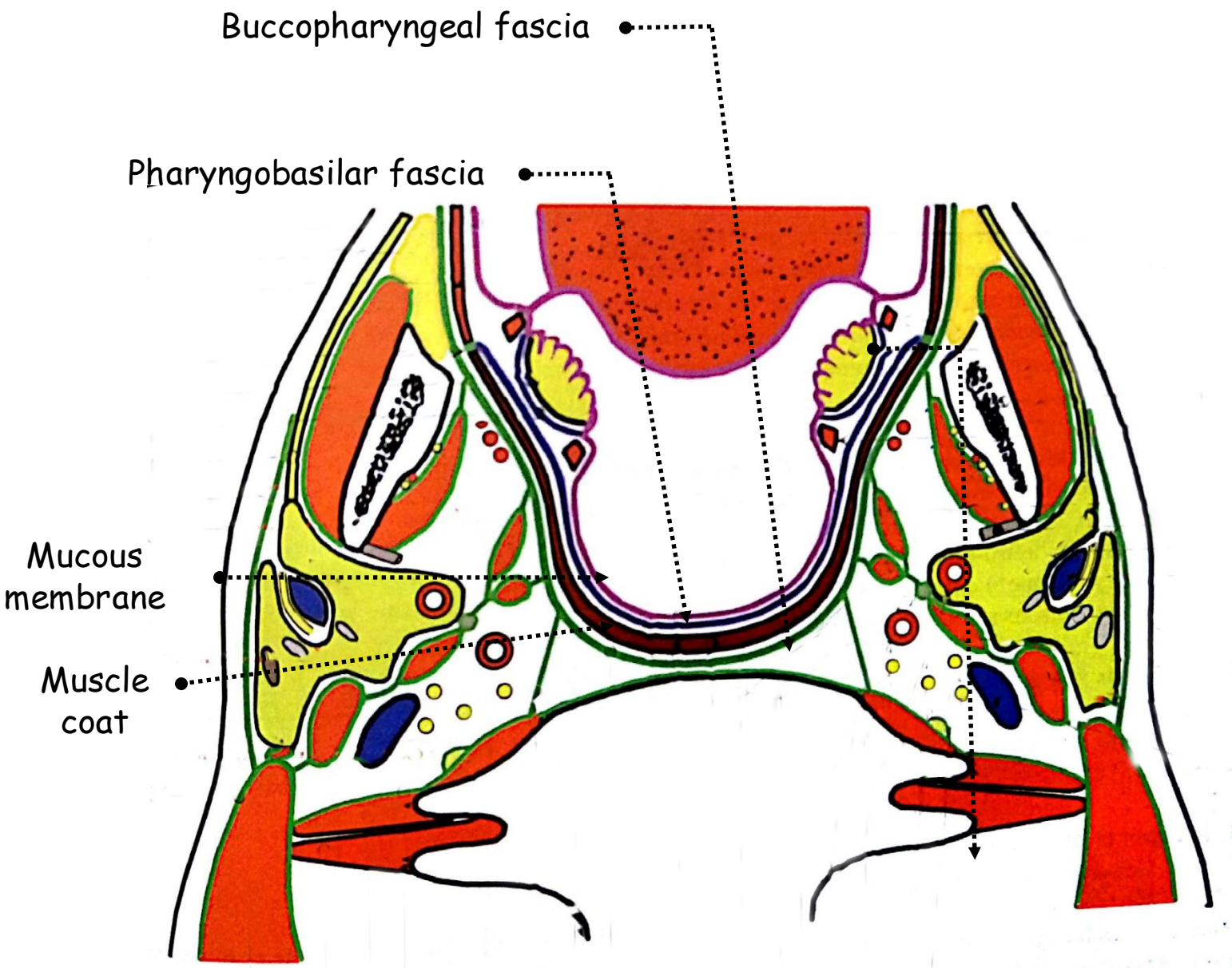

HORIZONTAL SECTION OF THE OROPHARYNX PASSING BY C2 VERTEBRA

IV. ANATOMICAL RELATIONS

A. BACKWARDS AND LATERALLY

- Prevertebral fascia
- 'Dead space' between the pharynx and the prevertebral fascia continuous with the posterior mediastinum
- Retrostyloid region of the parapharyngeal space:
  - -Internal carotid artery
  - -Internal jugular vein
  - -Vagus nerve
  - -Glossopharyngeal nerve
  - -Accessory nerve
  - -Hypoglossus nerve

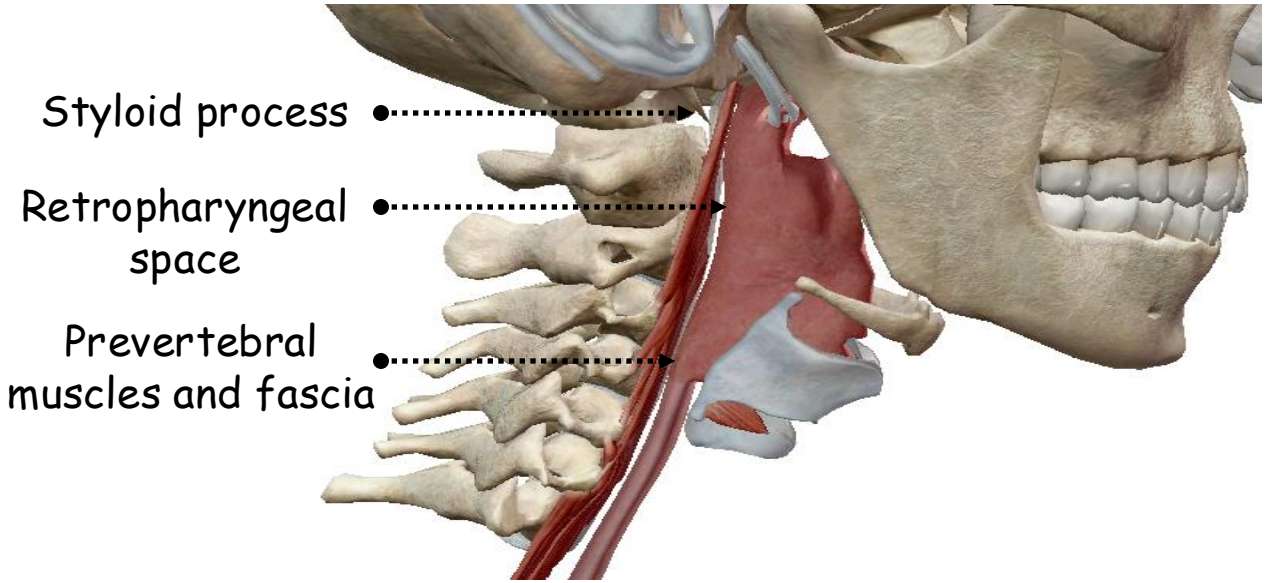

LATERAL VIEW OF THE HEAD AND NECK SHOWING THE PHARYNX

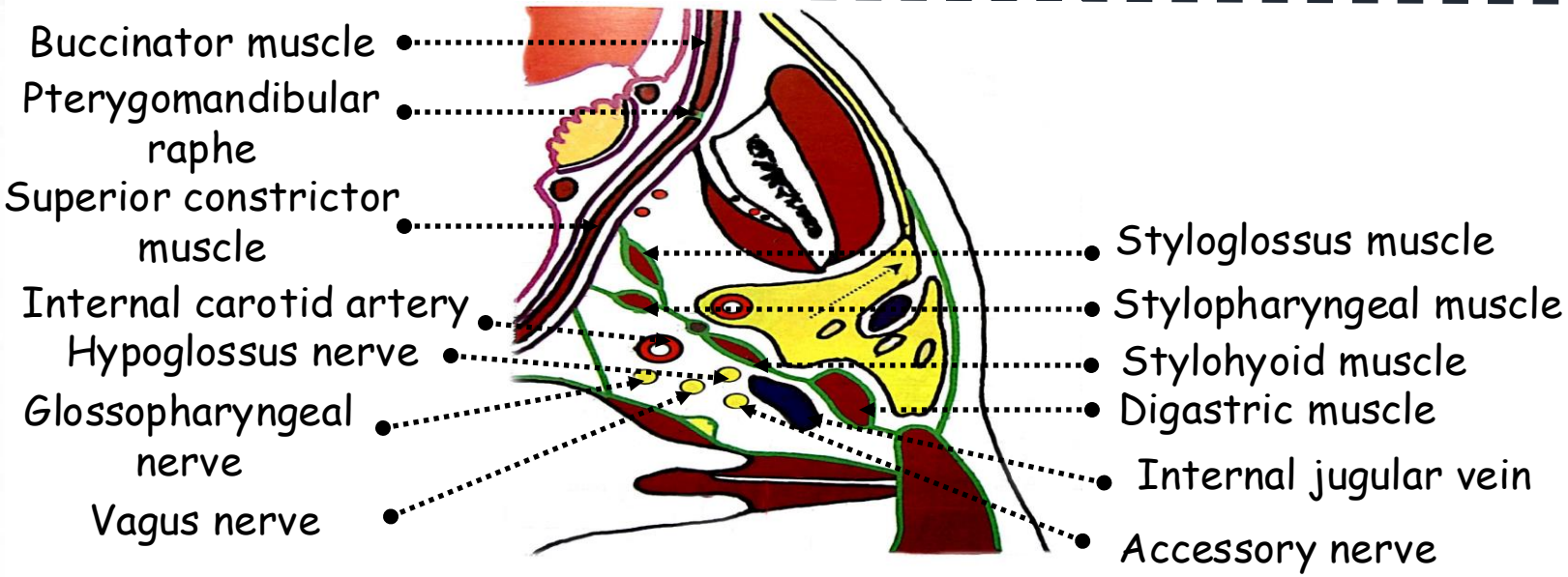

HORIZONTAL SECTION OF THE FACE AT THE LEVEL OF THE AXIS SHOWING THE PAROTID GLAND

B. FORWARDS

- 3 openings:
  - -Choanae
  - -Lateral glossoepiglottic folds and posterior part of the tongue
  - -Aditus

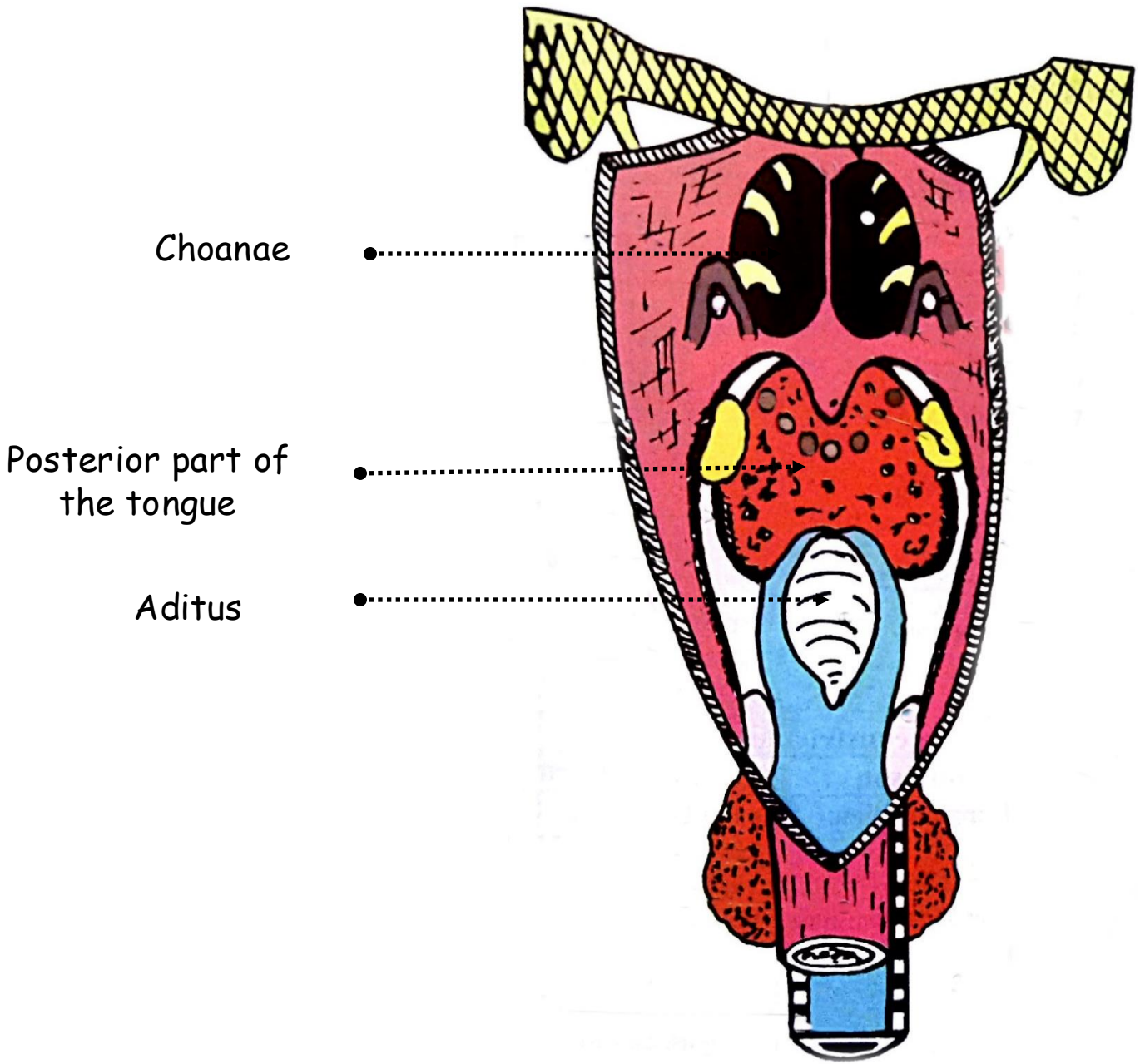

POSTERIOR VIEW OF THE PHARYNX

C. UPWARDS

- Pharyngeal tubercle of basiocciput
- Body of the sphenoid
- Auditory tubes laterally

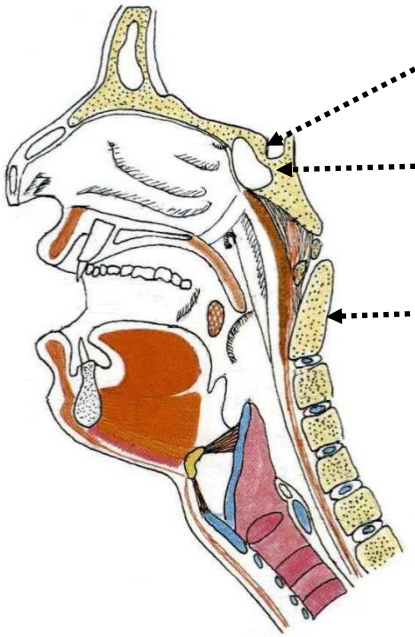

SAGITTAL SECTION OF THE PHARYNX SHOWING ITS MUSCLE WALL

V. BLOOD SUPPLY; LYMPH DRAINAGE AND NERVE SUPPLY

A. ARTERIES

- Branches of external carotid and subclavian arteries
- Superior thyroid artery through superior laryngeal artery
- Facial artery through ascending palatine branch
- Ascending pharyngeal artery
- Maxillary artery through artery of the pterygoid canal, superior pharyngeal and greater palatine arteries

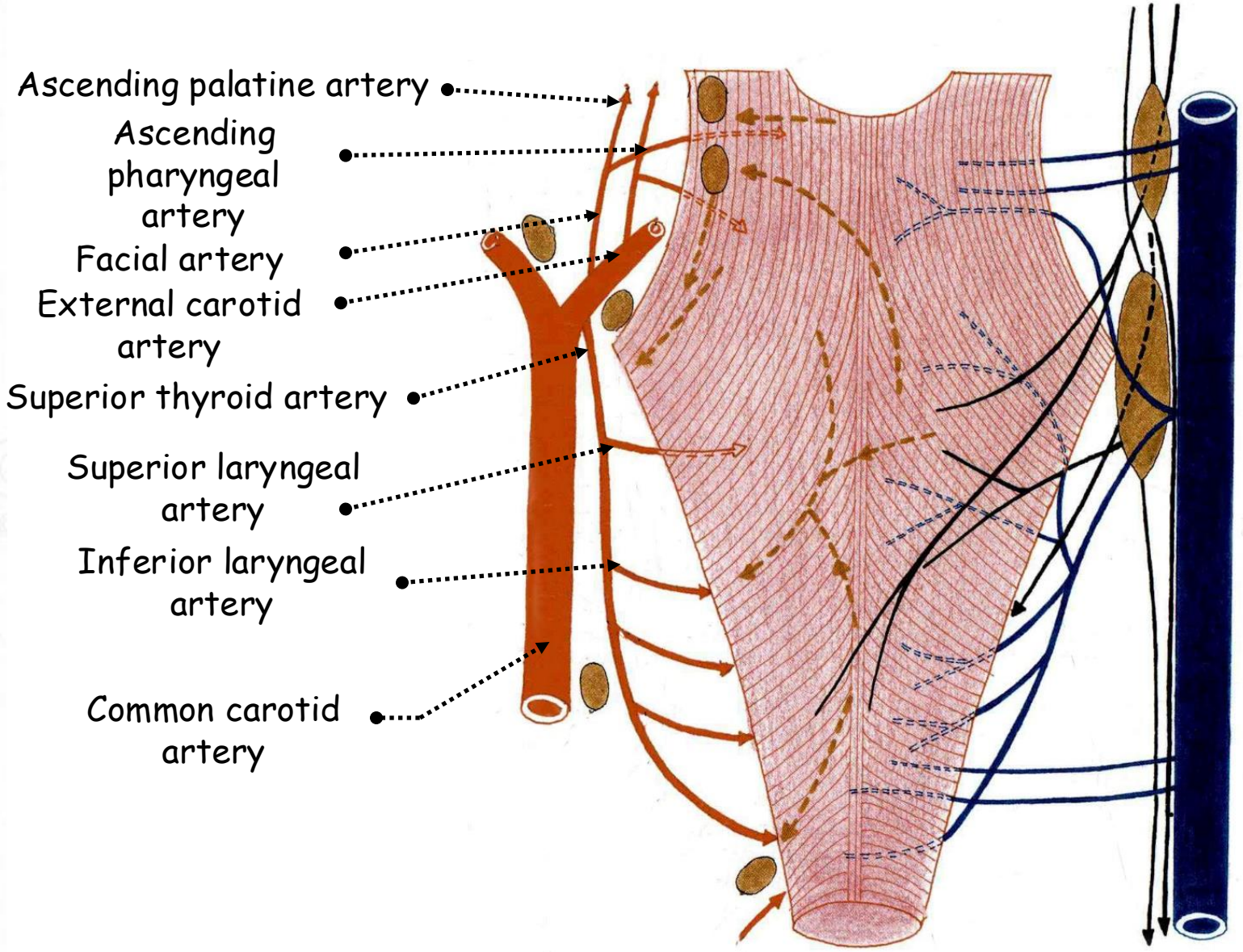

POSTERIOR VIEW OF THE PHARYNX SHOWING ITS BLOOD SUPPLY

- Inferior thyroid artery
- Lingual artery through dorsal lingual branches

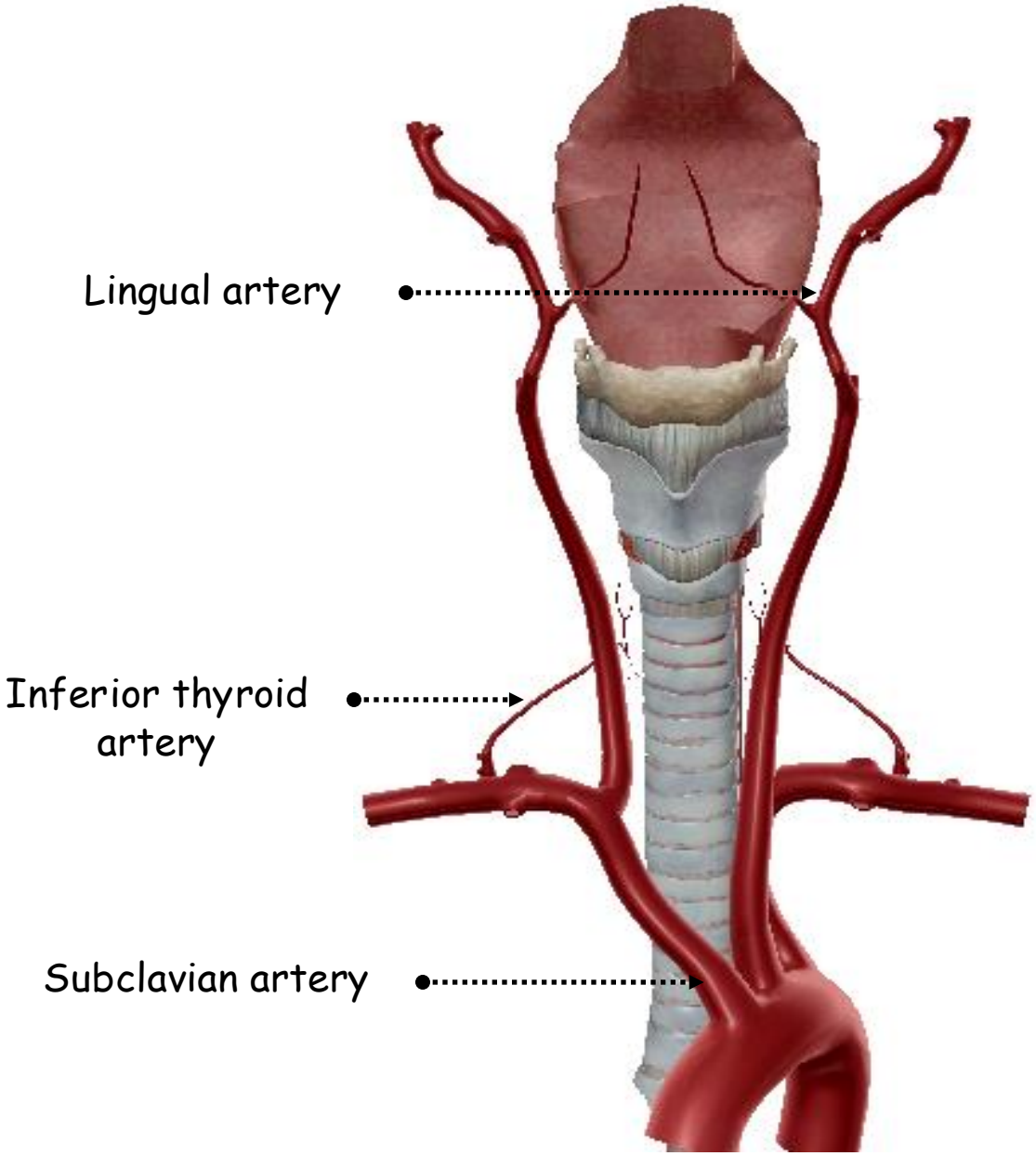

ANTERIOR VIEW OF THE AERODIGESTIVE TRACT SHOWING THE ARTERIES OF THE PHARYNX

B. VEINS

- Pharyngeal venous plexus
- The back of the middle constrictor
- Drains to the pterygoid plexus or directly into the internal jugular vein
- From the lowest part blood finds its way to the inferior thyroid veins

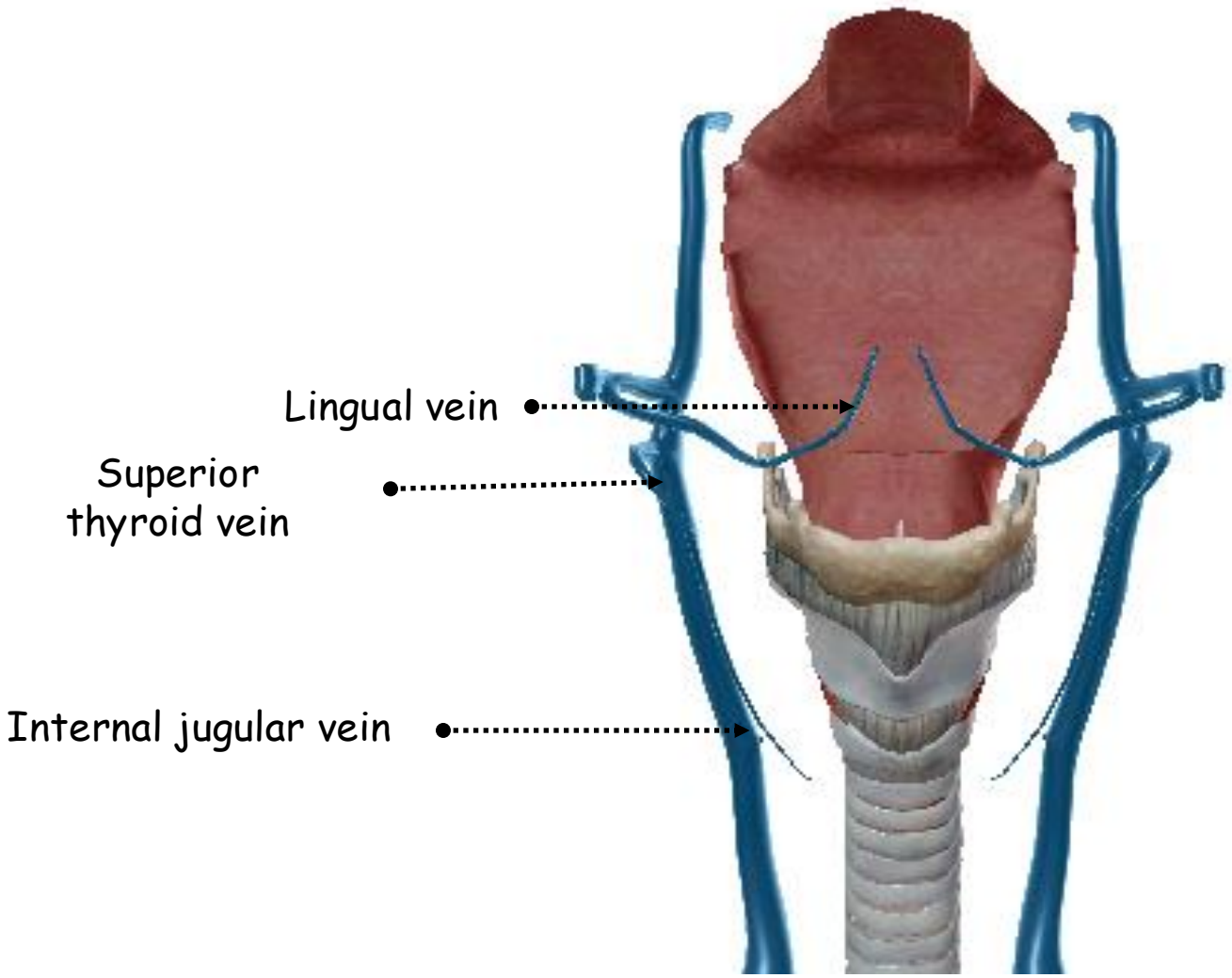

ANTERIOR VIEW OF THE AERODIGESTIVE TRACT SHOWING THE ARTERIES OF THE PHARYNX

C. LYMPH DRAINAGE

- Retropharyngeal nodes
- **Upper and lower deep cervical nodes:**
  - -Jugulodigastric group
  - -Jugular group

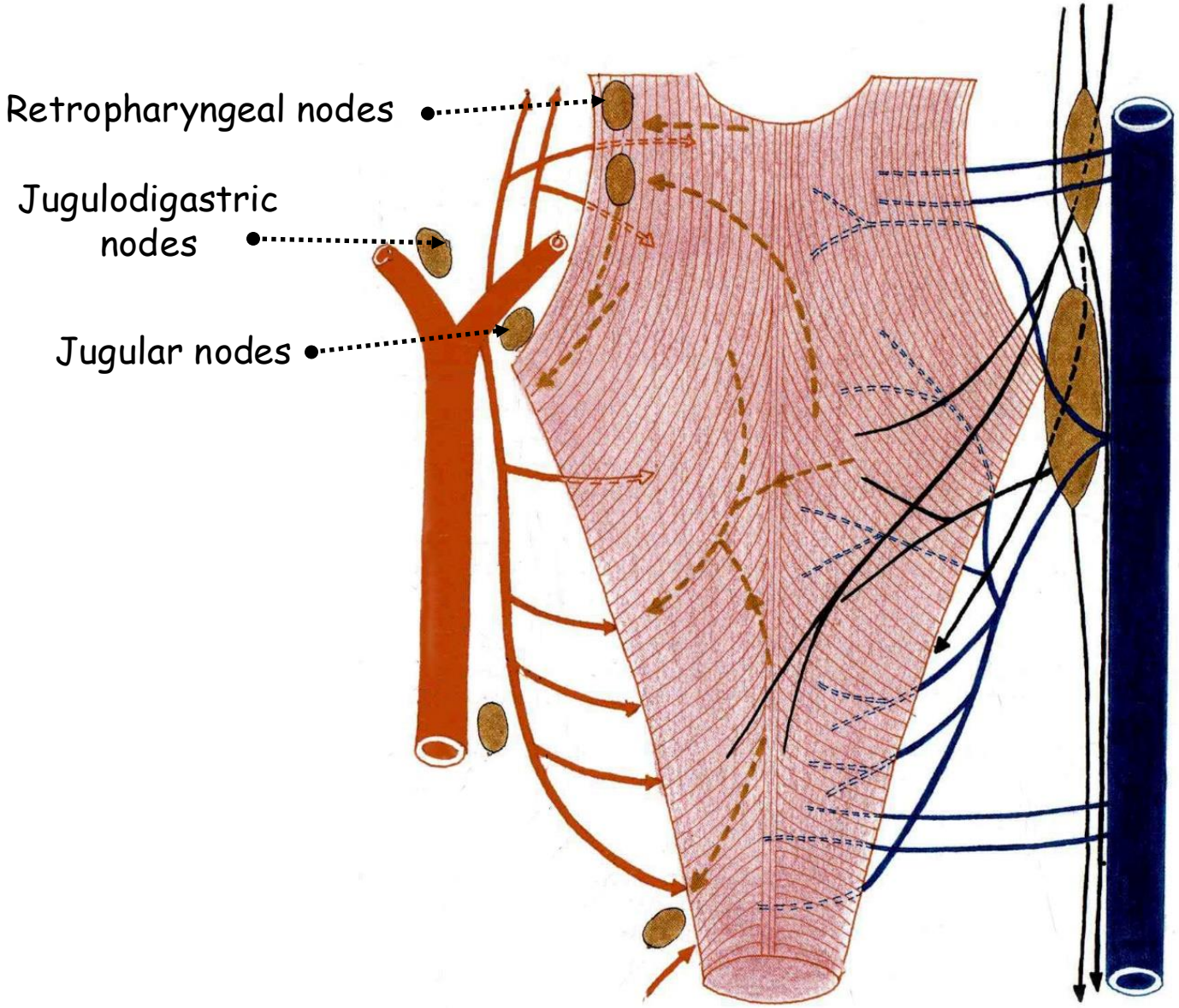

ANTERIOR VIEW OF THE AERODIGESTIVE TRACT SHOWING THE LYMPH DRAIANGE OF THE PHARYNX

D. NERVES

- Pharyngeal plexus
- The back of the middle constrictor
- Pharyngeal branches of glossopharyngeal, vagus and superior cervical ganglion
- Sensitive fibres: glossopharyngeal
- Motor fibres: vagus for constrictors and glossopharyngeal for stylopharyngeal

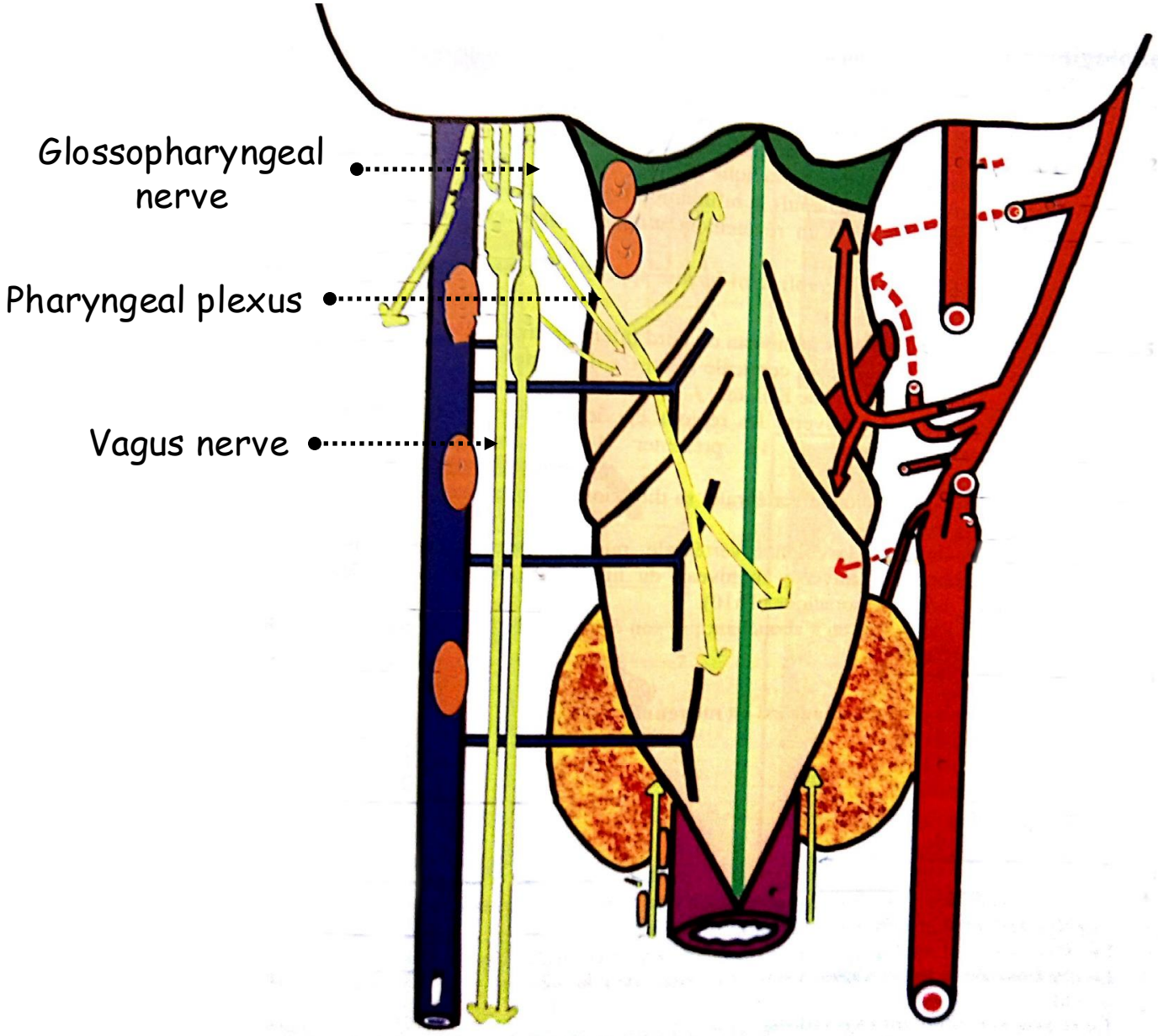

ANTERIOR VIEW OF THE AERODIGESTIVE TRACT SHOWING THE NERVES OF THE PHARYNX

VII. CONCLUSION

- Hollow muscular organ
- Most posterior viscera of the neck
- Multiple major functions
- Three parts
- Diverse blood supply, lymph drainage and nerve supply

MARRAKECH
جامعة القاضي عياض
UNIVERSITÉ CADI AYYAD

كلية الطب
والصيدلة - مراكش
FACULTÉ DE MÉDECINE
ET DE PHARMACIE - MARRAKECH

ANATOMIE
FMPM