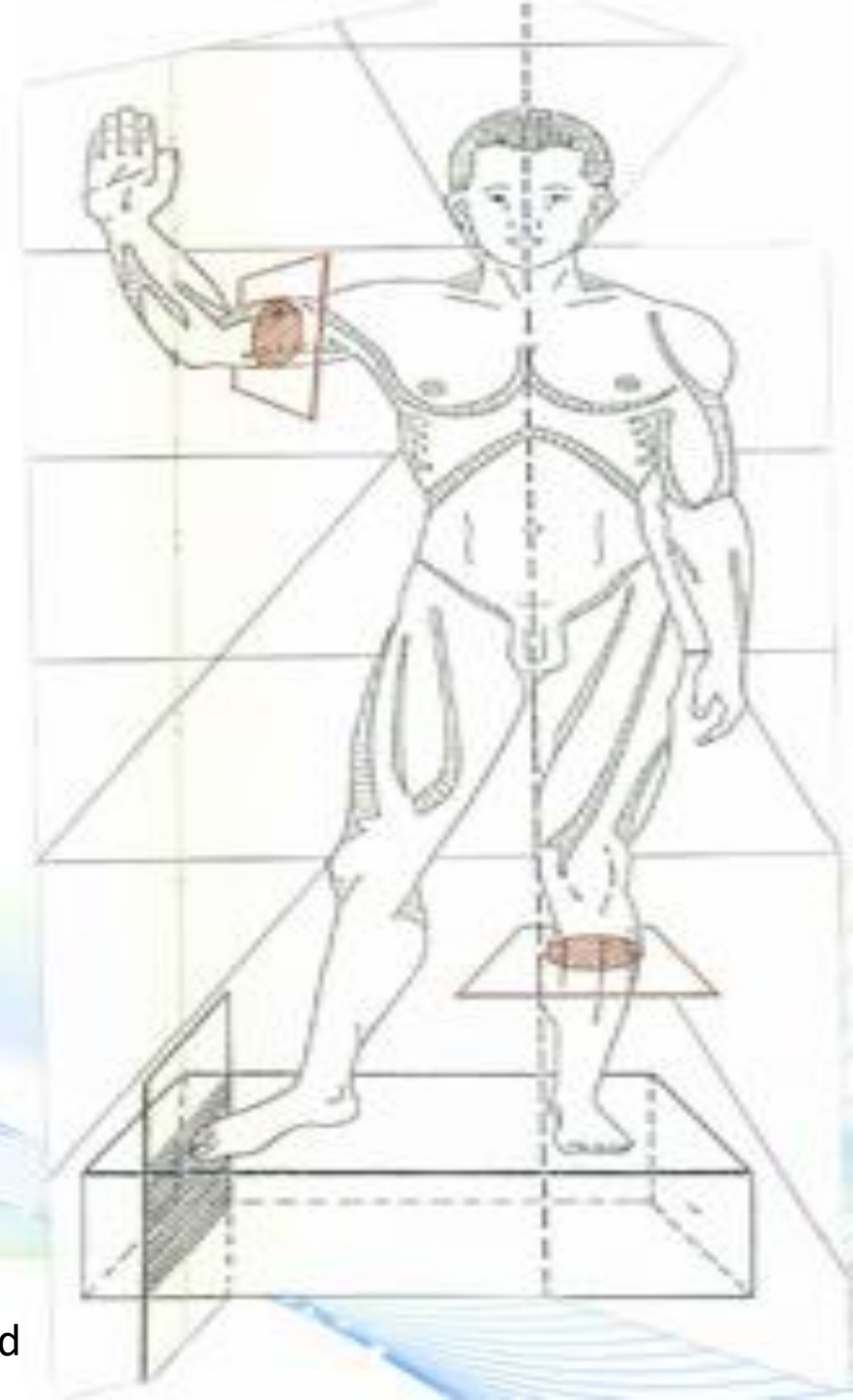


ABDOMINAL WALL



CONTENTS

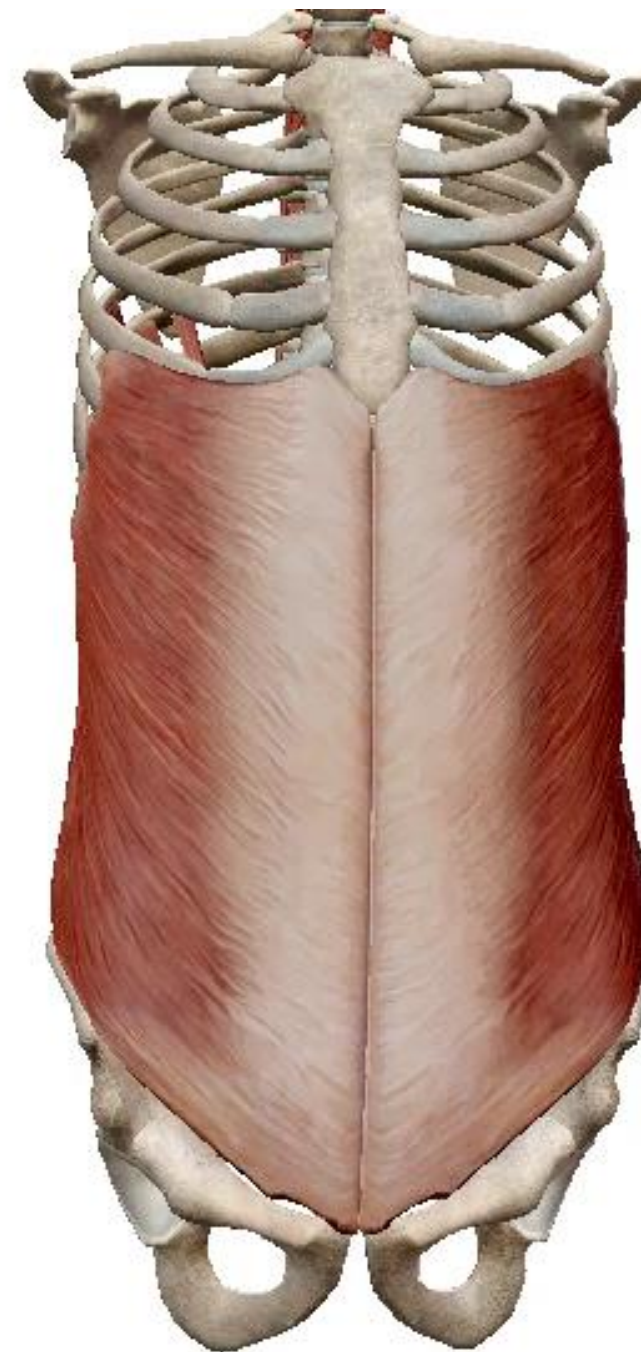
I. INTRODUCTION

II. DESCRIPTIVE ANATOMY

**III. BLOOD SUPPLY; LYMPH
DRAINAGE AND NERVE
SUPPLY**

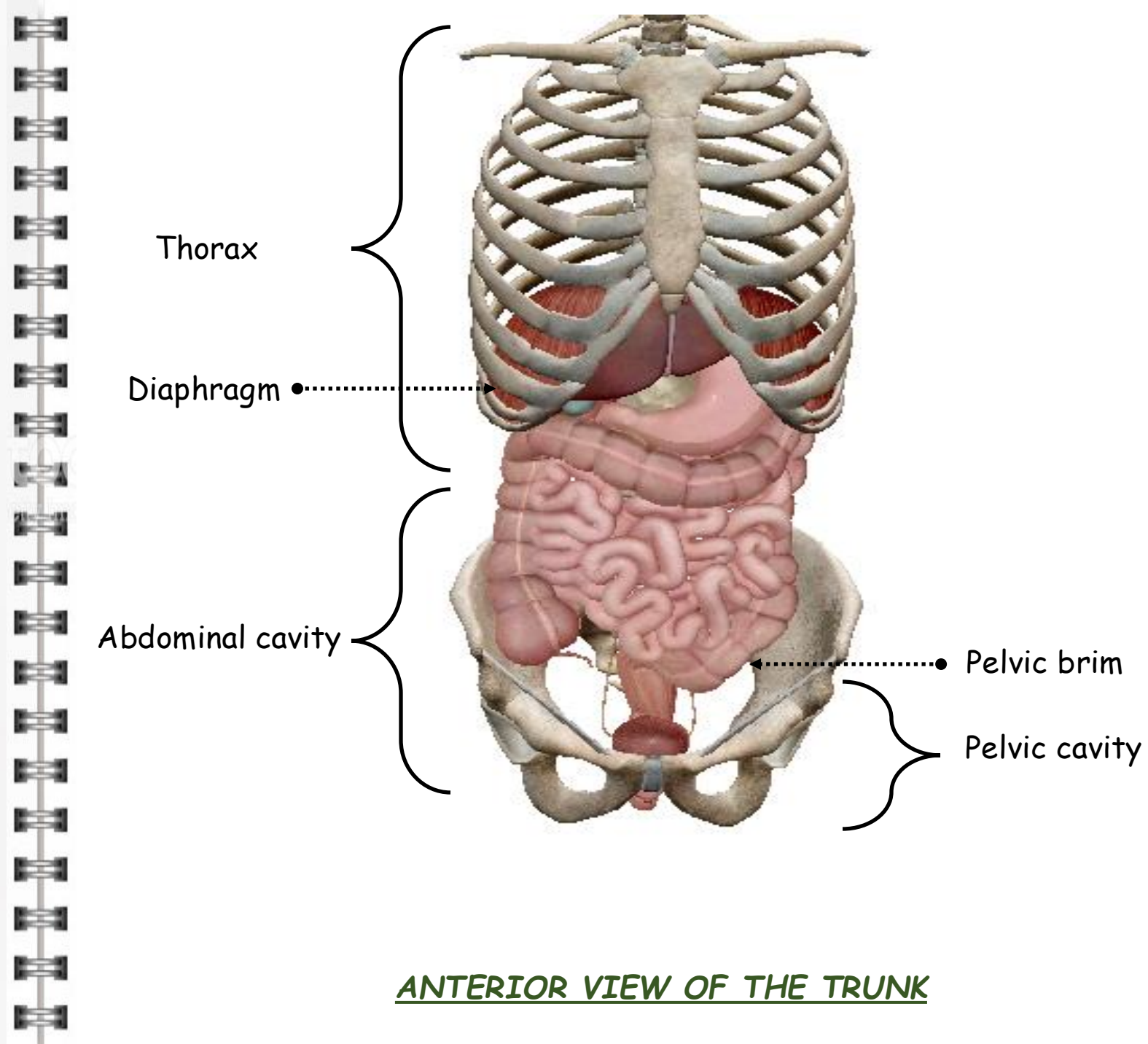
IV. SURGICAL APPROACH

V. CONCLUSION



I. INTRODUCTION

- Trunk: columnar cavity
- Divided by the thoracoabdominal diaphragm
- Above the diaphragm: thorax covered by the thoracic wall
- Below the diaphragm: abdominal cavity covered by the anterior and posterior abdominal walls
- Anterior abdominal wall: skeletal, muscular and aponeurotic
- Posterior abdominal wall: skeletal and muscular
- The abdominal cavity contains the digestive and urogenital viscera
- Below the pelvic brim is the pelvic cavity
- The latter can be distinguished from the abdominal cavity proper
- Closed below by the pelvic diaphragm



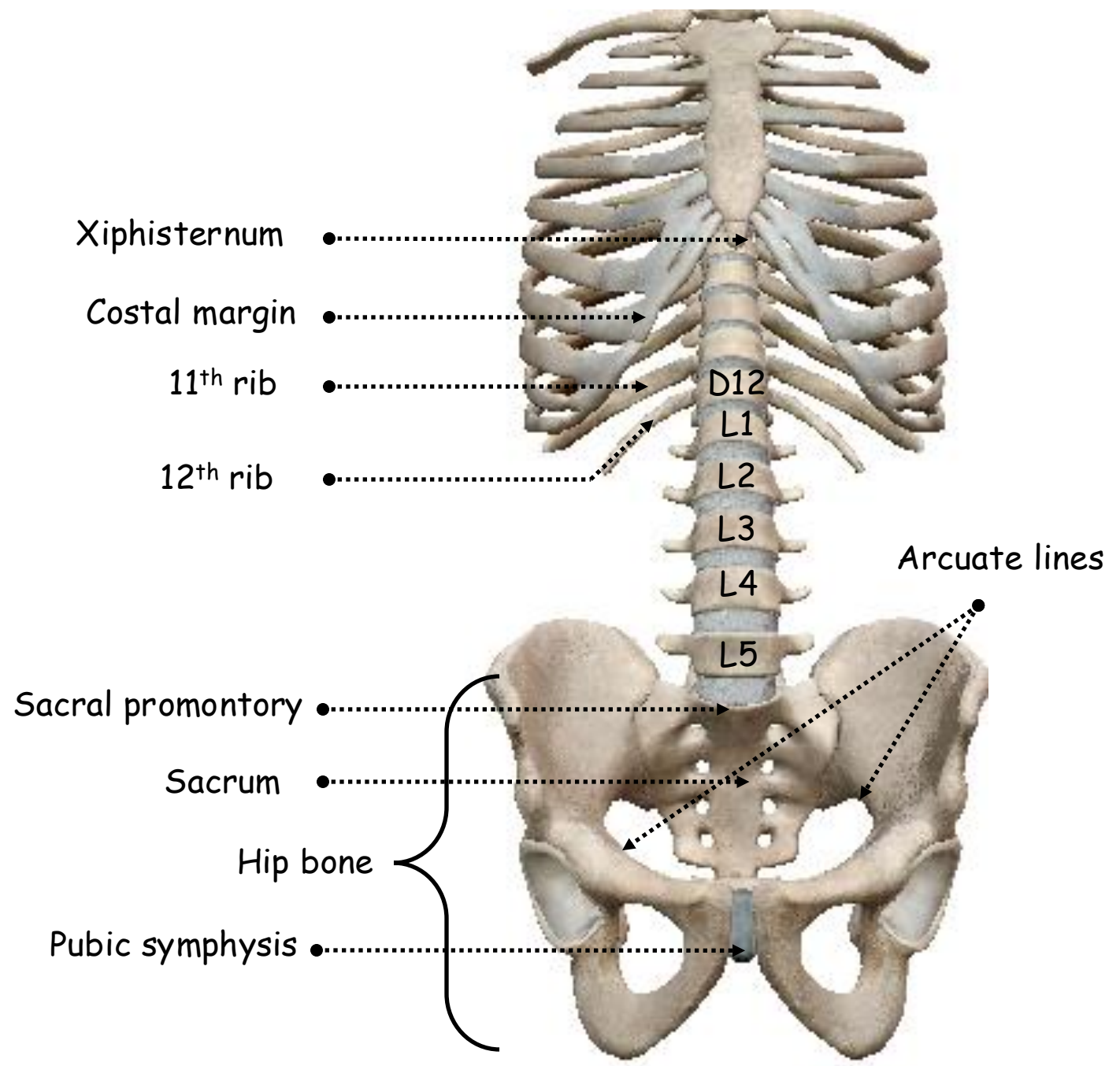
ANTERIOR VIEW OF THE TRUNK

II. DESCRIPTIVE ANATOMY

A. ANTERIOR ABDOMINAL WALL

1. Skeleton of anterior abdominal wall:

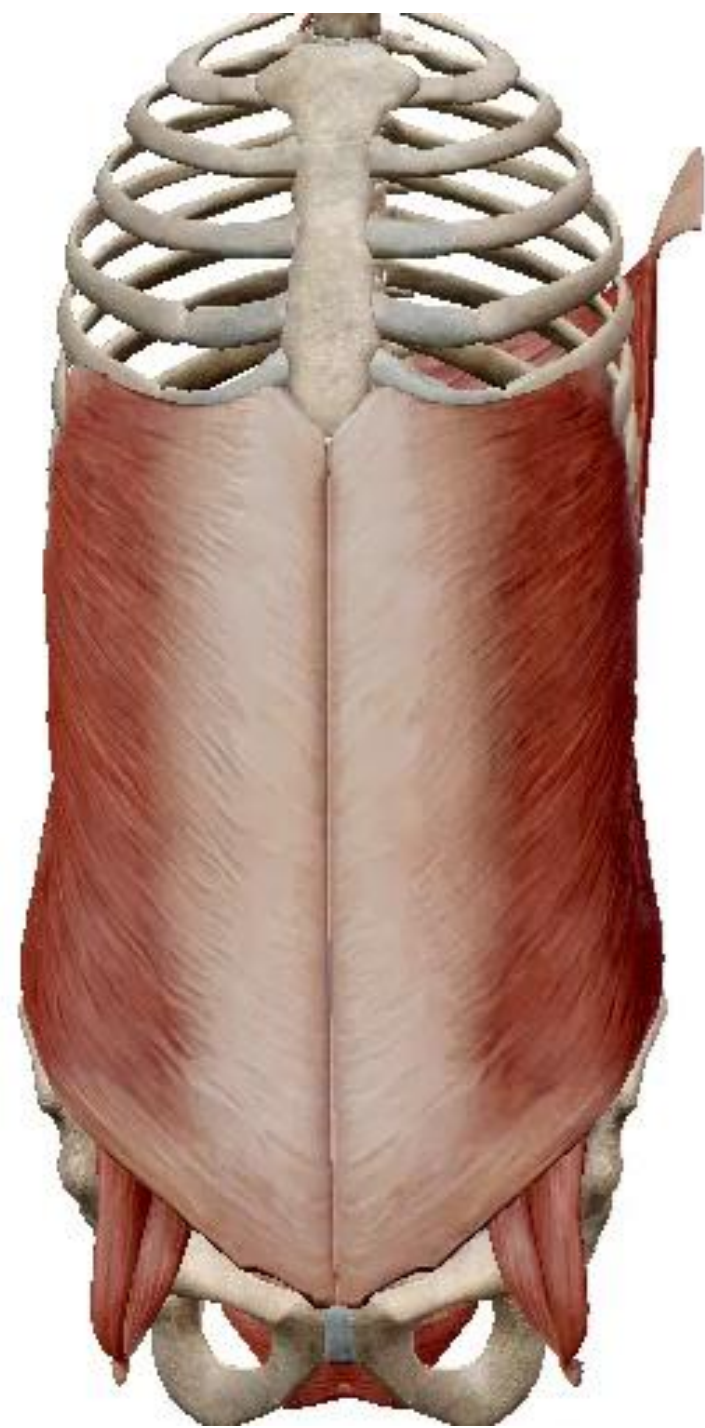
- Upwards: thoracic outlet limited by the xiphisternum and the costal margins forwards and the 11th and 12th ribs backwards
- Downwards: pelvic bones namely the hip bones brought together forwards by the pubic symphysis and hinged backwards with the sacrum through the sacroiliac joints
- The pelvic brim is limited backwards by the sacral promontory, the arcuate lines laterally and the upper edge of the pubic symphysis



ANTERIOR VIEW OF THE SKELETON OF ABDOMINAL WALL

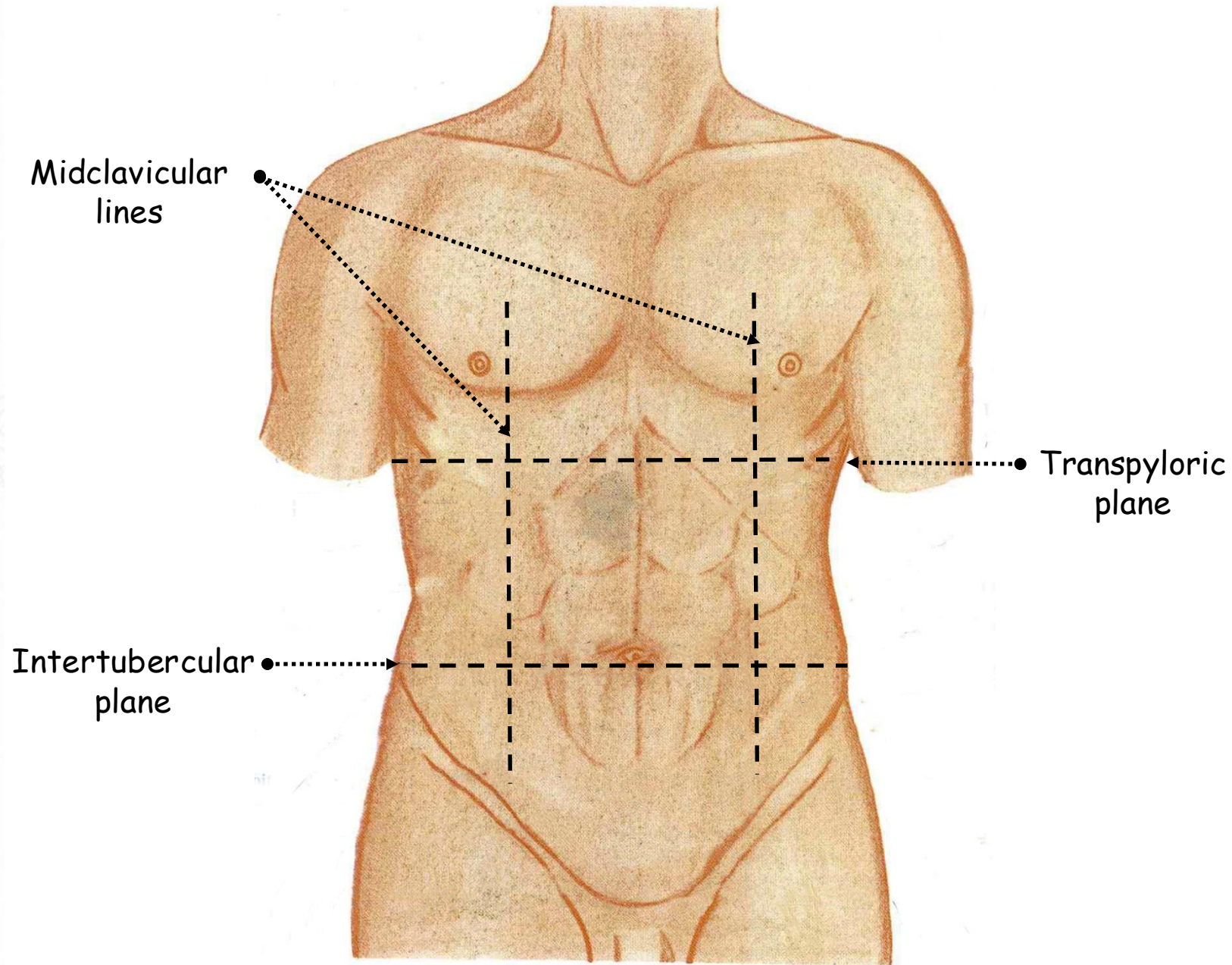
2. Anterolateral abdominal muscles and aponeuroses:

- External oblique muscle
- Internal oblique muscle
- Transversus abdominis muscle
- Fuse together ventrally to form the rectus abdominis muscle
- Pyramidalis muscle



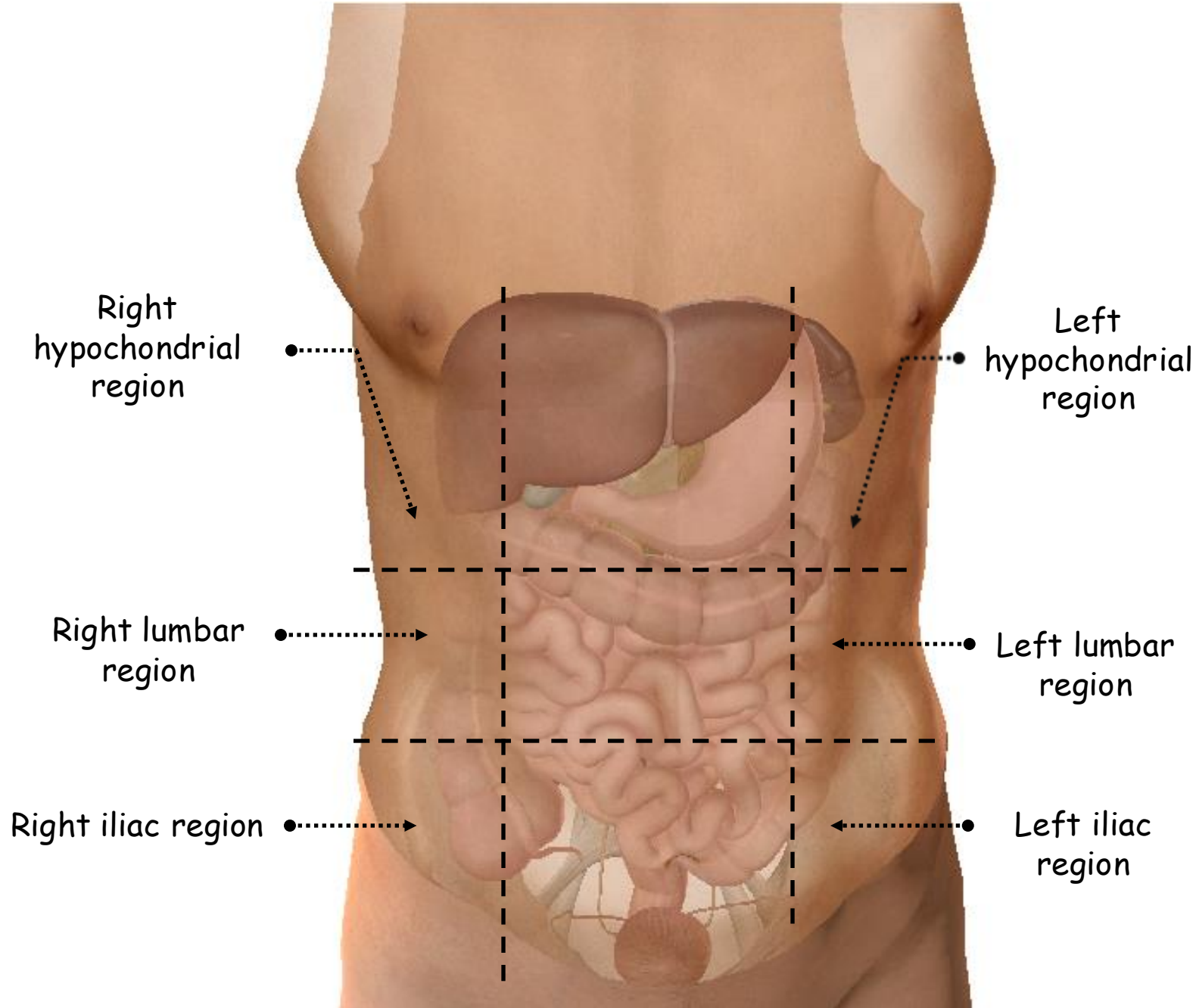
3. Surface marking of anterior abdominal wall:

- Nine regions
- Delineated by two vertical lines on each side and two horizontal lines
- Vertical line: midclavicular extended downwards to the midinguinal point on the inguinal ligament midway between the pubic symphysis and the anterior superior iliac spine
- Lower transverse line: intertubercular plane between the tubercles of the iliac crests
- Upper transverse line: transpyloric plane midway between the jugular notch and the top of the pubic symphysis although some clinicians use the subcostal plane which is a little lower
- Clinical interest



ANTERIOR VIEW OF THE SURFACE OF THE TRUNK

- 3 lateral regions
- Right and left hypochondrial regions:
 - Right: liver, gall bladder and right colic flexure
 - Left: spleen and left colic flexure
- Right and left lumbar regions:
 - Right: right kidney and ascending colon
 - Left: left kidney and descending colon
- Right and left iliac regions:
 - Right: cecum and appendix and right adnexa in women
 - Left: sigmoid colon and left adnexa in women



ANTERIOR VIEW OF THE SURFACE OF THE TRUNK

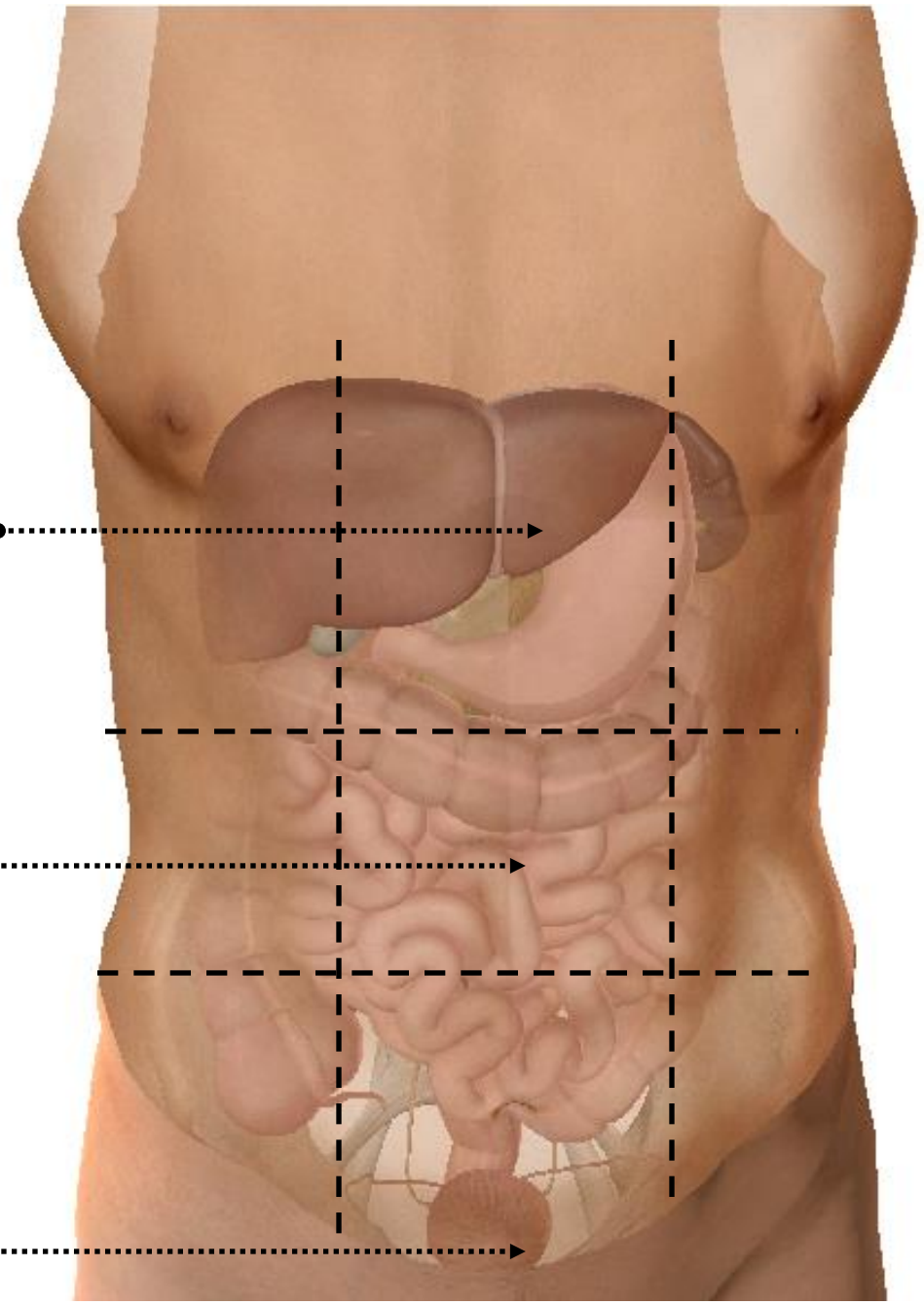
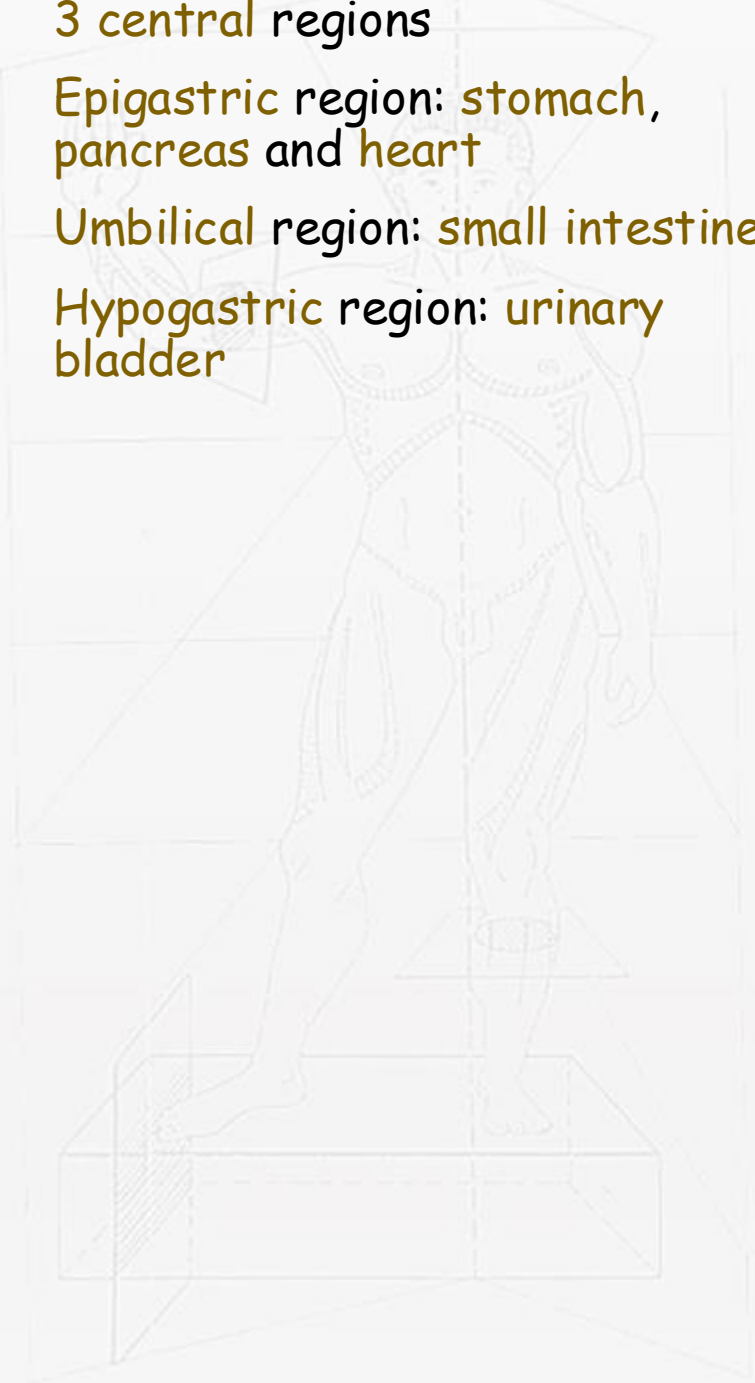- 3 central regions
- Epigastric region: stomach, pancreas and heart
- Umbilical region: small intestine
- Hypogastric region: urinary bladder

Epigastric region

Umbilical region

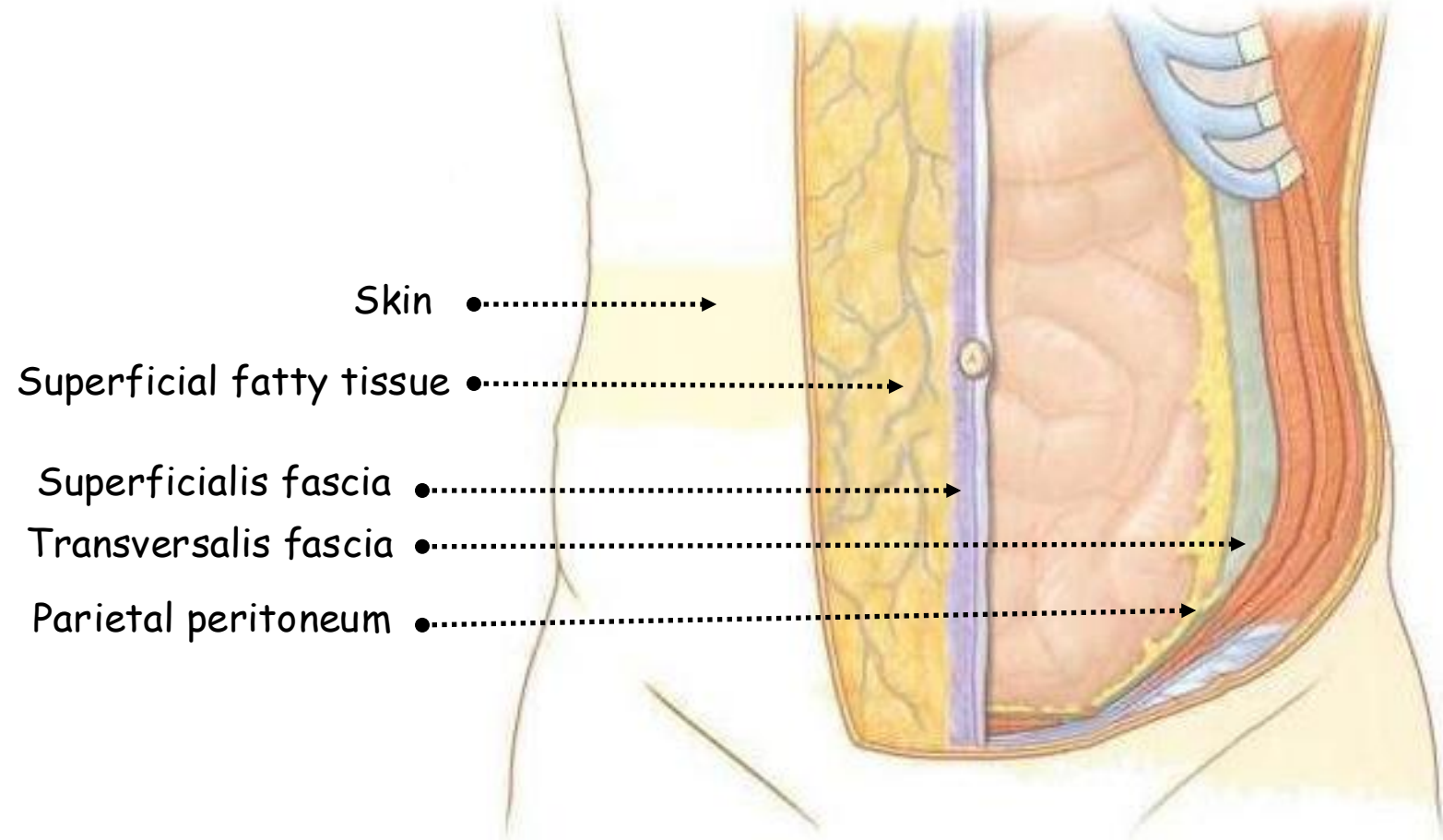
Hypogastric region

ANTERIOR VIEW OF THE SURFACE OF THE TRUNK



4. Skin and subcutaneous tissue:

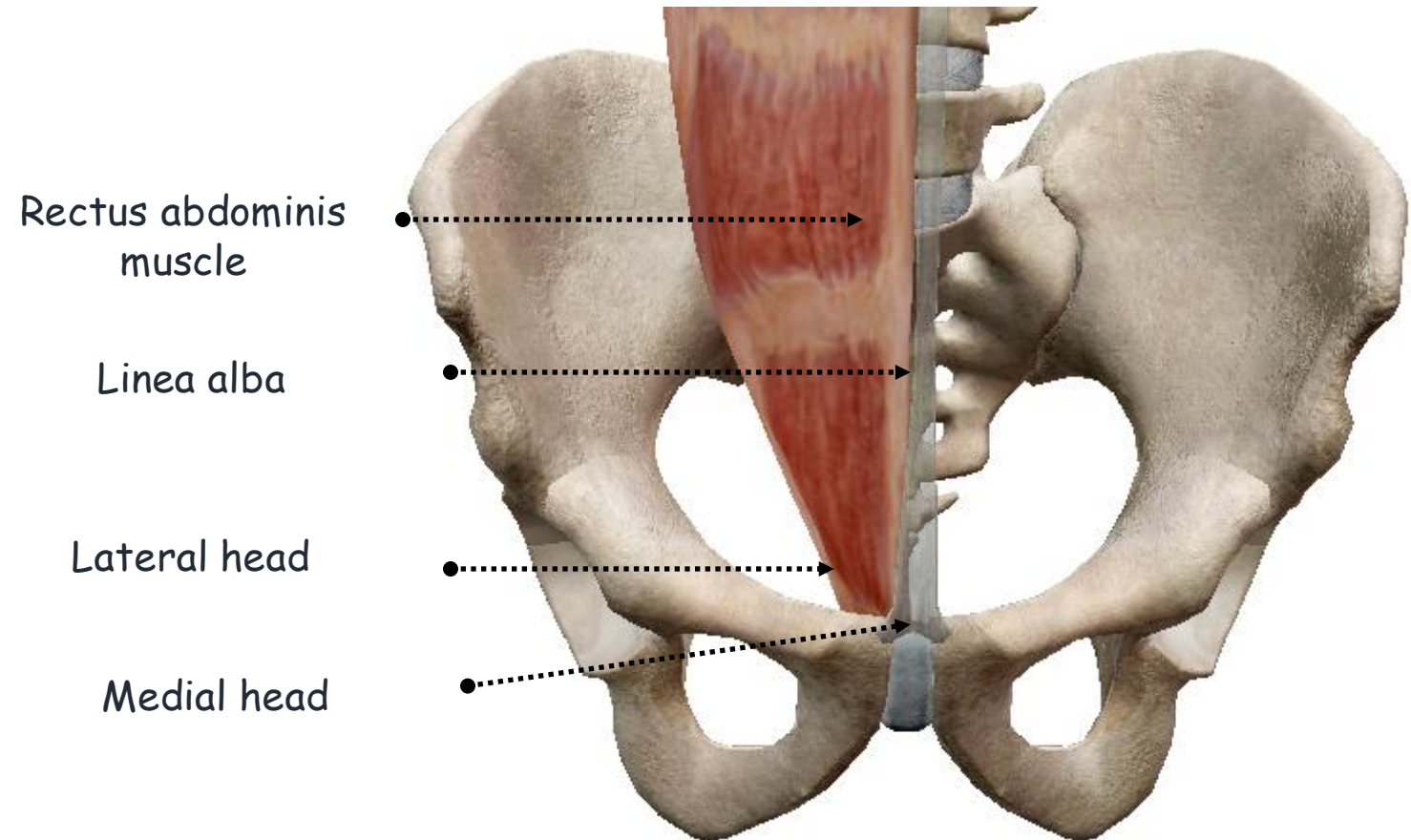
- Skin: thin and flexible
- Superficial subcutaneous tissue: fatty above the superficial fascia of Scarpa
- Superficialis fascia: Scarpa
- Deep subcutaneous tissue: fatty below the fascia of Scarpa



ANTERIOR VIEW OF THE ABDOMEN SHOWING THE LAYERS OF THE ANTEROLATERAL ABDOMINAL WALL

5. Rectus abdominis muscle:

- Paired
- Arises by two heads
- Medial from in front of the pubic symphysis
- Lateral from the upper border of the pubic crest
- Relatively small tendon that rapidly thickens
- The two muscles lie edge to edge in the lower part, but broaden out above separated by the linea alba



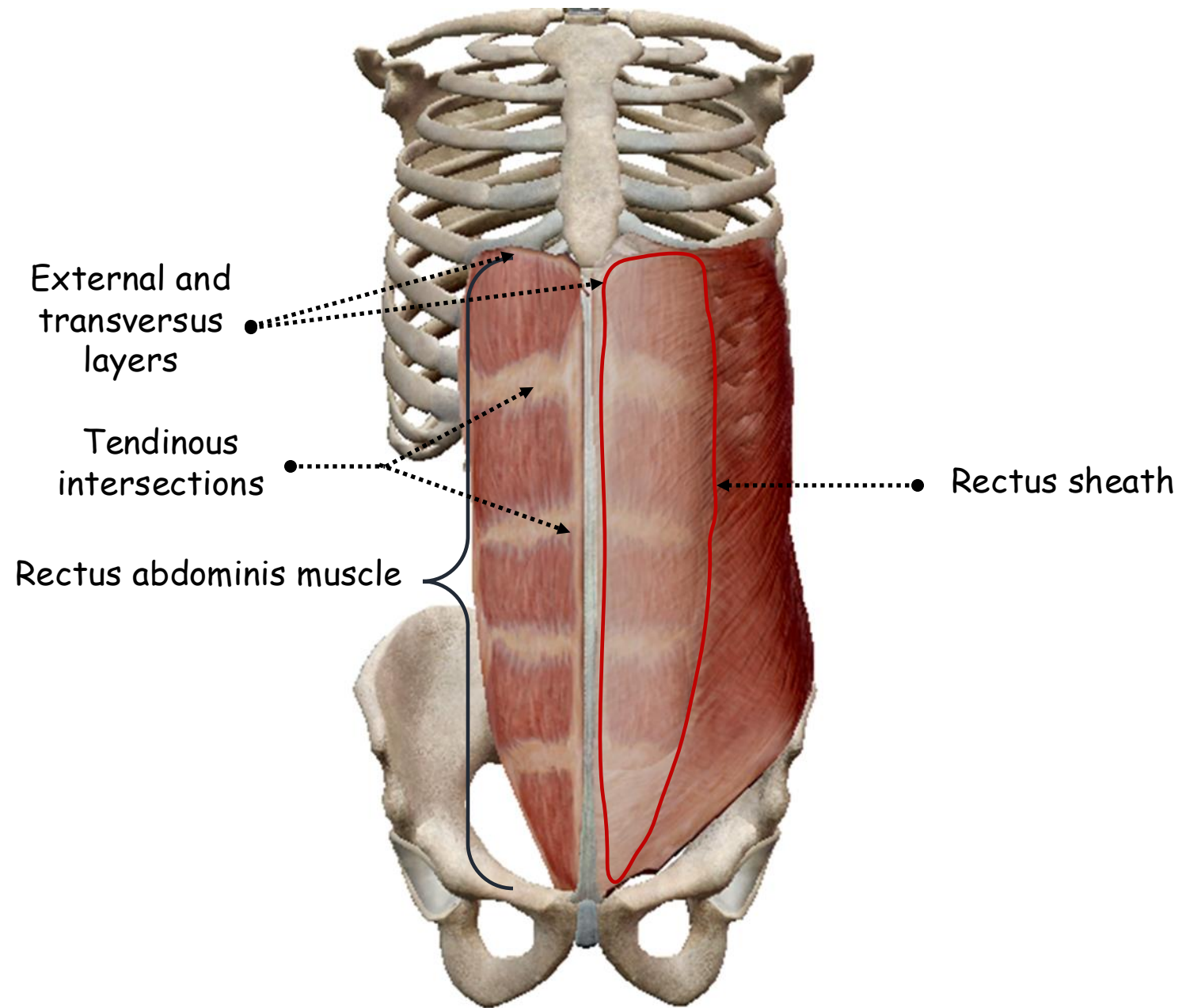
ANTERIOR VIEW OF THE PELVIS SHOWING THE PELVIC INSERTIONS OF RECTUS ABDOMINIS MUSCLE

- **Thoracic insertions:**

- External oblique layer: in front of the fifth to seventh costal cartilages
- Internal oblique layer: costal margin at the lower border of seventh cartilage
- Transversus layer: xiphisternal fibres

- **3 tendinous intersections:**

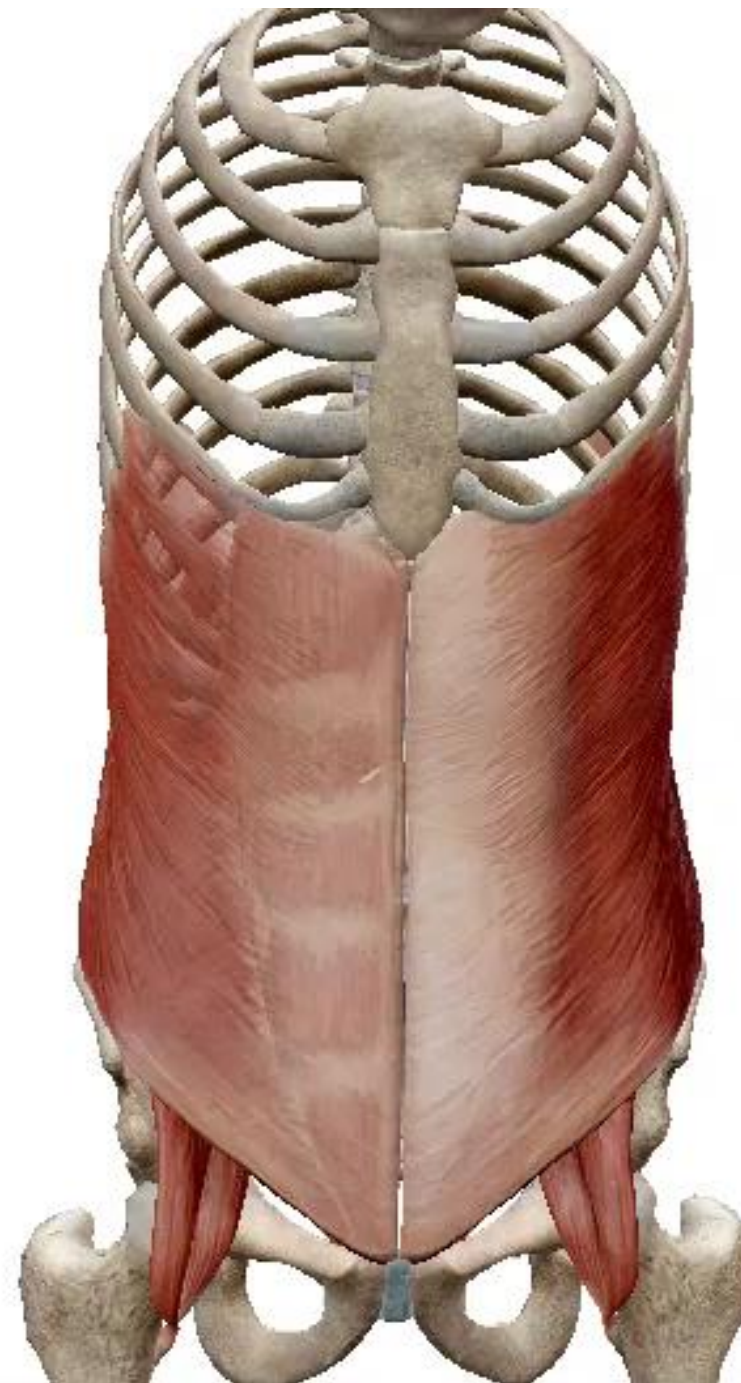- Upper: xiphisternum
- Lower: umbilicus
- Middle: midway between the latter
- Blend with the anterior layer of the rectus sheath and do not penetrate to the posterior surface of the muscle



ANTERIOR VIEW OF THE SKELETON OF THE TRUNK
SHOWING THE RECTI ABDOMINIS MUSCLES

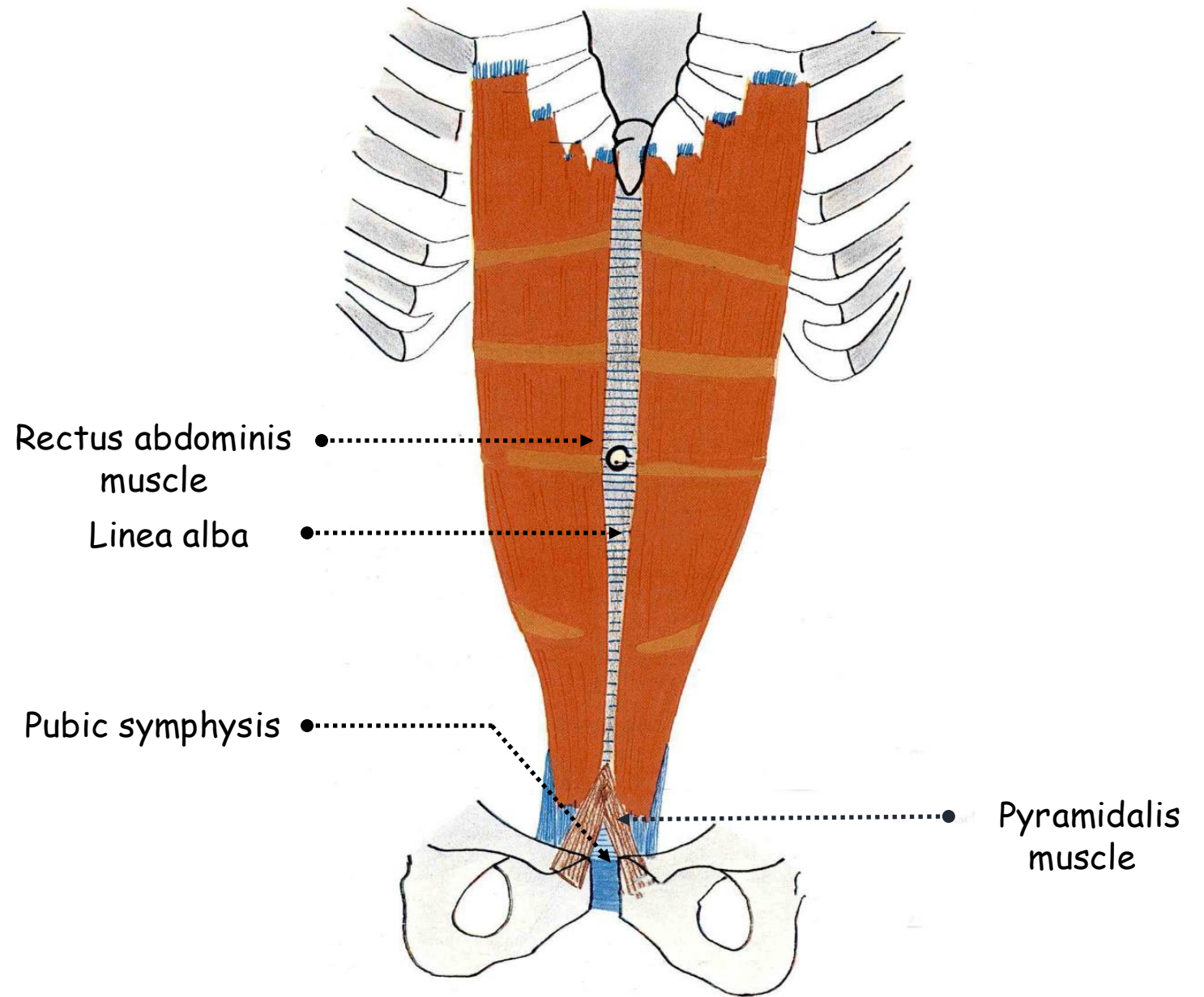
- **Actions:**

- Compressor of the abdomen
- Flexor of the vertebral column
- Depressor of ribs



6. Pyramidalis muscle:

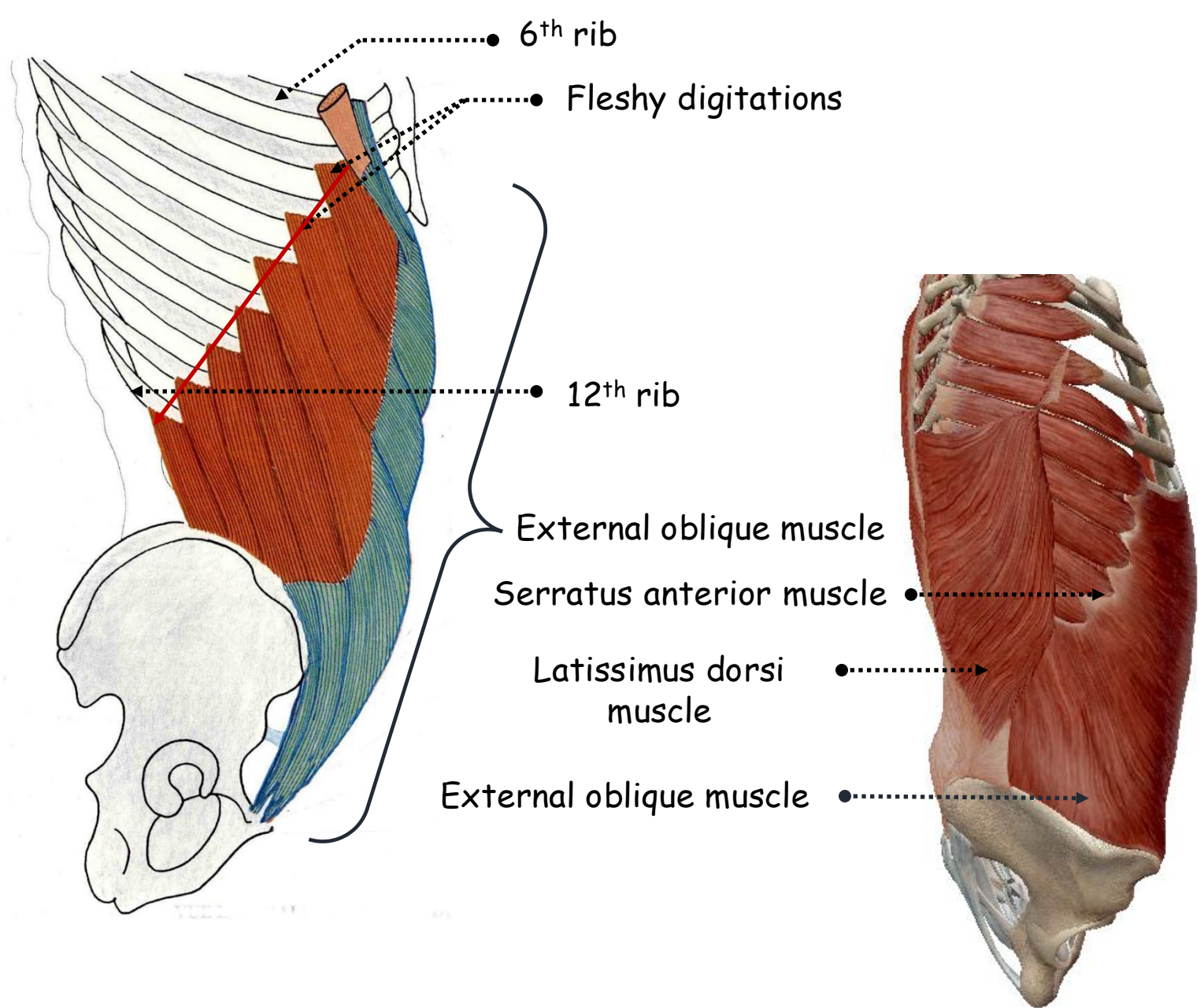
- Arises from the pubic crest
- Between rectus abdominis and its sheath
- Converges with its fellow into the **linea alba** 4 cm above its origin



ANTERIOR VIEW OF THE SKELETON OF THE TRUNK
SHOWING THE RECTI ABDOMINIS AND PYRAMIDALIS
MUSCLES

7. External oblique muscle:

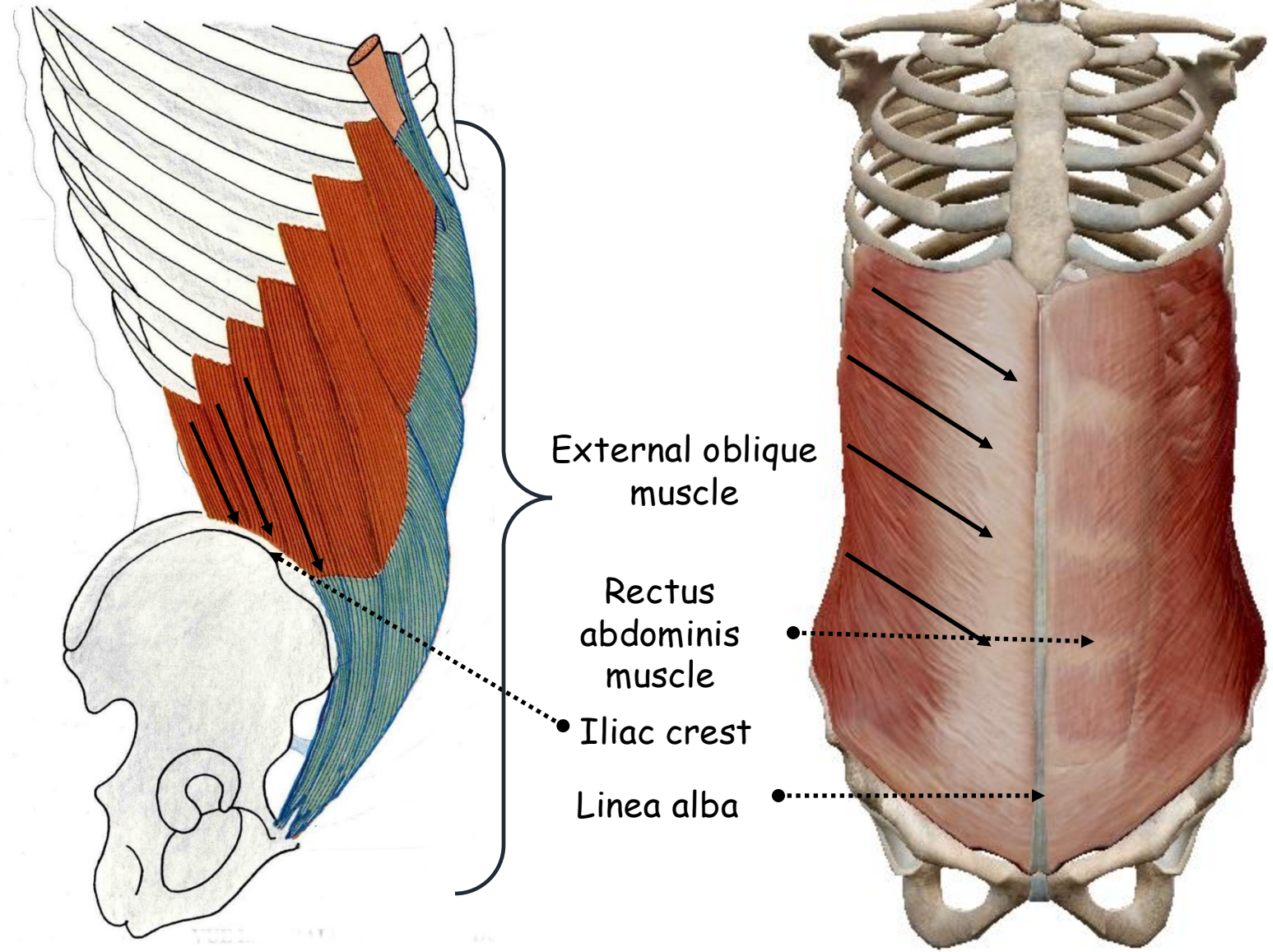
- Paired
- Most superficial
- Large and thick
- **Fleshy origin:**
 - Eight digitations
 - One from each of the lower eight ribs just lateral to their anterior extremities
 - Lower four slips interdigitate with the costal fibres of latissimus dorsi
 - Upper four with corresponding digitations of serratus anterior



LATERAL VIEW OF THE SKELETON OF THE TRUNK SHOWING THE EXTERNAL OBLIQUE MUSCLE

- **Wide mostly aponeurotic insertion:**

-Backwards: fleshy free fibres into the anterior half of the outer lip of the iliac crest and form the anterior boundary of lumbar triangle of Petit



LATERAL AND ANTERIOR VIEWS OF THE SKELETON OF THE TRUNK SHOWING THE EXTERNAL OBLIQUE AND RECTUS ABDOMINIS MUSCLES

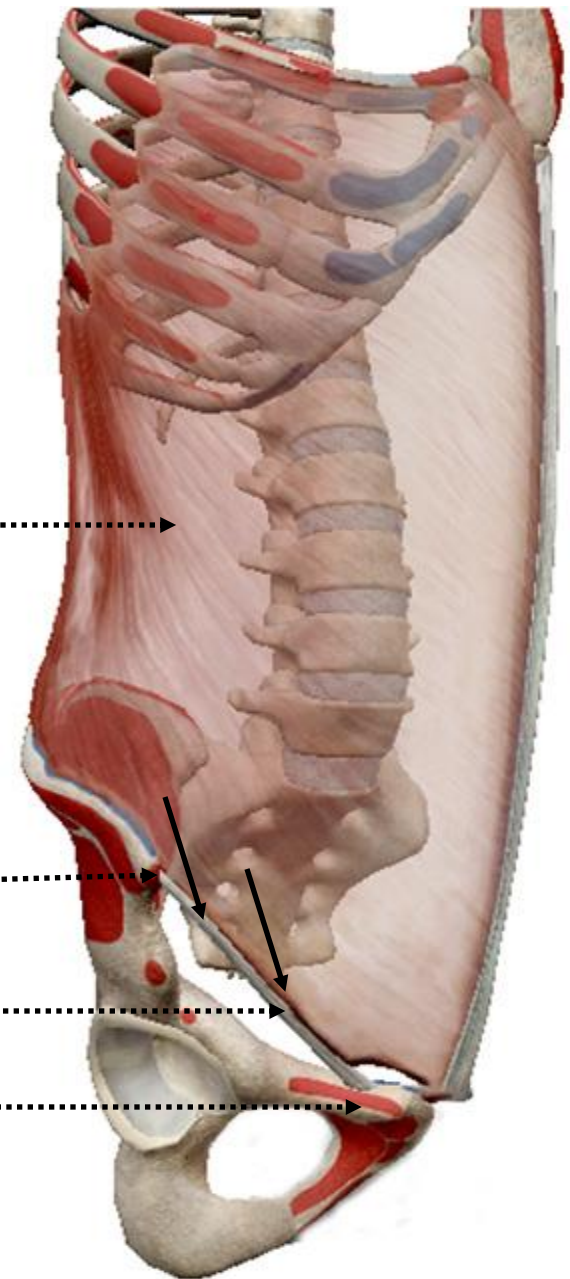
-Forwards: **aponeurotic fibres** directed obliquely downwards and forwards from **anterior superior iliac spine** to **pubic tubercle** interdigitating with each other above the **pubic symphysis** across the front of the **rectus abdominis** to the whole length of the **linea alba** up to the **xiphisternum** as the only structure in the anterior sheath of the rectus muscle **above the costal margin**

External oblique muscle ●.....→

Anterior superior iliac spine ●.....→

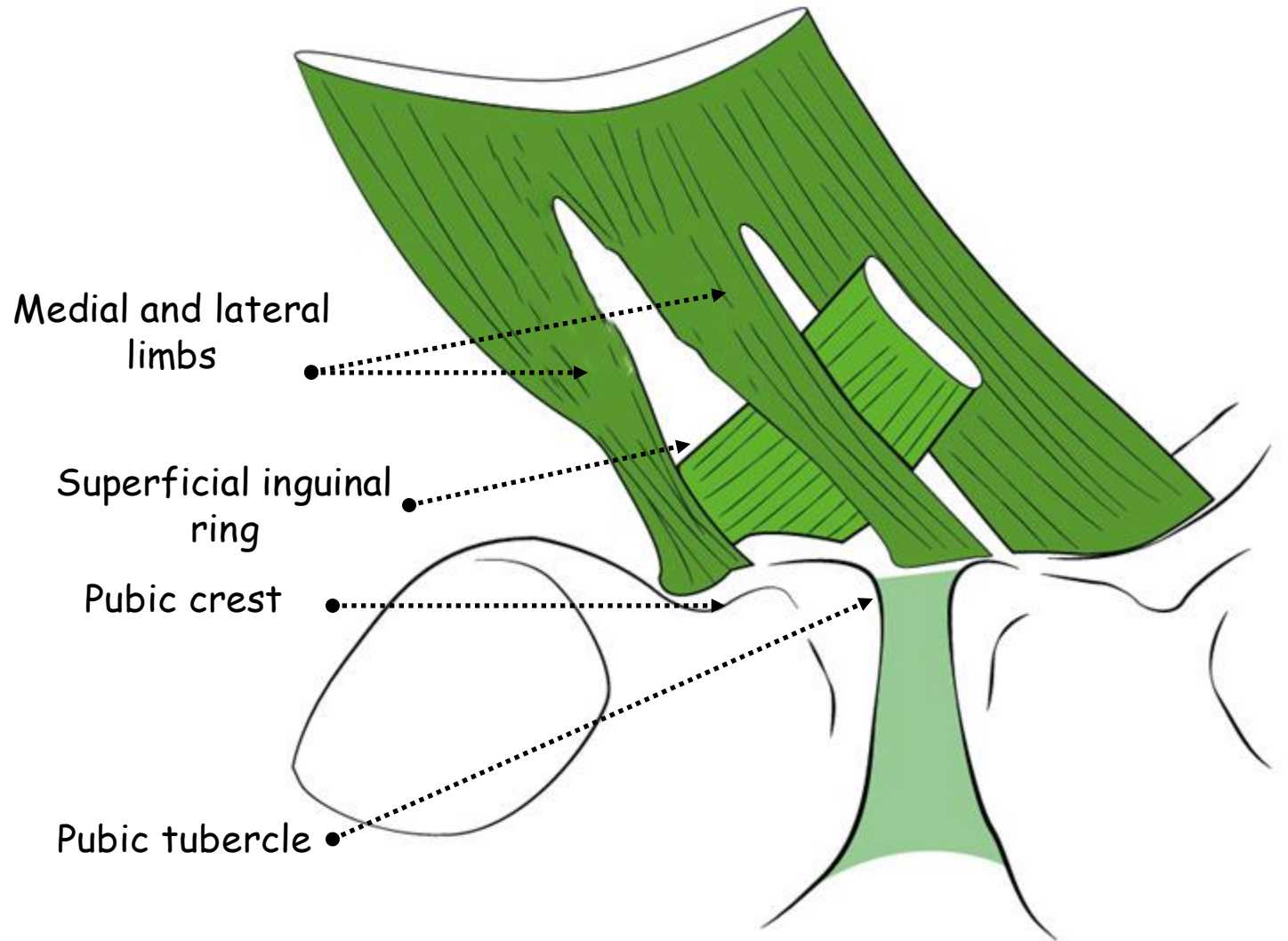
Inguinal ligament ●.....→

Pubic crest ●.....→



LATERAL VIEW OF THE SKELETON OF THE TRUNK SHOWING THE EXTERNAL OBLIQUE MUSCLE

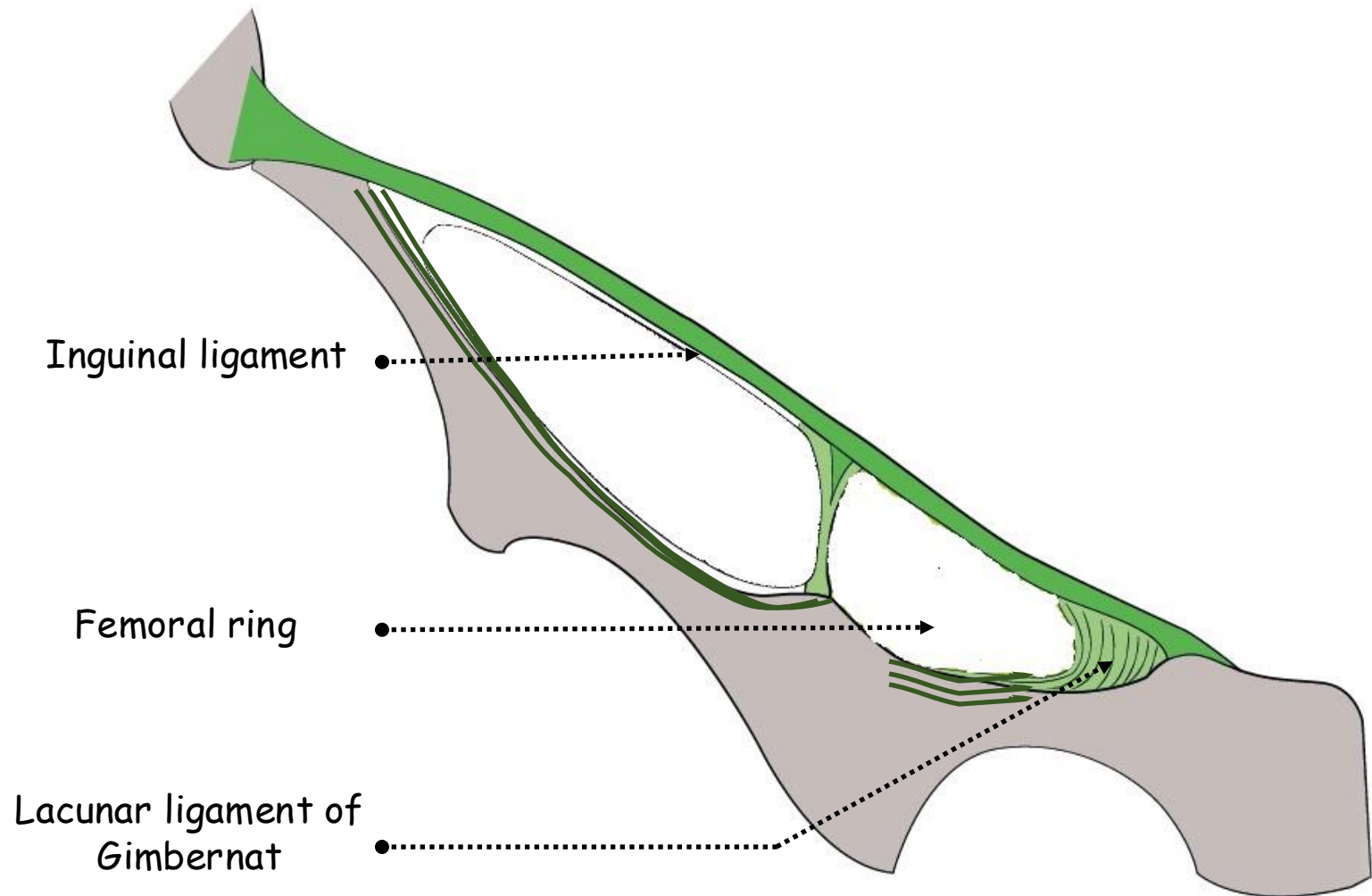
-Downwards: forms the inguinal ligament of Poupart between the anterior superior iliac spine and the pubic tubercle and the superficial inguinal ring, V-shaped, with medial limb down to the pubic tubercle and lateral limb down to the pubic crest



ANTERIOR VIEW OF THE PUBIS SHOWING THE PELVIC INSERTIONS OF EXTERNAL OBLIQUE MUSCLE

- **Inguinal ligament:**

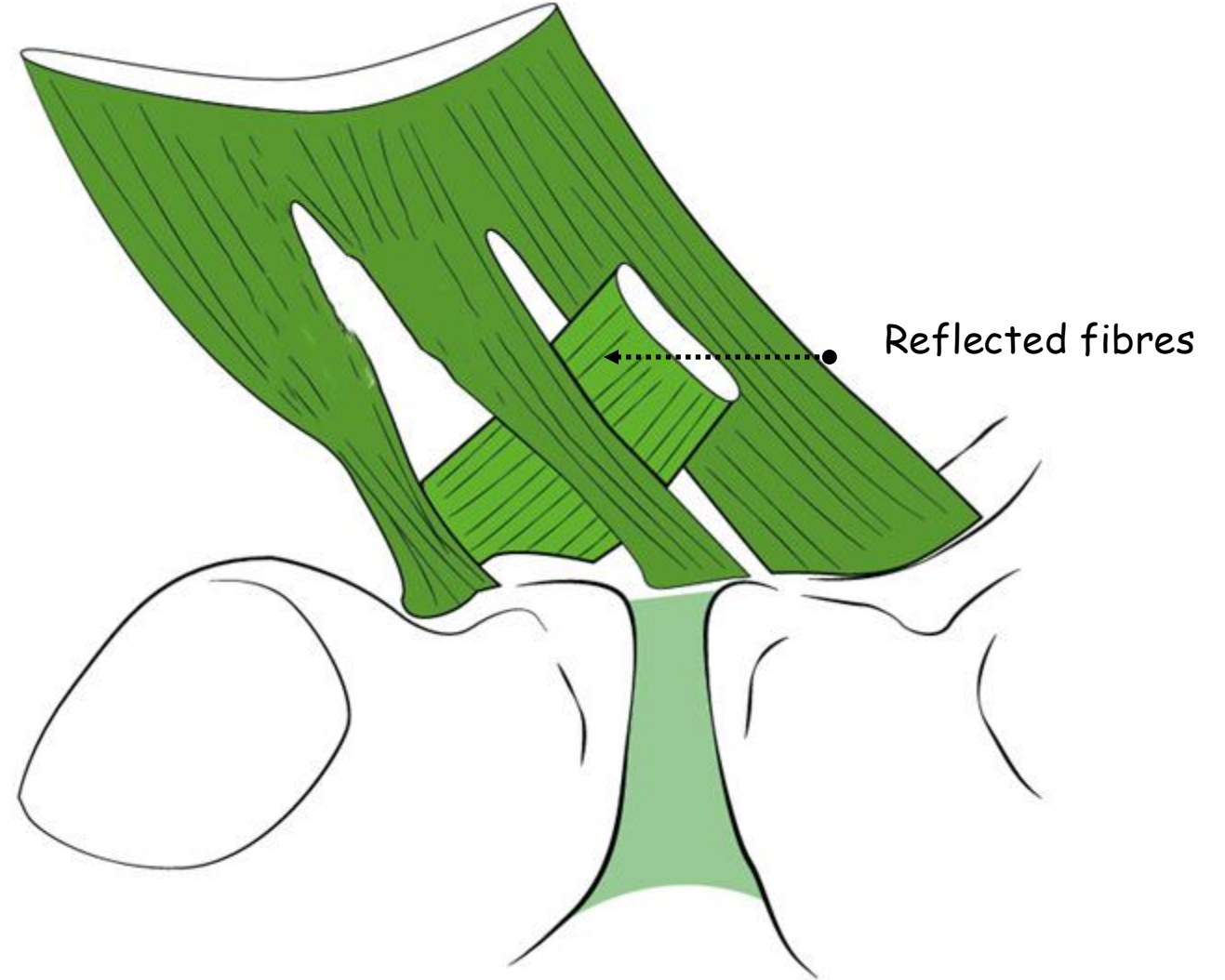
- Extends from the anterior superior iliac spine to the pubic tubercle
- Rolled inwards to form a gutter
- Lateral end: origin to part of the internal oblique and transversus abdominis muscles
- Medial end: lacunar ligament of Gimbernat extends backwards to the pectineal line forming with its crescentic free edge the medial margin of the femoral ring



ANTERIOR VIEW OF THE HIP BONE SHOWING THE INGUINAL LIGAMENT

-Reflected fibres: traced upwards and medially, behind the spermatic cord to interdigitate in the linea alba with those of the opposite side

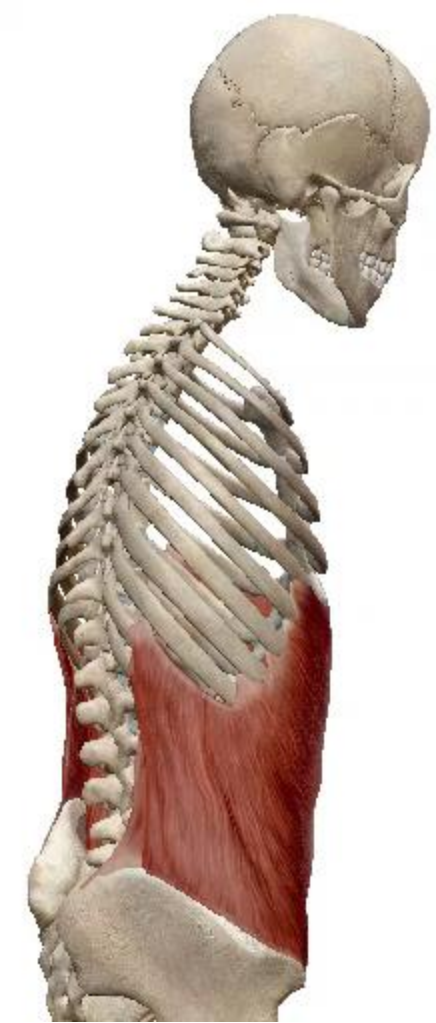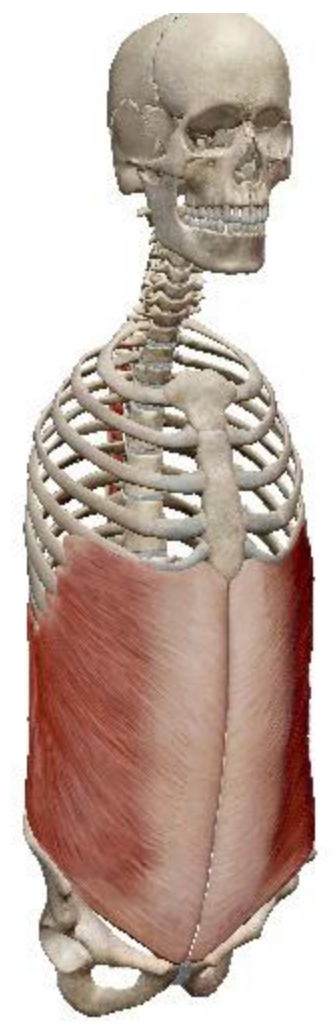
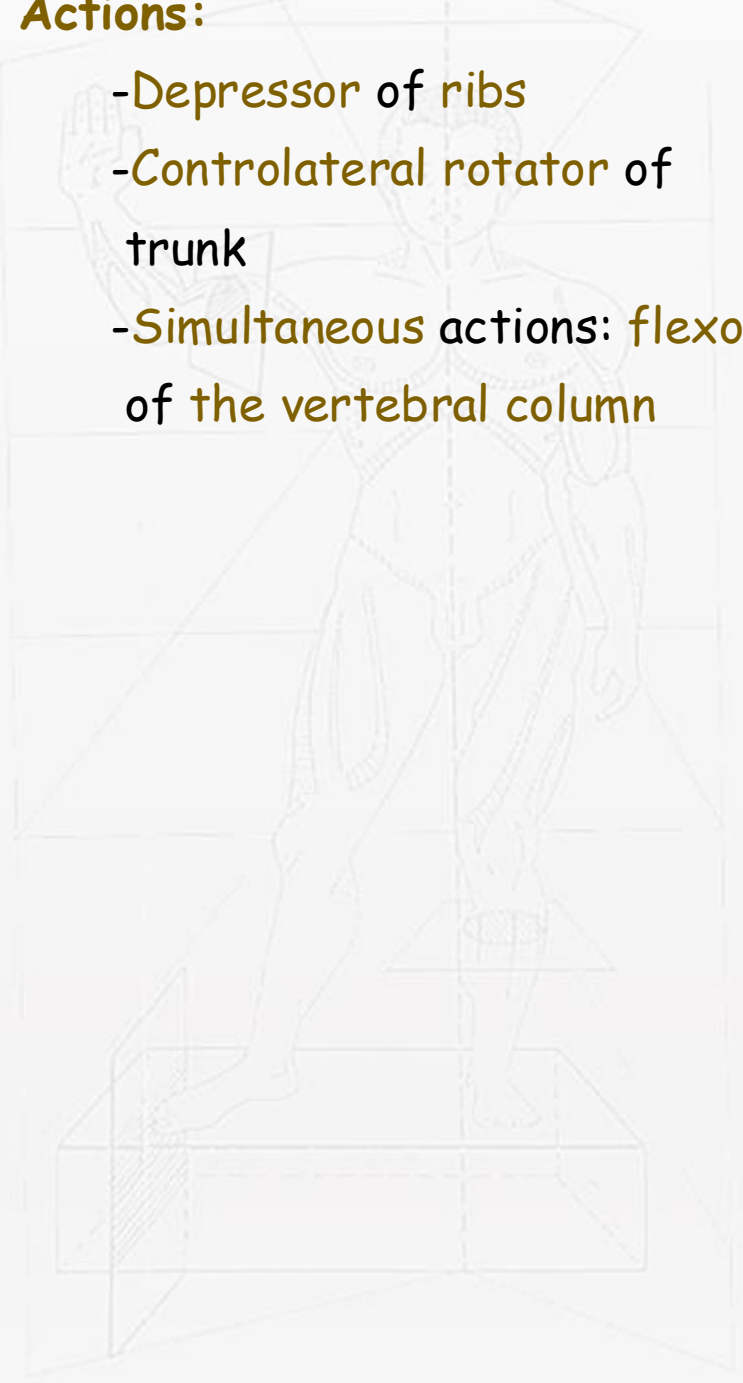
-Intercrural fibres: fibres running at right angles to the limbs near the apex of the superficial inguinal ring preventing them from separating



ANTERIOR VIEW OF THE PUBIS SHOWING THE PELVIC INSERTIONS OF EXTERNAL OBLIQUE MUSCLE

• **Actions:**

- Depressor of ribs
- Controlateral rotator of trunk
- Simultaneous actions: flexor of the vertebral column



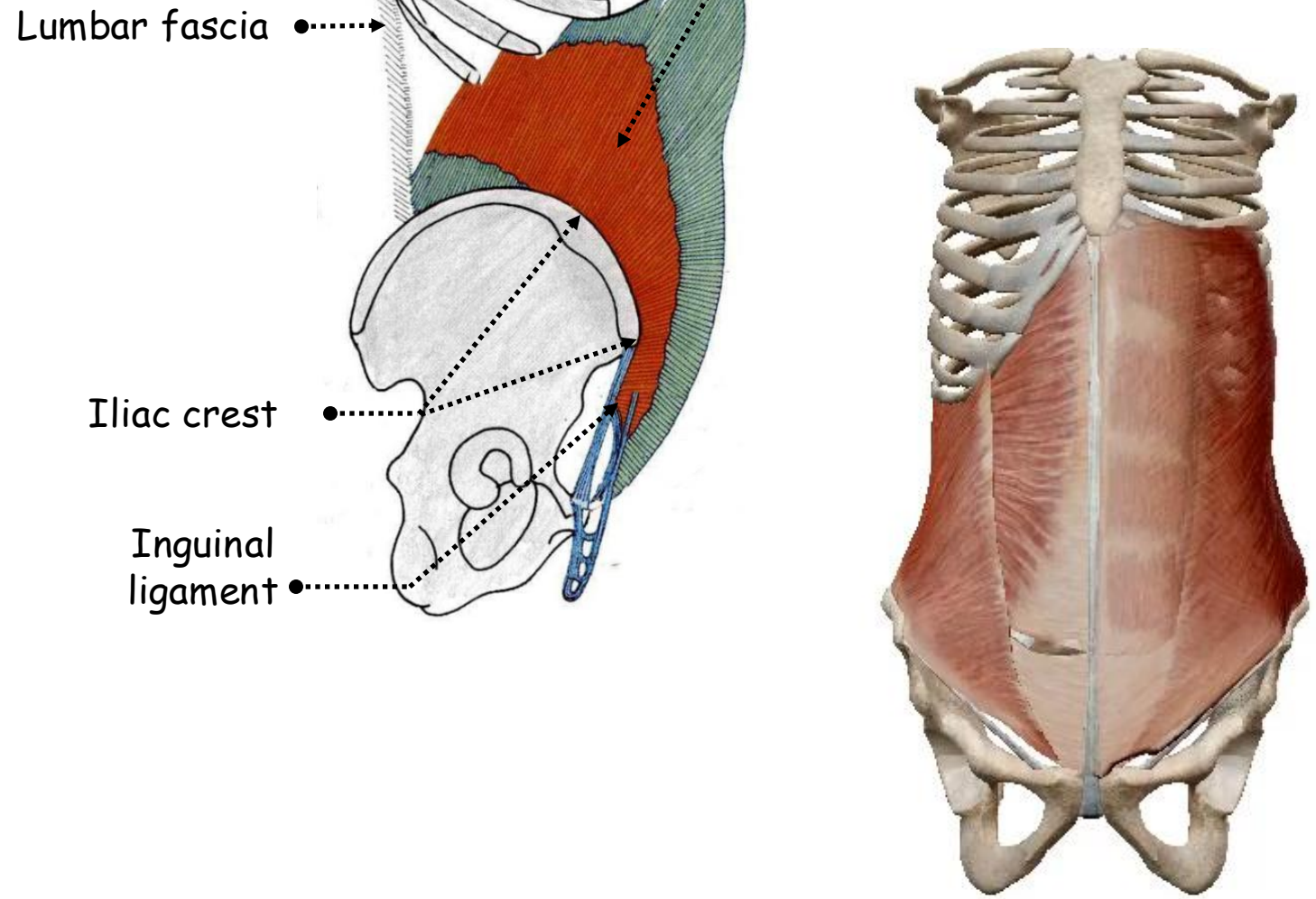
8. Internal oblique muscle:

- **Fleshy fibres:**

- The whole length of the lumbar fascia
- The intermediate area of the anterior two-thirds of the iliac crest
- The lateral two-thirds of the inguinal ligament

- **From the lumbar fascia:**

- Run upwards along the costal margin, to which they are attached
- Become aponeurotic at the tip of the ninth costal cartilage
- Split around the rectus muscle below the costal margin joining the linea alba



Lumbar fascia

Iliac crest

Inguinal ligament

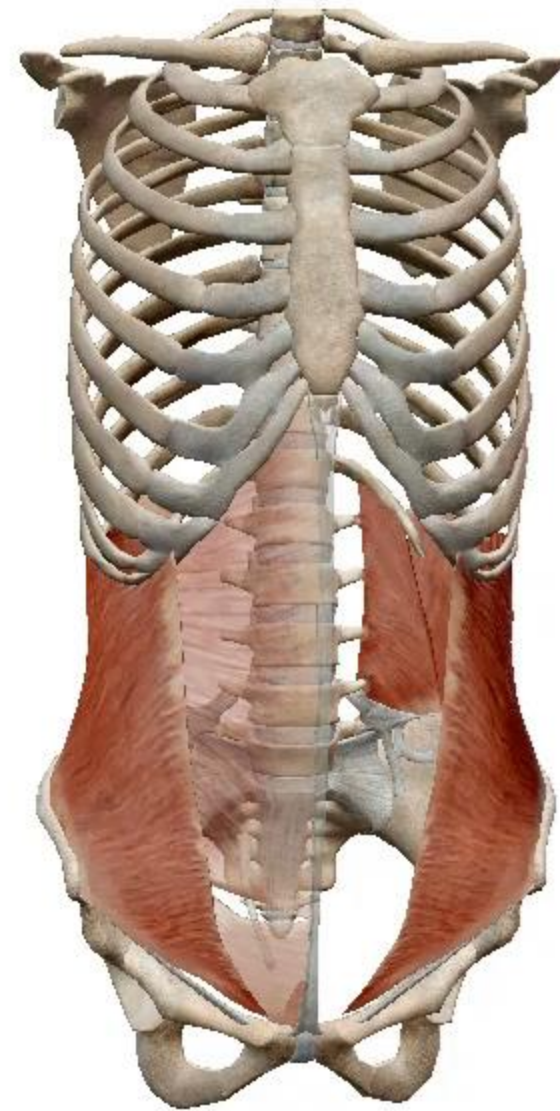Internal oblique muscle

LATERAL VIEW OF THE SKELETON OF THE TRUNK SHOWING THE INTERNAL OBLIQUE MUSCLE

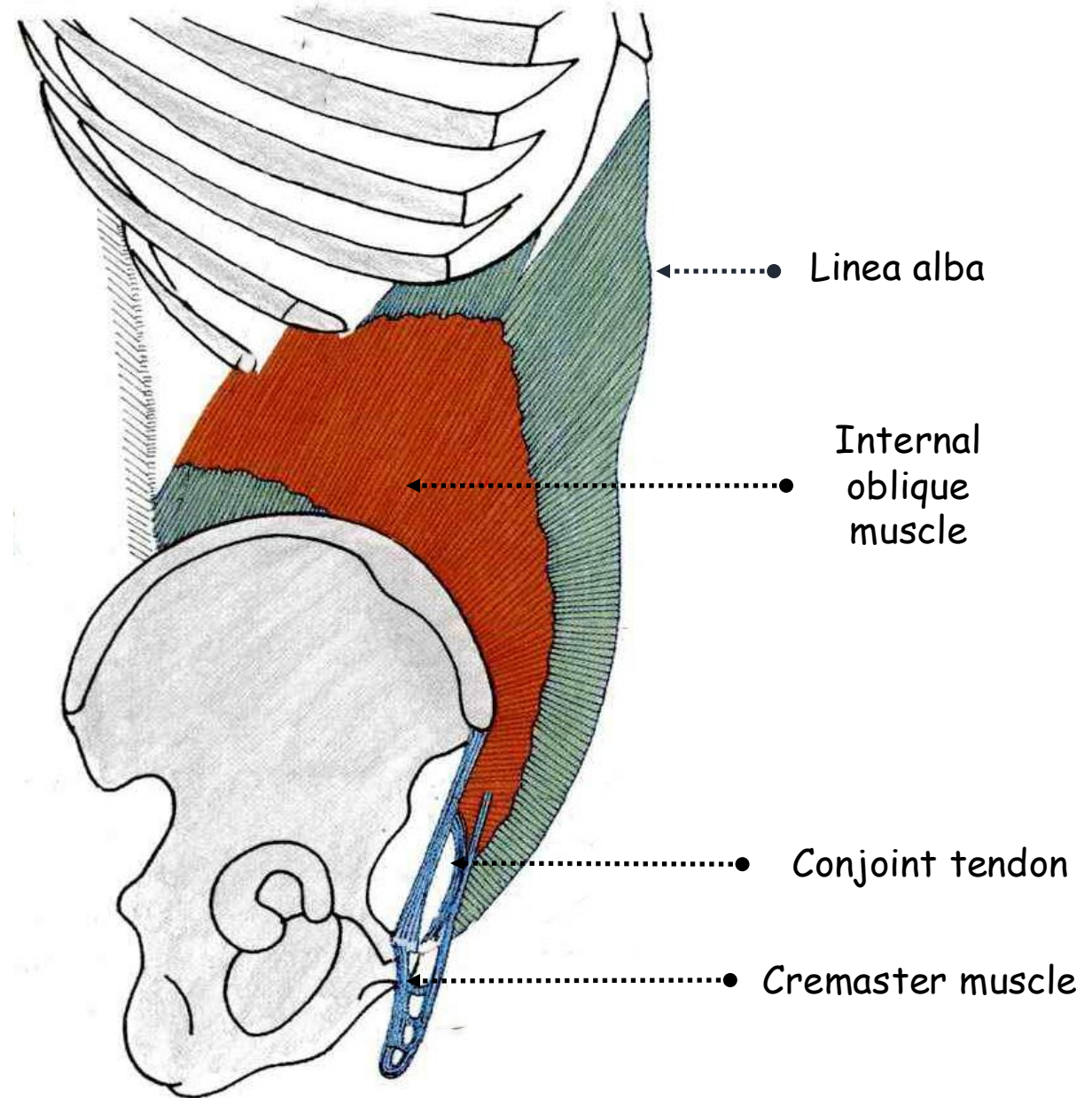
-Anterior layer adheres to tendinous intersections
-2.5 cm below the umbilicus the posterior layer ends in a curved free margin, concave downwards, the arcuate line of Douglas

- **From the inguinal ligament:**

-Continued into an aponeurosis that is attached to the crest of the pubic bone and, more laterally, to the pectineal line
-Lateral margin: consists of muscle fibres in front of the spermatic cord continuous with cremaster muscle



-Medial margin: consists of tendinous fibres behind the cord fused with a similar arrangement of the transversus aponeurosis to form the conjoint tendon



LATERAL VIEW OF THE SKELETON OF THE TRUNK SHOWING THE INTERNAL OBLIQUE AND CREMASTER MUSCLES

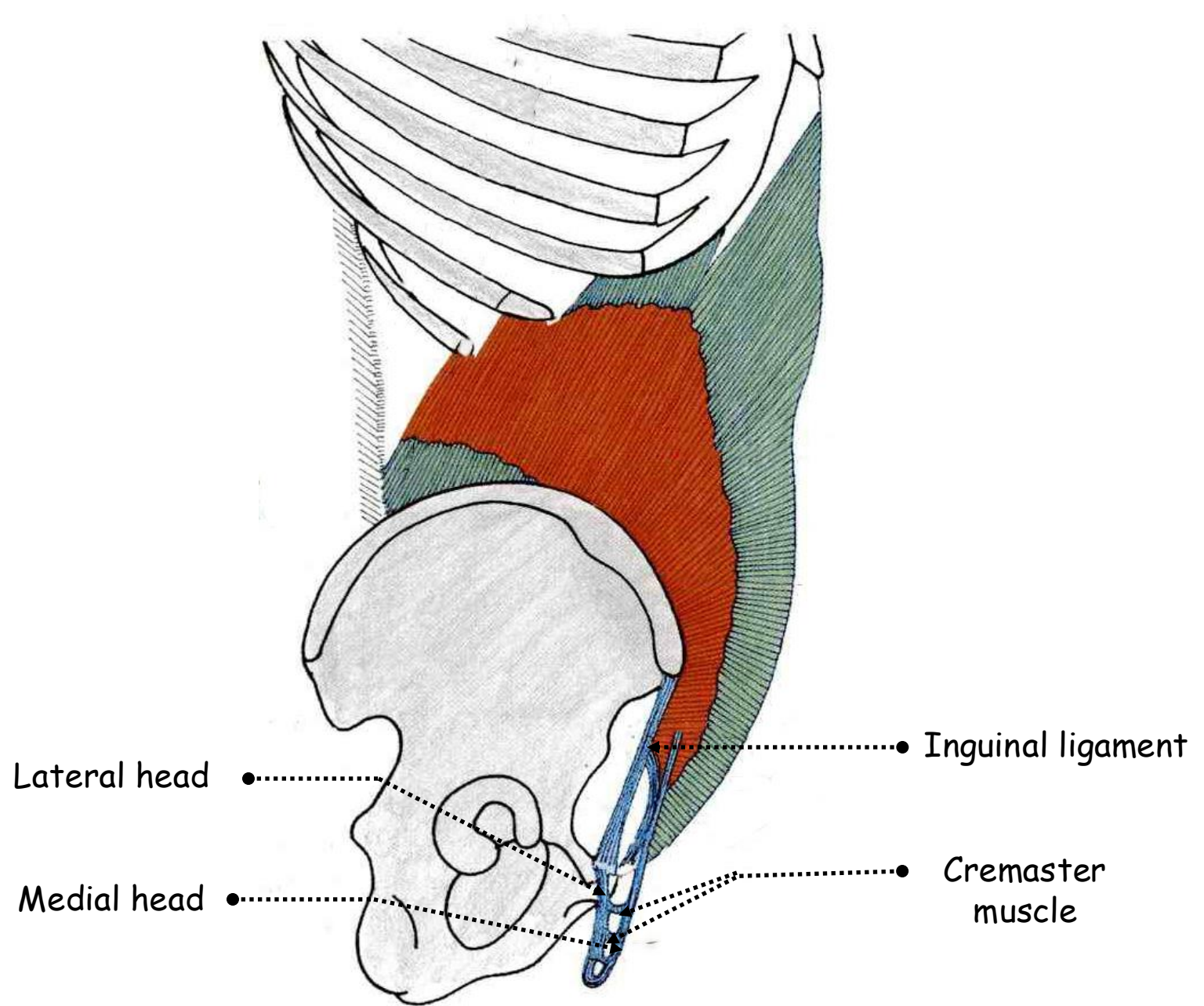
• **Action:**

- Compressor of the abdomen
- Ipsilateral rotator of trunk
- Simultaneous actions: flexor of the vertebral column



9. Cremaster muscle:

- Muscular wall of the spermatic cord
- Lateral head: continuous with the lateral margin of the internal oblique aponeurosis, ends in the anterolateral part of the cremasteric fascia
- Medial head: attached to the pubis, ends in the posteromedial part of the cremasteric fascia

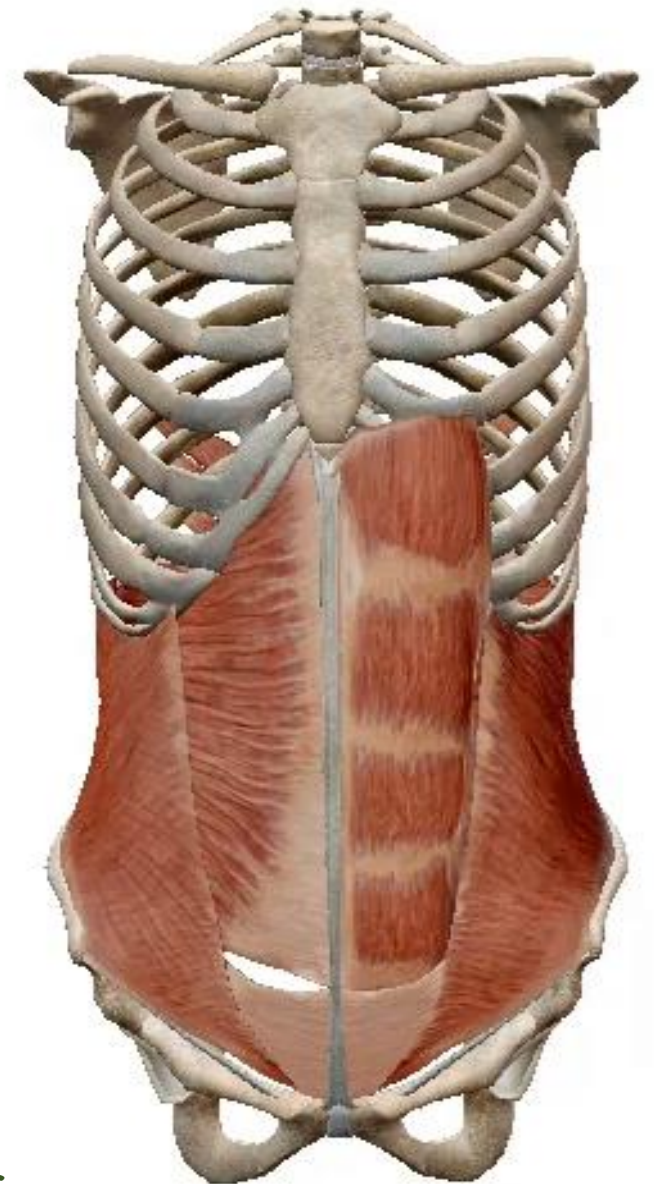
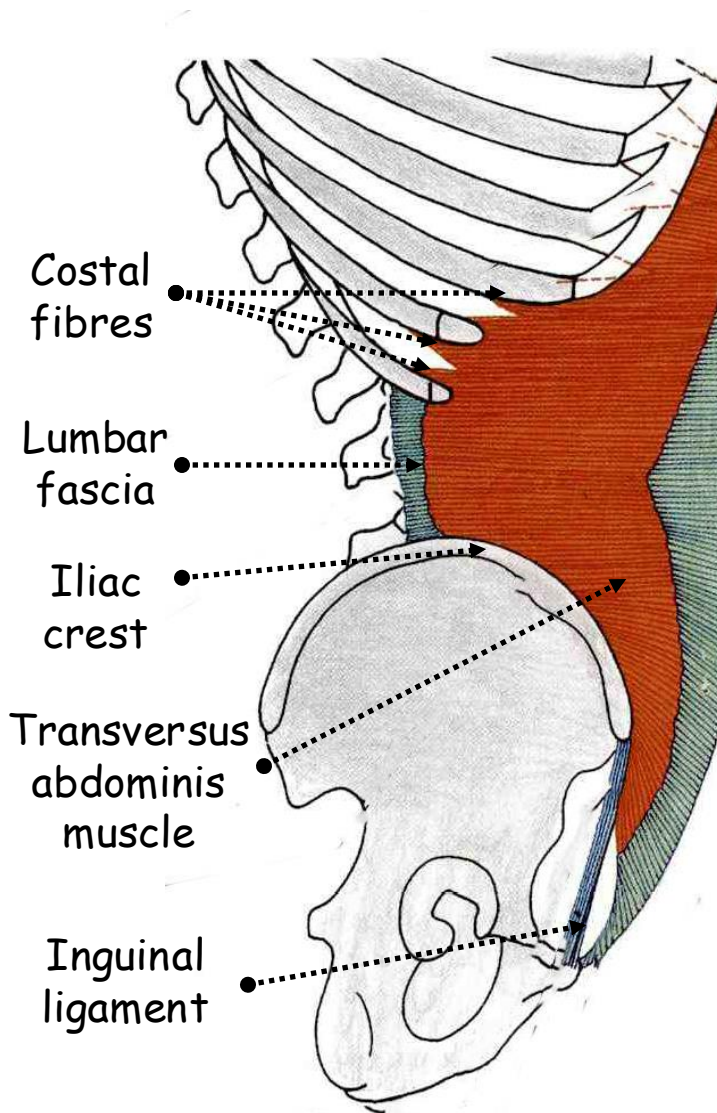


LATERAL VIEW OF THE SKELETON OF THE TRUNK SHOWING THE INTERNAL OBLIQUE AND CREMASTER MUSCLES

10. Transversus abdominis muscle:

• **Fleshy fibres:**


- Inside each costal cartilage of the whole costal margin interdigitating with the costal origin of the diaphragm
 - Lumbar fascia lateral to the quadratus lumborum
 - Internal lip of the anterior two-thirds of the iliac crest
 - Fascia over iliacus
 - From the lateral half of the inguinal ligament deep to the internal oblique
- Become **aponeurotic** and fuses with the **posterior layer of the internal oblique aponeurosis**
 - Fuses laterally downwards with the **internal oblique** to form the **conjoint tendon** behind the spermatic cord



LATERAL VIEW OF THE SKELETON OF THE TRUNK SHOWING THE TRANSVERSUS ABDOMINIS MUSCLE

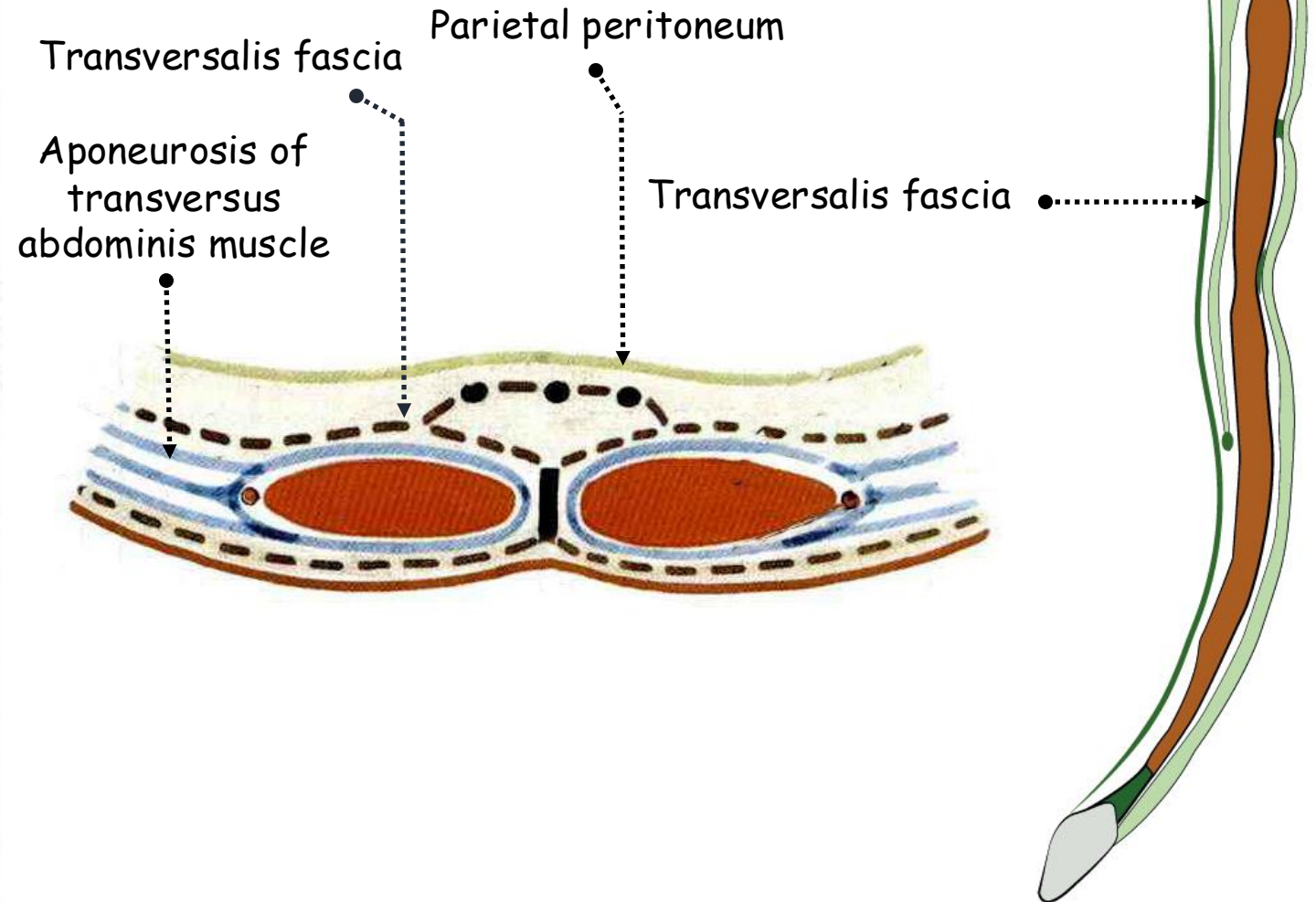
- **Action:**

-Compressor of the abdomen



11. Transversalis fascia:

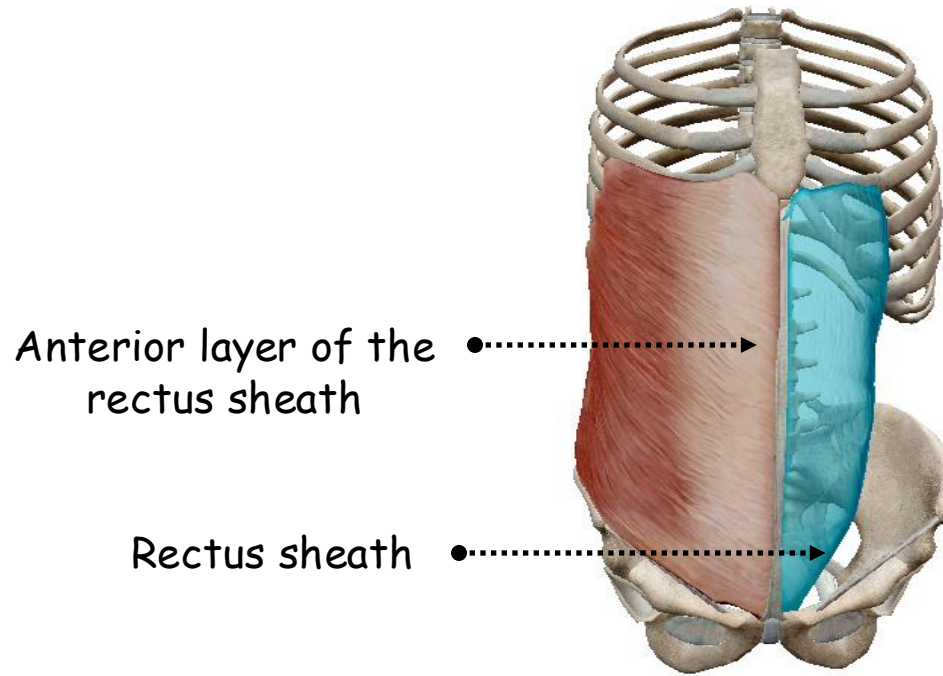
- Loose and cellular aponeurosis
- Interposed between the posterior layer of rectus sheath forwards and the aponeurosis of transversus abdominis muscle laterally and the parietal peritoneum backwards
- Lower thickened part of the transversalis fascia below the arcuate line of Douglas between the iliac crest and pubis
- Iliopubic tract
- Medial boundary of the femoral ring



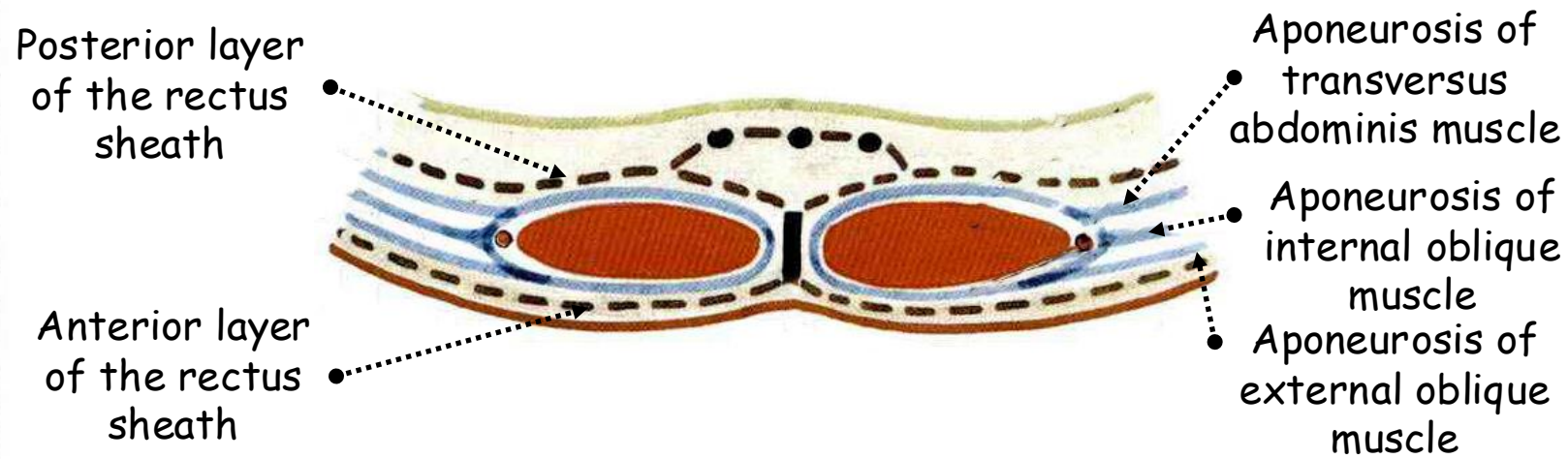
HORIZONTAL AND SAGITTAL SECTIONS OF THE ANTERIOR ABDOMINAL WALL SHOWING THE TRANSVERSALIS FASCIA

12. Rectus sheath:

- The aponeurosis of the internal oblique splits into anterior and posterior layers to enclose the rectus muscle
- The external oblique aponeurosis fuses with the anterior layer to form the anterior layer of the sheath
- The transversus aponeurosis fuses with the posterior layer to form the posterior layer of the sheath
- The posterior layer of the sheath is attached to the costal margin, seventh, eighth and ninth costal cartilages consisting of the transversus and internal oblique layers
- The anterior layer of the sheath is attached to the fifth, sixth and seventh cartilages consisting of the external oblique layer

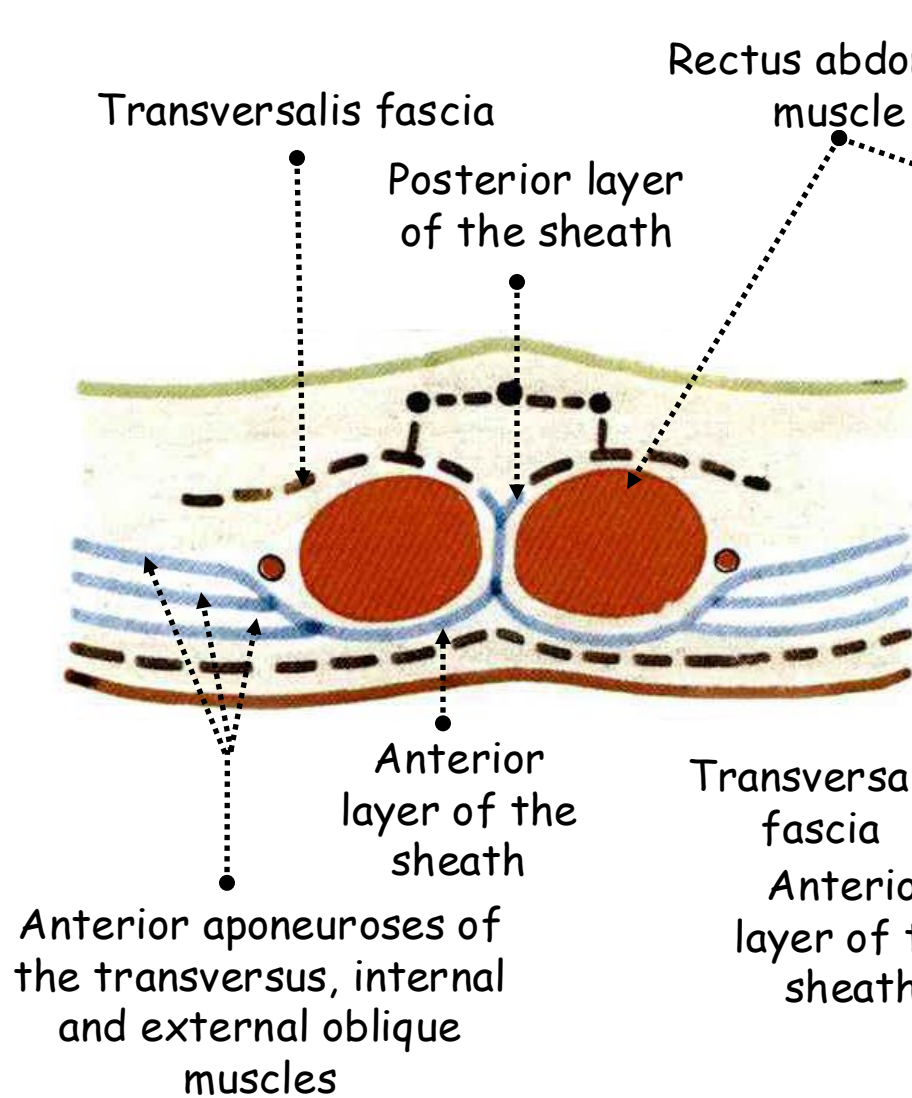


ANTERIOR VIEW OF THE SKELETON OF THE TRUNK SHOWING THE RECTUS SHEATH



HORIZONTAL SECTION OF THE ANTERIOR ABDOMINAL WALL ABOVE THE UMBILICUS

- Below the umbilicus the aponeuroses of internal oblique and transversus fuse completely
- That of the external oblique fuses only to the most medial part of the sheath
- 2.5 cm below the umbilicus all three aponeuroses pass in front of the muscle
- Free lower margin to the posterior layer
- Concave and ill-defined
- Between the linea alba and the lateral border of rectus muscle
- The arcuate line or the semicircular line of Douglas



HORIZONTAL SECTION OF THE ANTERIOR ABDOMINOINAL WALL BELOW THE UMBILICUS

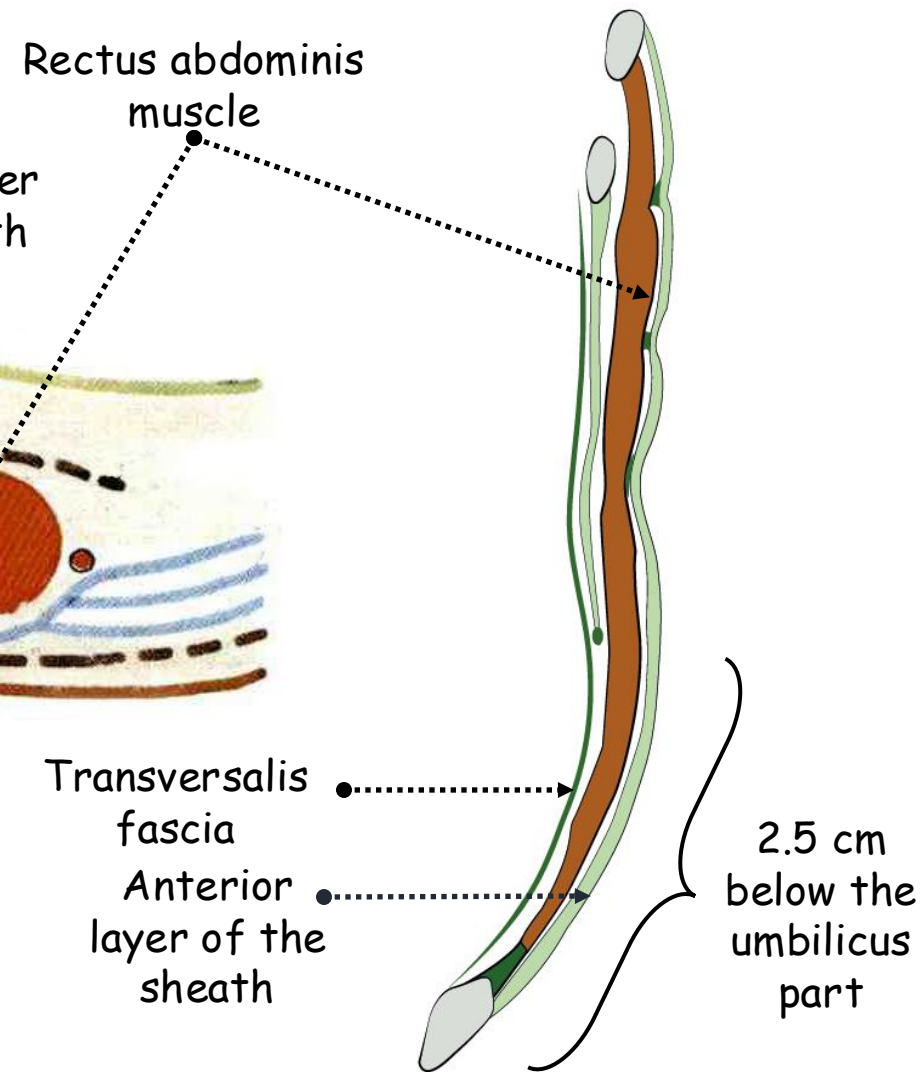
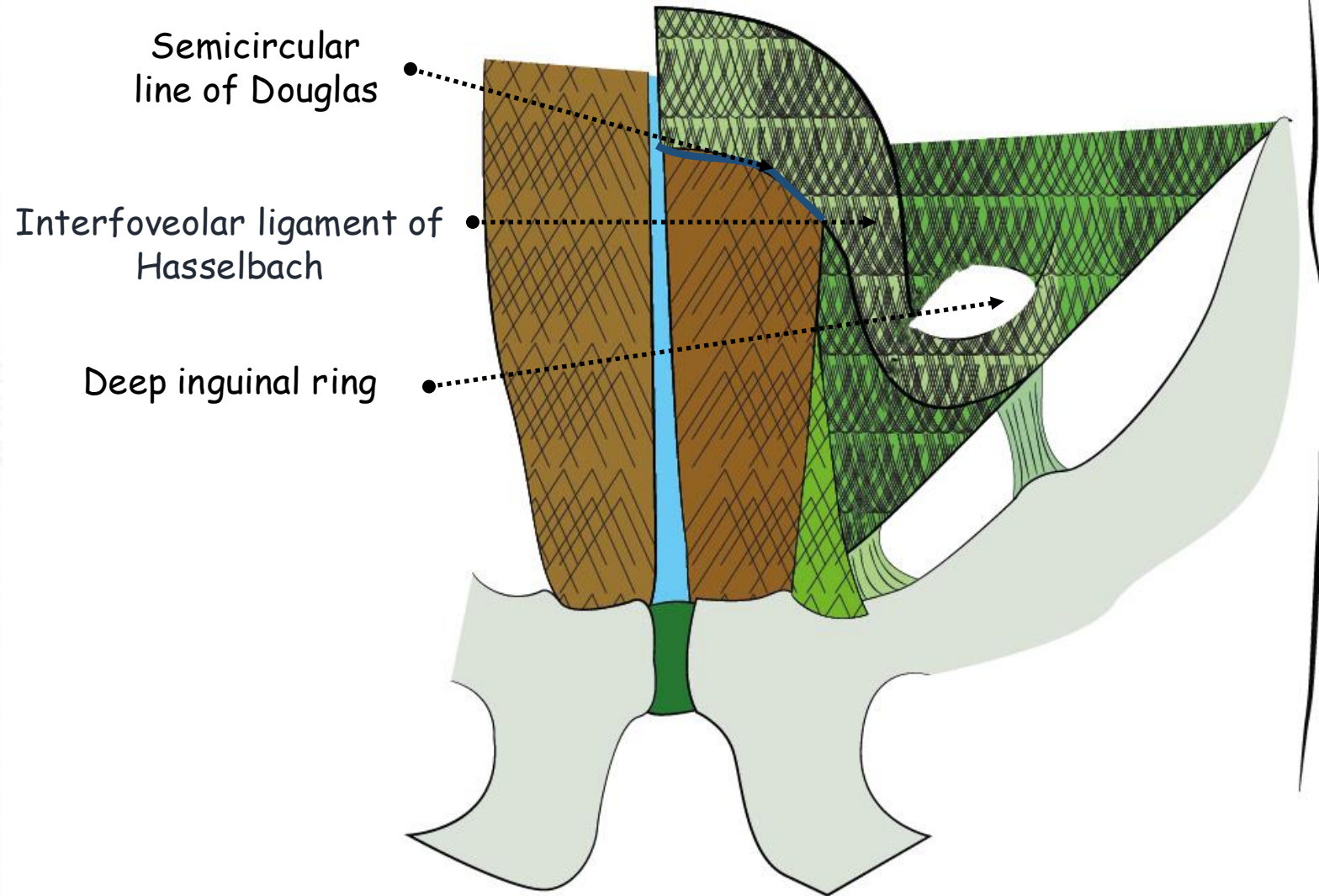


FIGURE SHOWING THE RECTUS SHEATH

13. Interfoveolar ligament of Hasselbach:

- Fibrous band that extends laterally from the **semicircular line of Douglas**
- Sloping downwards and laterally
- Crosses backwards the spermatic cord in men and the round ligament in women towards the deep inguinal ring



POSTERIOR VIEW OF THE INGUINAL CANAL SHOWING THE DEEP INGUINAL RING

14. Linea alba:

- Medial border of the recti abdominis muscles
- Most medial part of the rectus sheath
- Midline fusion of the aponeuroses of external oblique and internal oblique forwards and transversus abdominis and internal oblique backwards
- Forms a median groove at the midline

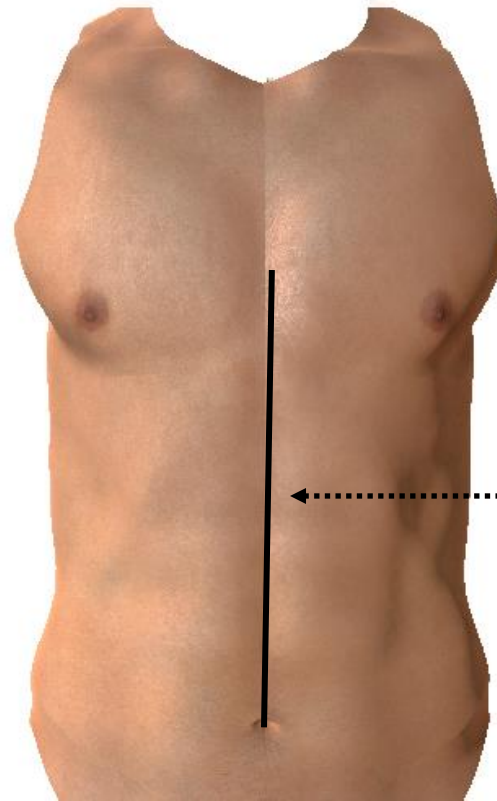
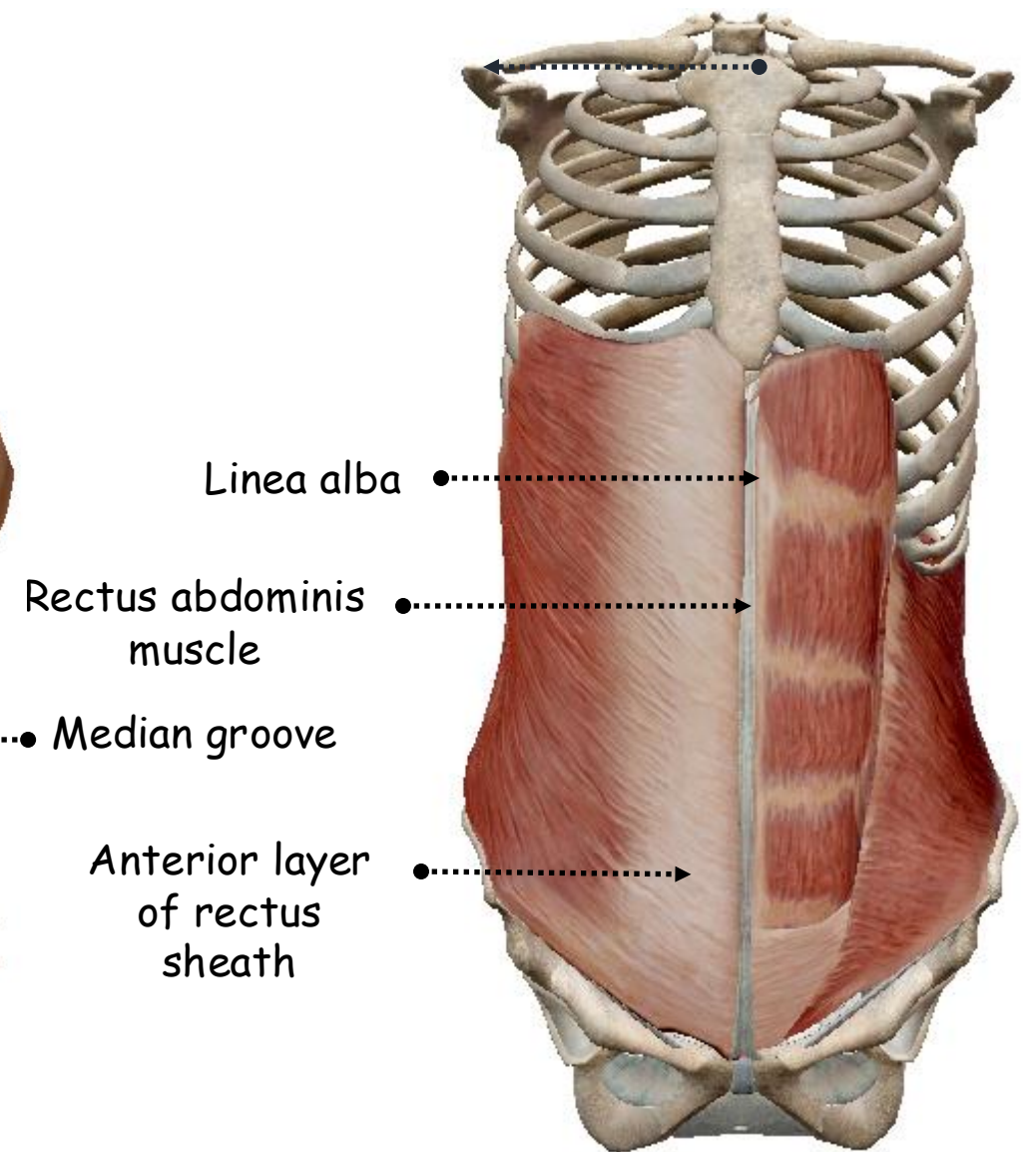


FIGURE SHOWING THE
MEDIAN GROOVE OF THE
LINEA ALBA



ANTERIOR VIEW OF THE SKELETON
OF THE TRUNK SHOWING THE
RECTUS ABDOMINIS MUSCLE AND
ITS SHEATH

- Extends from the xiphisternum to the pubic tubercle
- Umbilicus: midway
- Above the umbilicus: larger
- Weakness zone

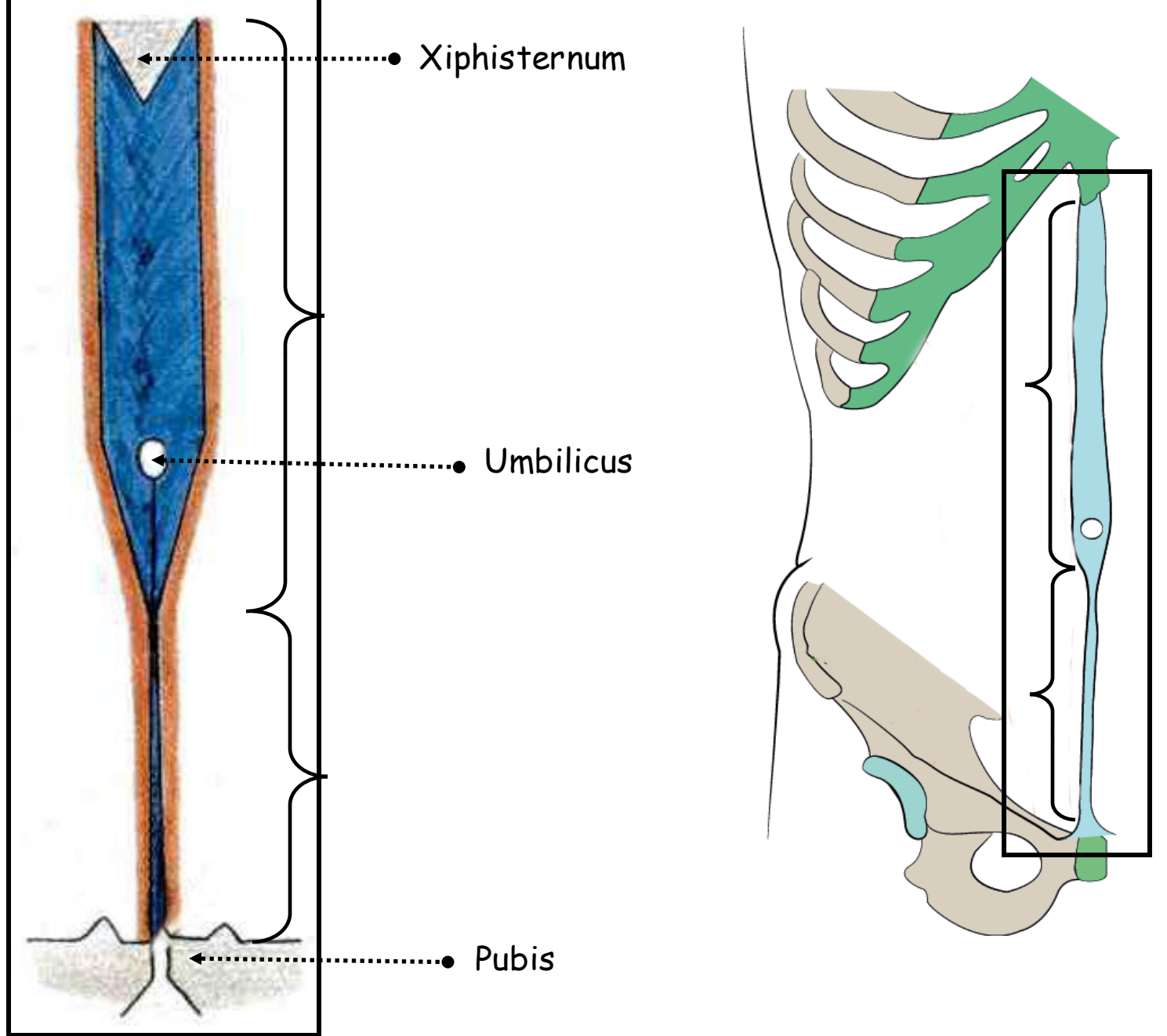


FIGURE SHOWING THE LINEA ALBA

15. Semilunar line:

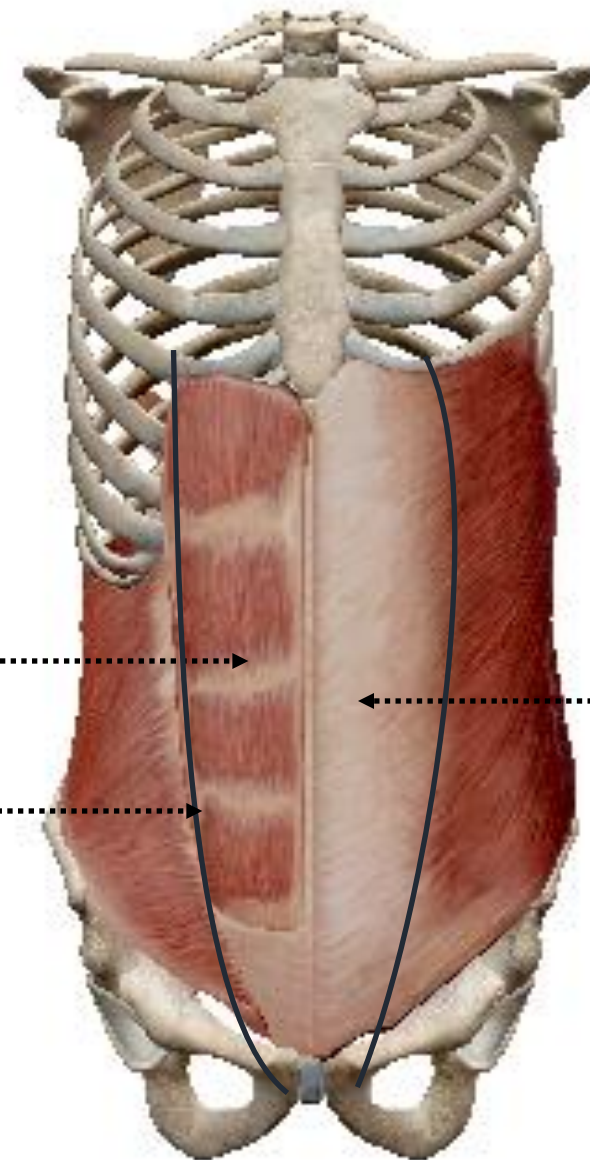
- Splitting of the internal oblique aponeurosis
- Along the lateral border of the rectus muscle
- Shallow and bloodless groove
- Curves up from the pubic tubercle to the costal margin at the tip of the ninth costal cartilage
- Not to be confused with the semicircular line
- **Weakness zone**

Rectus abdominis muscle

Semilunar line

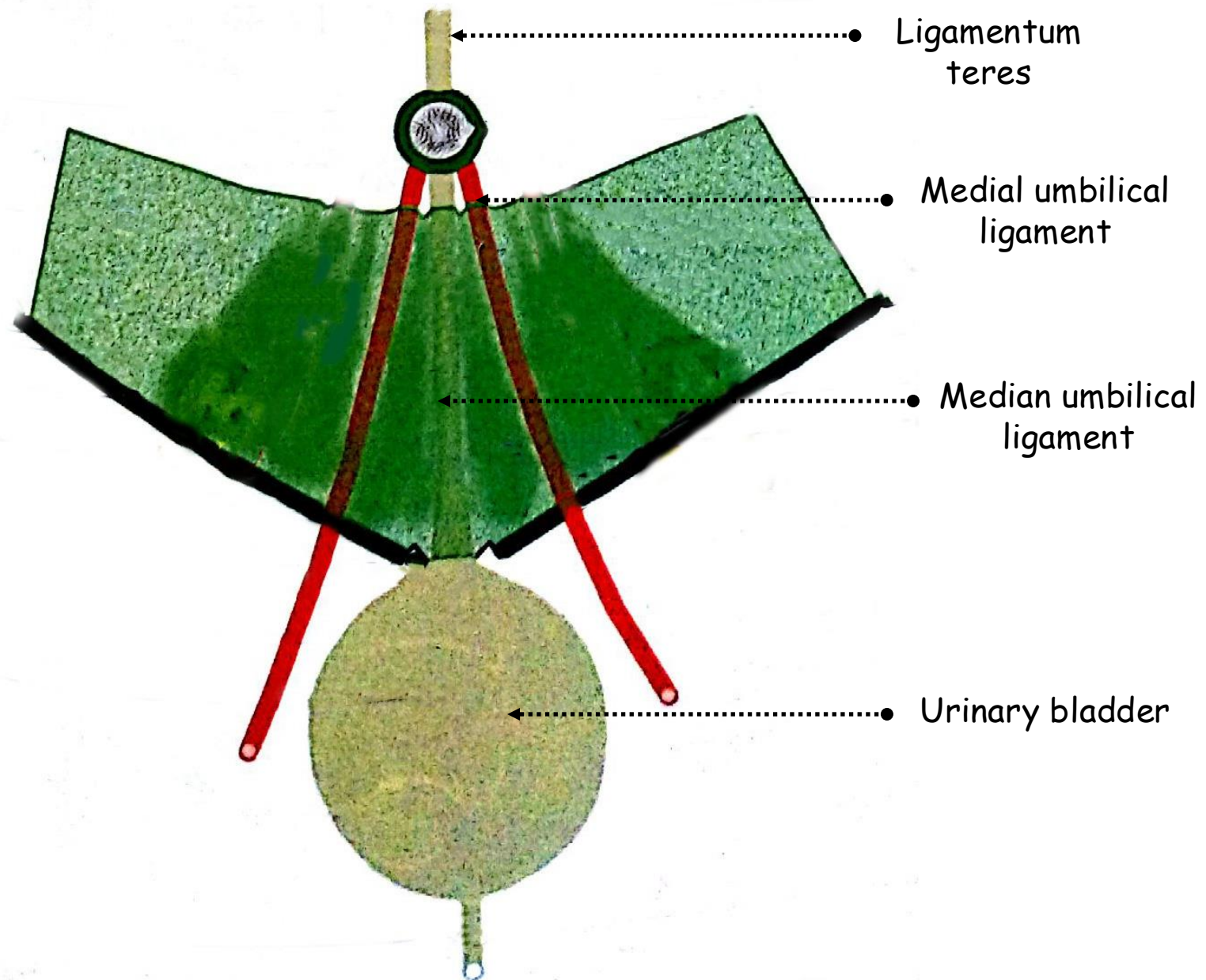
Anterior layer of rectus sheath

ANTERIOR VIEW OF THE SKELETON OF THE TRUNK SHOWING THE RECTUS ABDOMINIS MUSCLE AND ITS SHEATH



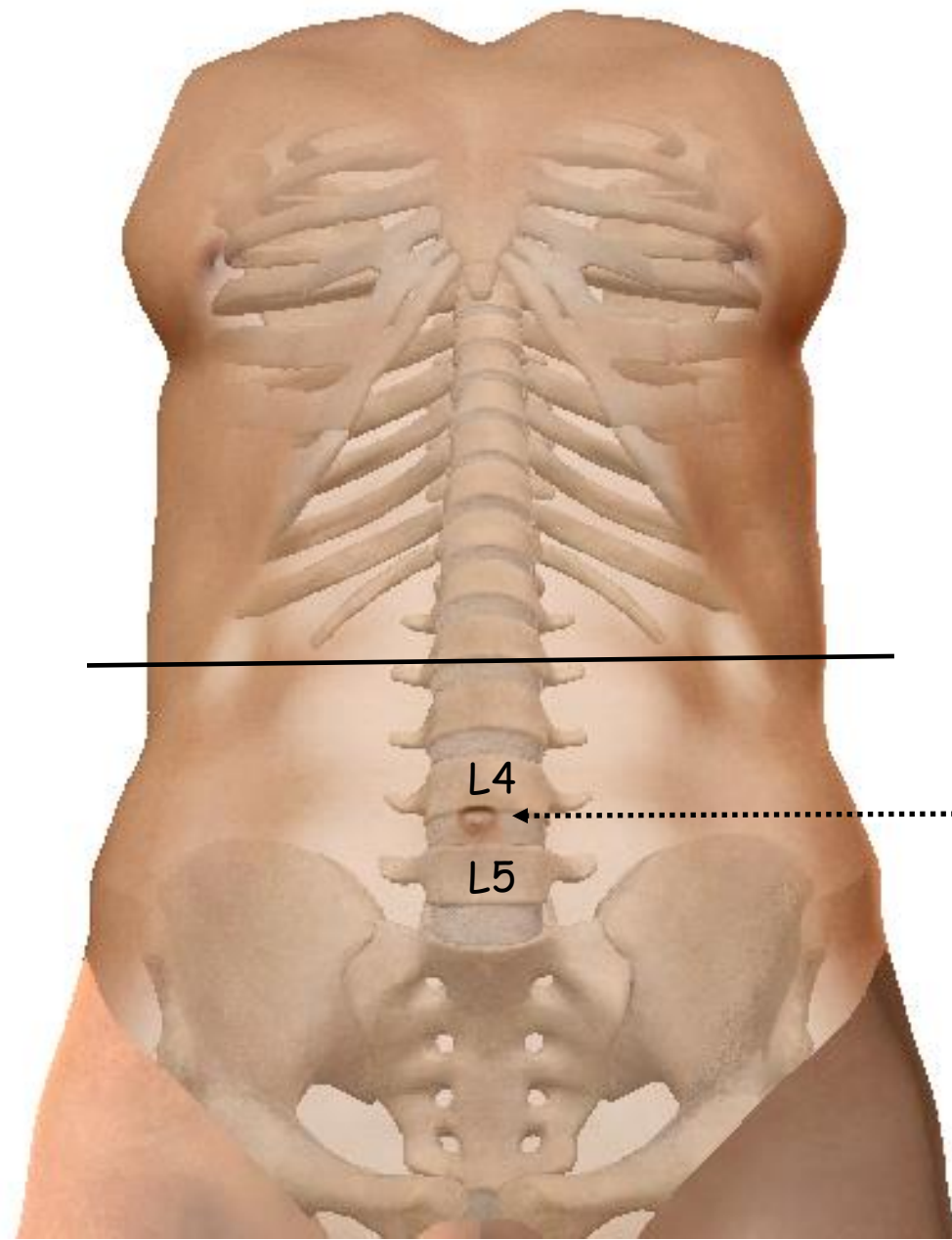
16. Umbilicus:

- Fibrous scar of the umbilical cord
- Fetal-maternal connection
- Contains the obliterated orifices of the three umbilical vessels
- **Ligamentum teres:** remnant of umbilical vein
- **Median umbilical ligament:** remnant of the urachus
- **Medial umbilical ligaments:** on each side of the median umbilical ligament remnants of the umbilical arteries
- **Ileal Meckel's diverticulum:** remnant of the villointestinal duct which apex may be adherent to the umbilicus or connected thereto by a fibrous cord



POSTERIOR VIEW OF THE UMBILICUS

- Variable situation
- Towards L4 vertebra
- Below midway between the xiphisternum and the pubic symphysis

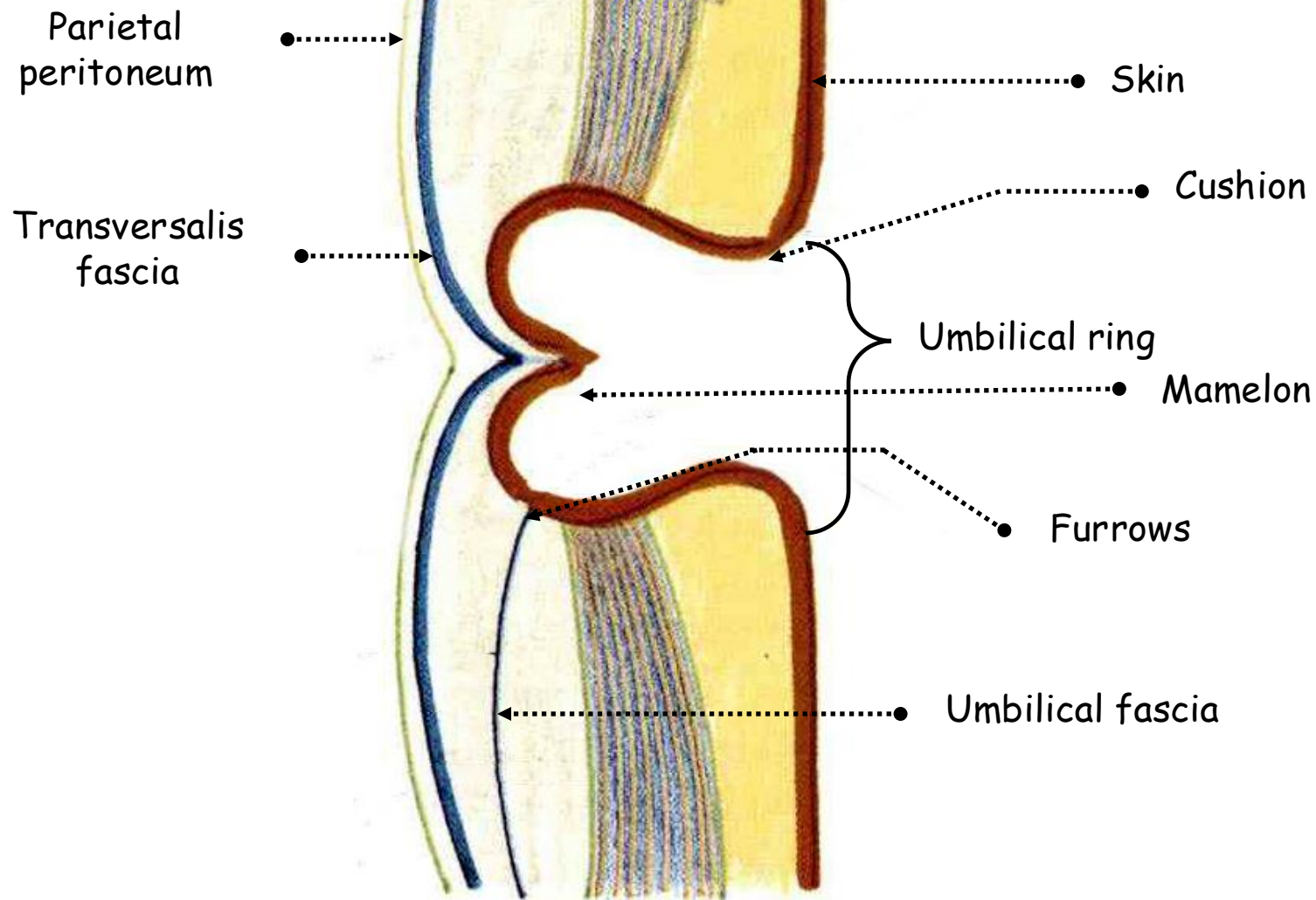


L4
L5

Umbilicus

ANTERIOR VIEW OF THE TRUNK

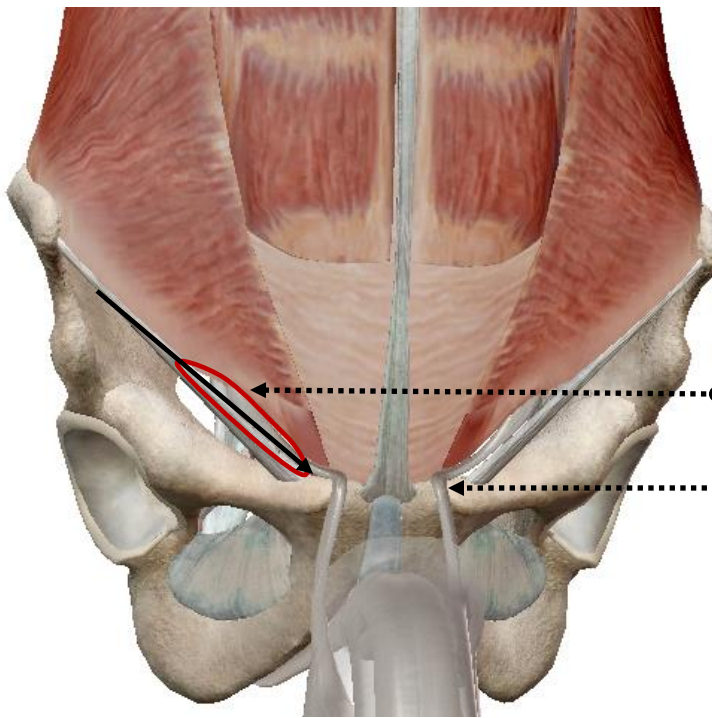
- **Mamelon:** central hump of the umbilicus
- **Cicatrix:** fusion of the fibrous structures of the umbilicus with transversalis fascia, umbilical fascia and parietal peritoneum
- **Cushion:** slightly raised skin margin which surrounds the mamelon and the cicatrix and contains the umbilical ring continuous with the linea alba
- **Furrows:** depressions surrounding the mamelon
- Important landmark of the anterior abdominal wall
- **Weakness zone**



SAGITTAL SECTION OF THE ANTERIOR ABDOMINAL WALL SHOWING THE UMBILICUS

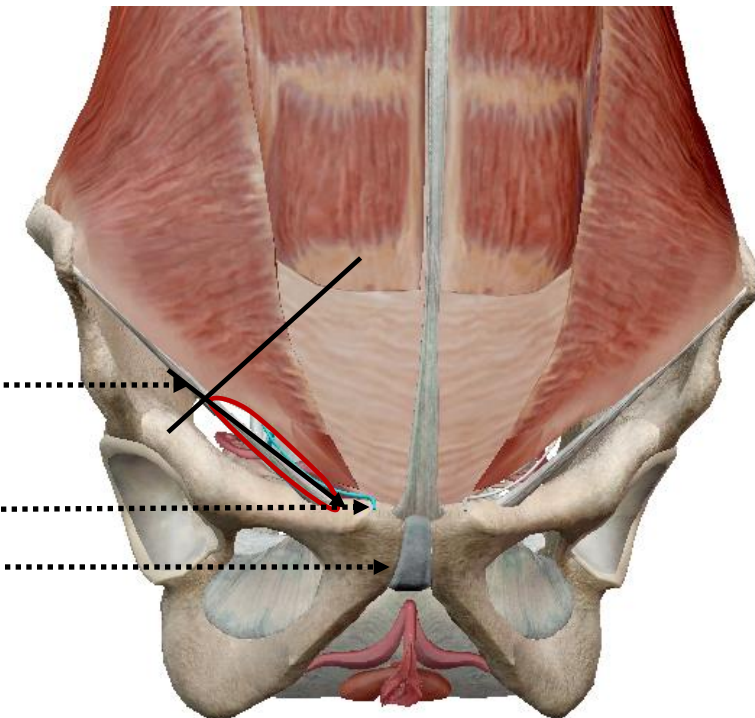
17. Inguinal canal:

- Oblique columnar intermuscular slit
- 6cm long
- Lies above the medial half of the inguinal ligament
- Sloping forwards and medially
- Transmits the spermatic cord and ilioinguinal nerve in the male
- Transmits the round ligament of the uterus and ilioinguinal nerve in the female
- Weakness zone



● Inguinal canal

● Spermatic cord



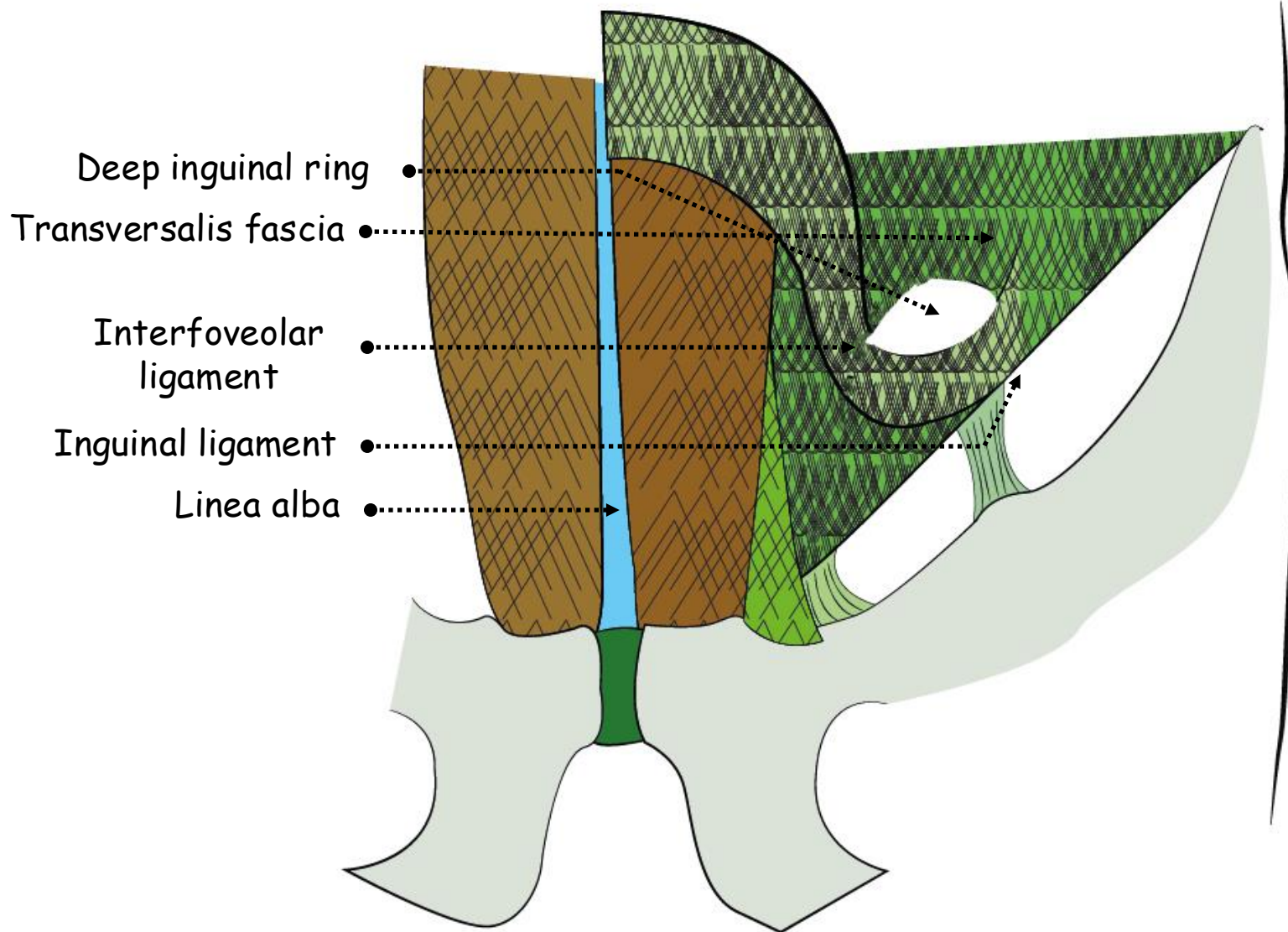
Inguinal ligament ●

Round ligament of the uterus ●

Pubis ●

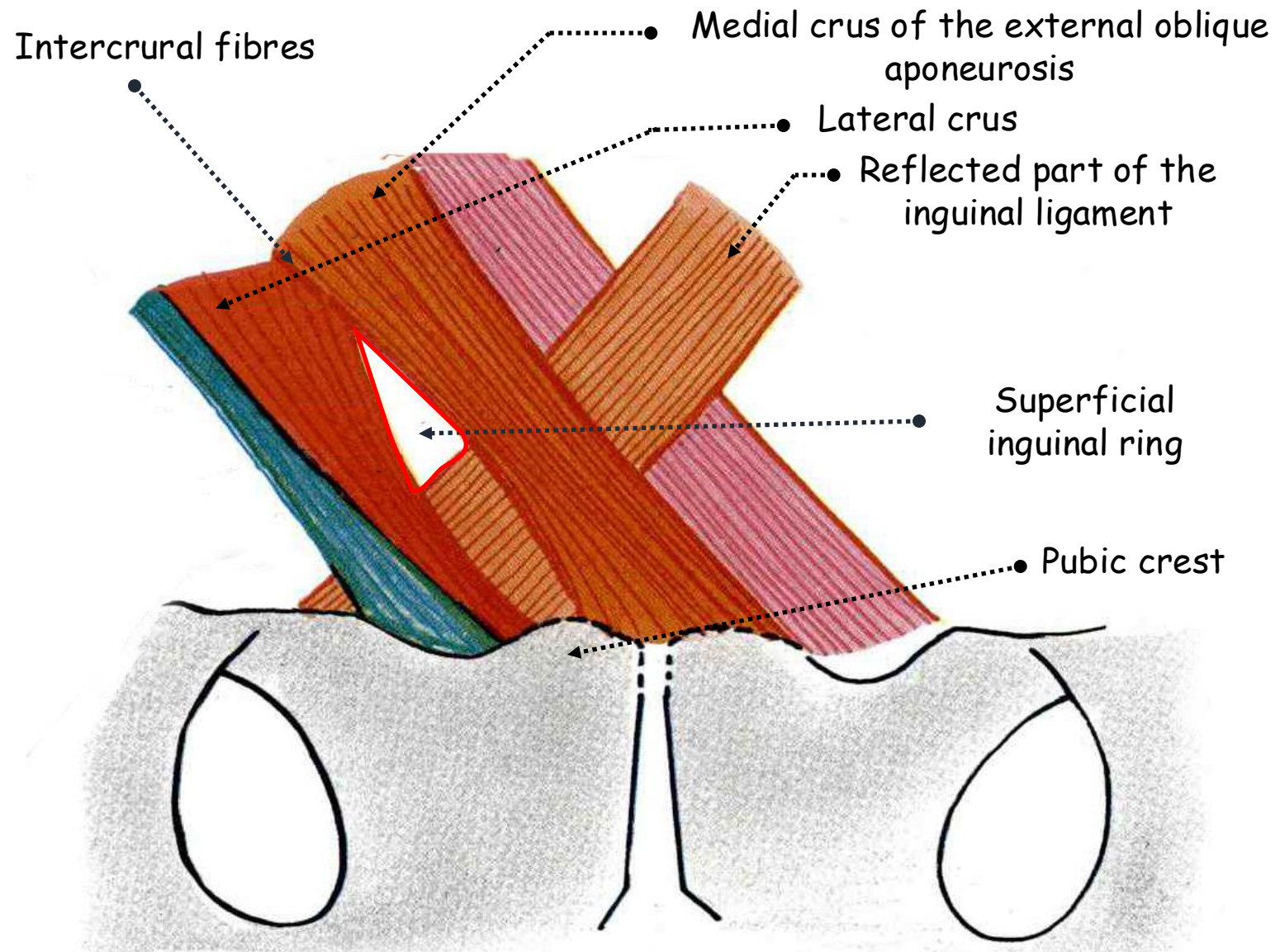
ANTERIOR VIEW OF THE ABDOMINAL WALL IN MEN AND WOMEN
SHOWING THE INGUINAL CANAL

- Commences at the deep inguinal ring
- Lies above the midpoint of the inguinal ligament
- Opening in the transversalis fascia
- Bounded laterally and upwards by the angle between the transversus muscle fibres and the inguinal ligament
- Medial border: transversalis fascia thickened as the sharp interfoveolar ligament projected along the canal like a sleeve from the armhole of a coat as the internal spermatic fascia



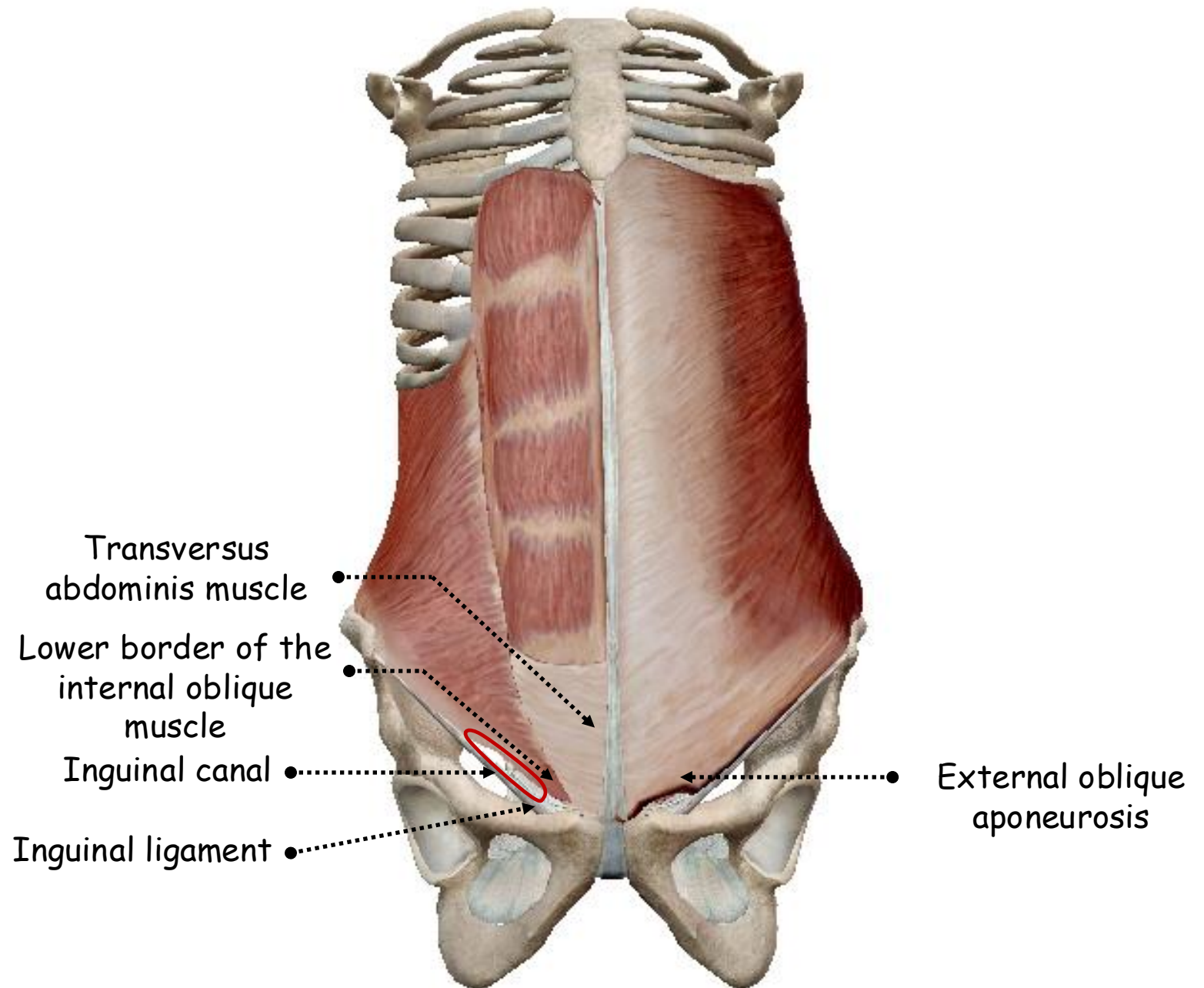
POSTERIOR VIEW OF THE INGUINAL CANAL SHOWING THE DEEP INGUINAL RING

- Ends at the superficial inguinal ring
- V-shaped opening
- Fibres of the external oblique aponeurosis run parallel to the inguinal ligament, their lower border, until they diverge from each other
- Lateral crus: attached to the pubic tubercle
- Medial crus: attached to the pubic crest near the pubic symphysis
- Intervening part of the pubic crest: receives no attachment from the external oblique aponeurosis and forms the base of the ring
- Intercrural fibres: run at right angles across the external oblique aponeurosis at the point of junction of the crura, bind the crura together and serve as a visible landmark
- Floor: reflected part of the inguinal ligament



ANTERIOR VIEW OF THE PELVIS SHOWING THE PELVIC INSERTIONS OF EXTERNAL OBLIQUE MUSCLE

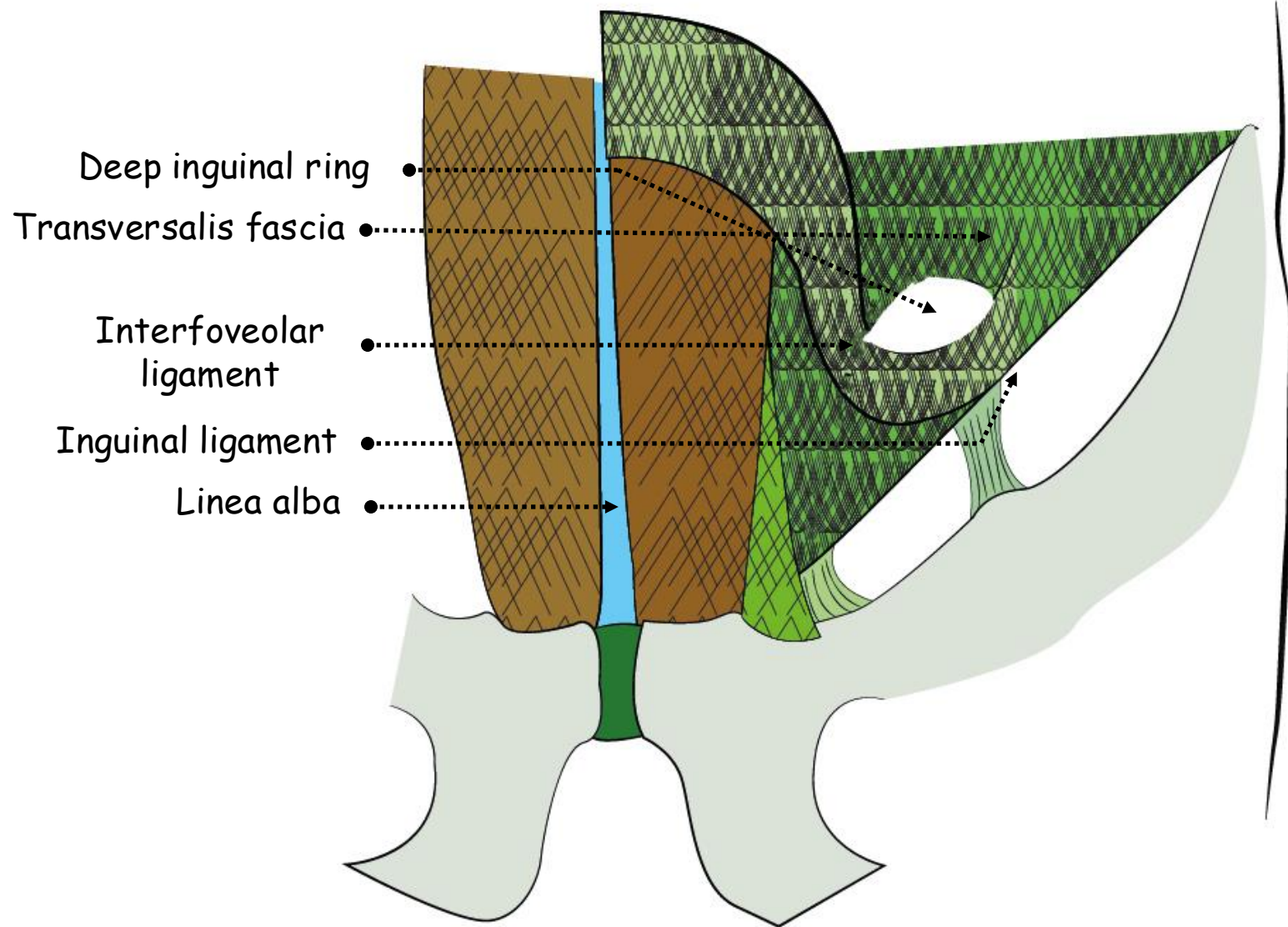
- **Anterior wall:** fibres of the external oblique aponeurosis run parallel to their lower border, the inguinal ligament
- **Floor:**
 - Inguinal ligament joining anterior superior spine and pubic tubercle
 - Lacunar ligament filling the angle between inguinal ligament downwards at the pubic crest and pectineal line with abdominal surface facing forwards and upwards
- **Roof:**
 - Arched lower borders of the internal oblique and transversus abdominis muscles forming the conjoint tendon attached to the pectineal line at right angle to the lacunar ligament backwards



ANTERIOR VIEW OF THE SKELETON OF THE TRUNK SHOWING THE INGUINAL CANAL

• **Posterior wall:**

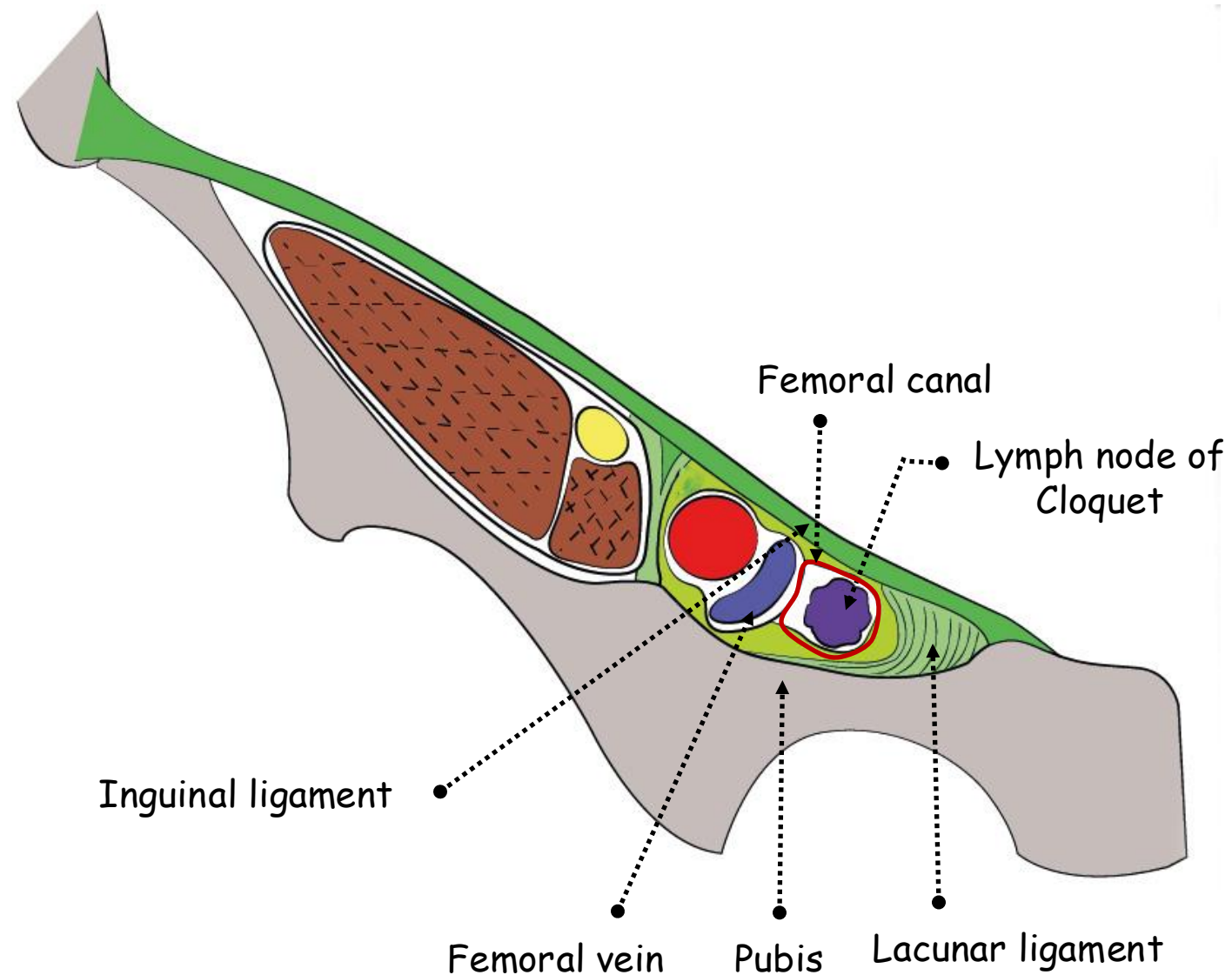
- Conjoint tendon medially
- Transversalis fascia laterally



POSTERIOR VIEW OF THE INGUINAL CANAL SHOWING THE DEEP INGUINAL RING

18. Femoral canal:

- Loose dead space
- Medial to the femoral sheath
- Route by which the efferent lymph vessels from the deep inguinal nodes pass to the abdomen
- Femoral ring:
 - Wide opening of the abdominal end of the femoral canal with 4 boundaries
 - Anterior: medial part of the inguinal ligament
 - Medial: crescentic edge of the lacunar ligament and iliopubic tract
 - Posterior: pectineal ligament
 - Lateral: medial border of the femoral vein
- Contains the lymph node of Cloquet which in the female drains directly the clitoris and in the male the glans penis
- Weakness zone

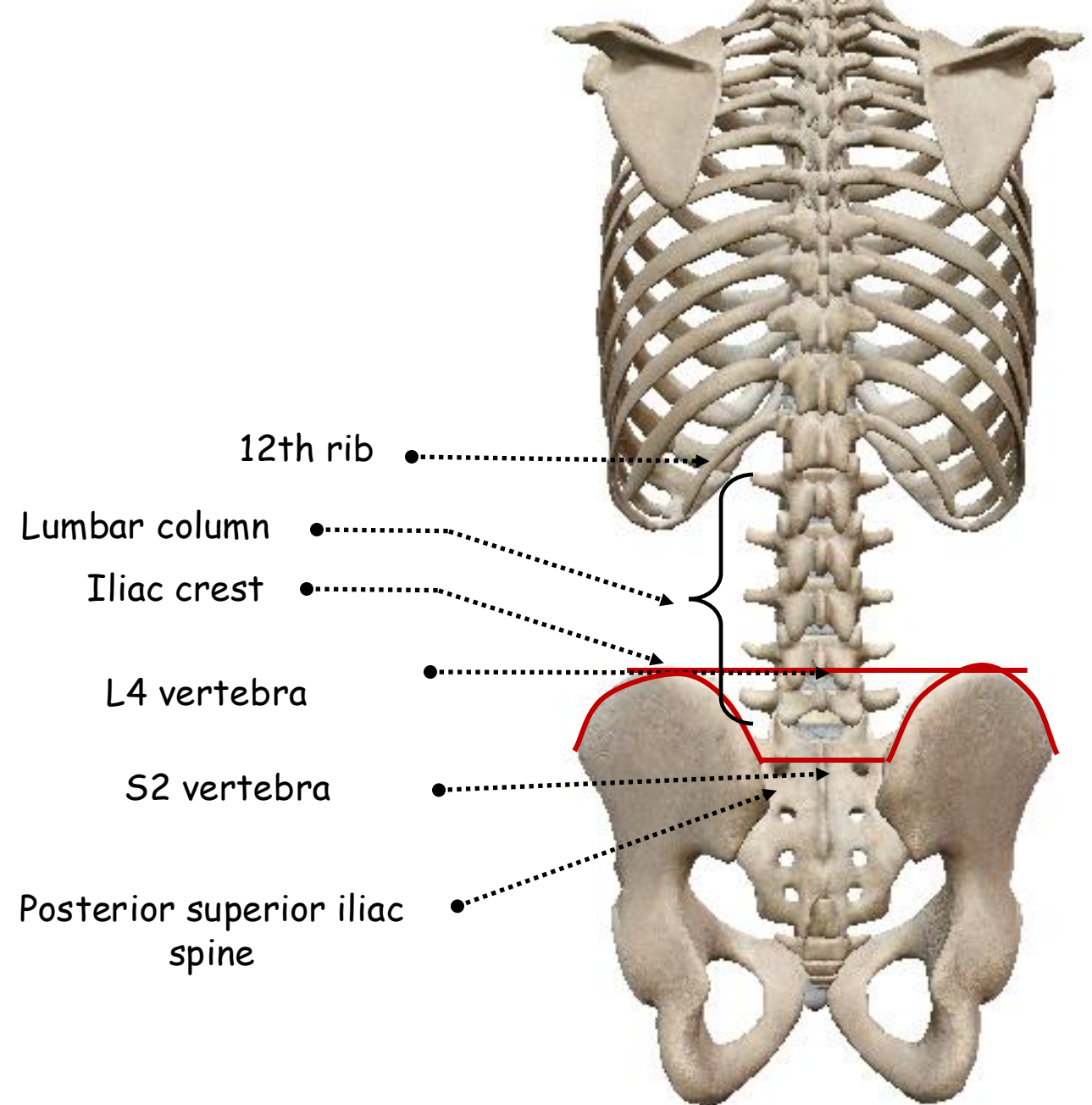


ANTERIOR VIEW OF THE FEMORAL RING

B. POSTERIOR ABDOMINAL WALL

1. Skeleton of posterior abdominal wall:

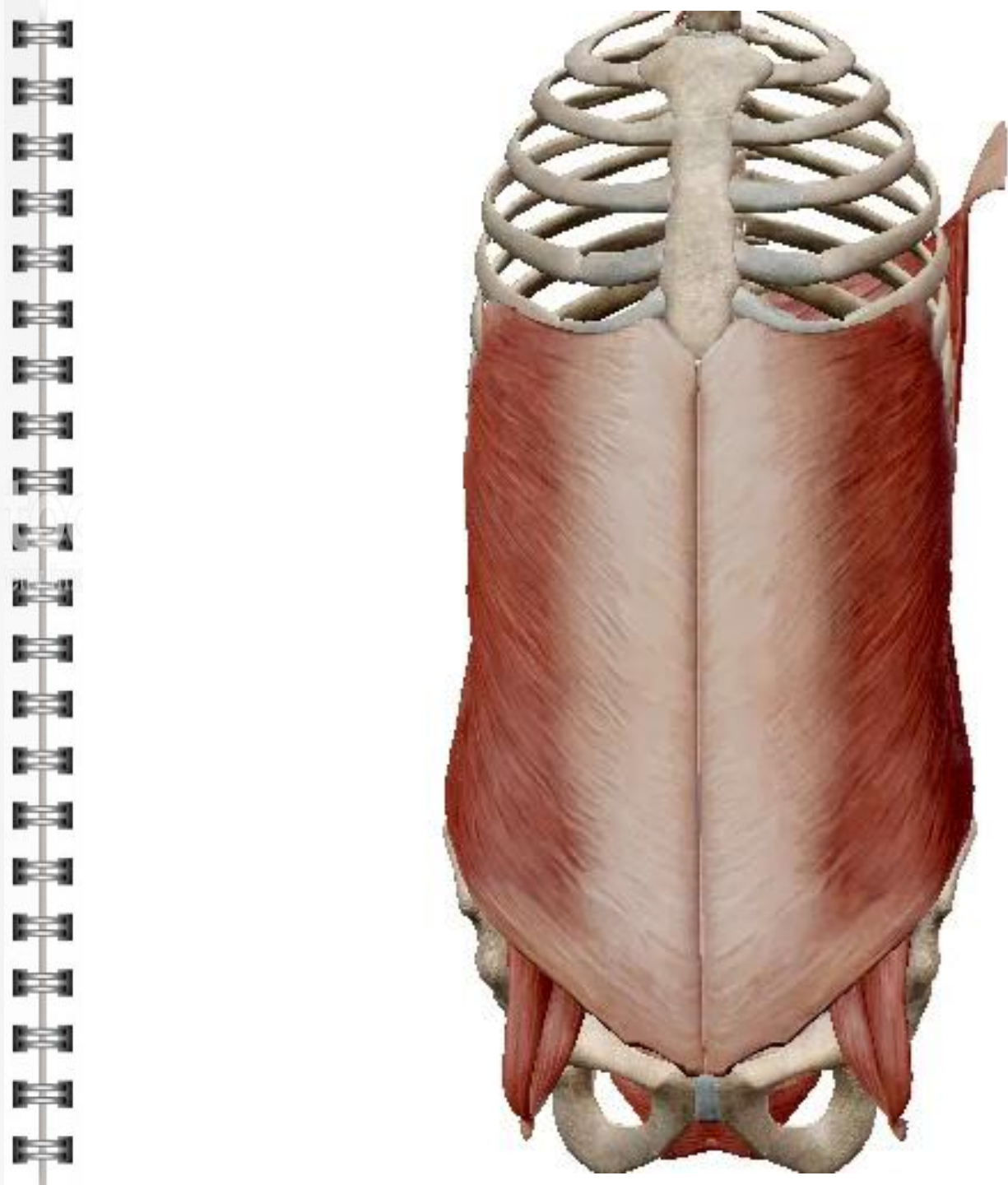
- Upwards: 12th ribs
- Backwards: vertebral column from T12 to L5 vertebrae
- Downwards: margin that lies between posterior superior iliac spines passing by S2 vertebra and the iliac crests on each side towards L4 vertebra



POSTERIOR VIEW OF THE SKELETON OF THE ABDOMINAL WALL


2. Posterior abdominal muscles and aponeuroses:

- Erector spinae mass:
 - Superficial layer of vertebral column muscles
 - From inside to outside
 - Spinalis muscle
 - Longissimus muscle
 - Iliocostalis muscle
- Outer layer of posterior thoracic muscles:
 - From depth to surface
 - Serratus posterior inferior
 - Latissimus dorsi muscle
- Proper muscles of the posterior abdominal wall:
 - From back to front
 - Quadratus lumborum muscle
 - Psoas major muscle
 - Iliacus muscle
- Crura of diaphragm
- Lumbar fascia



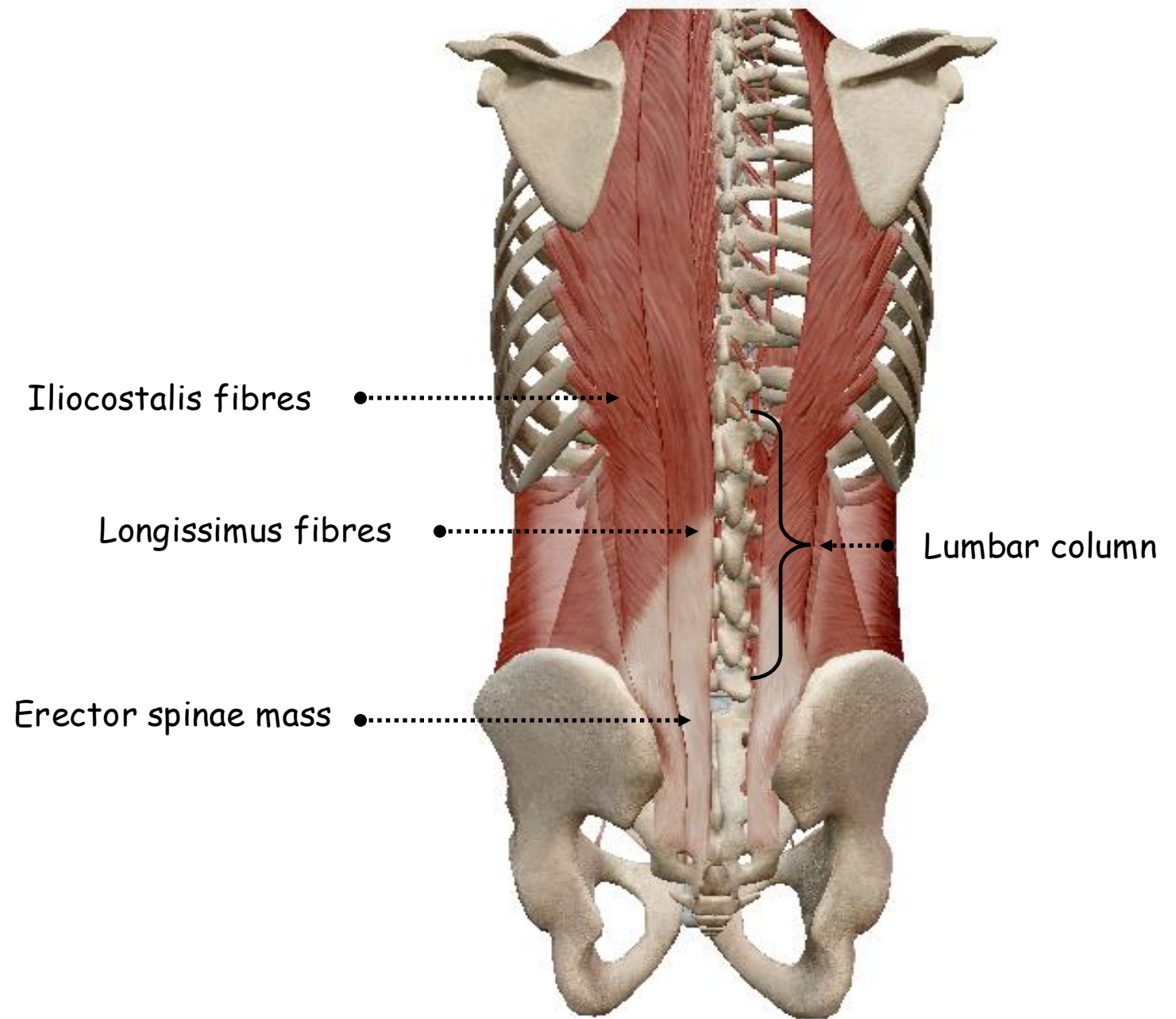
3. Skin and subcutaneous tissue:

- Skin: *variable thickness*
- Superficial subcutaneous tissue



4. Erector spinae mass:

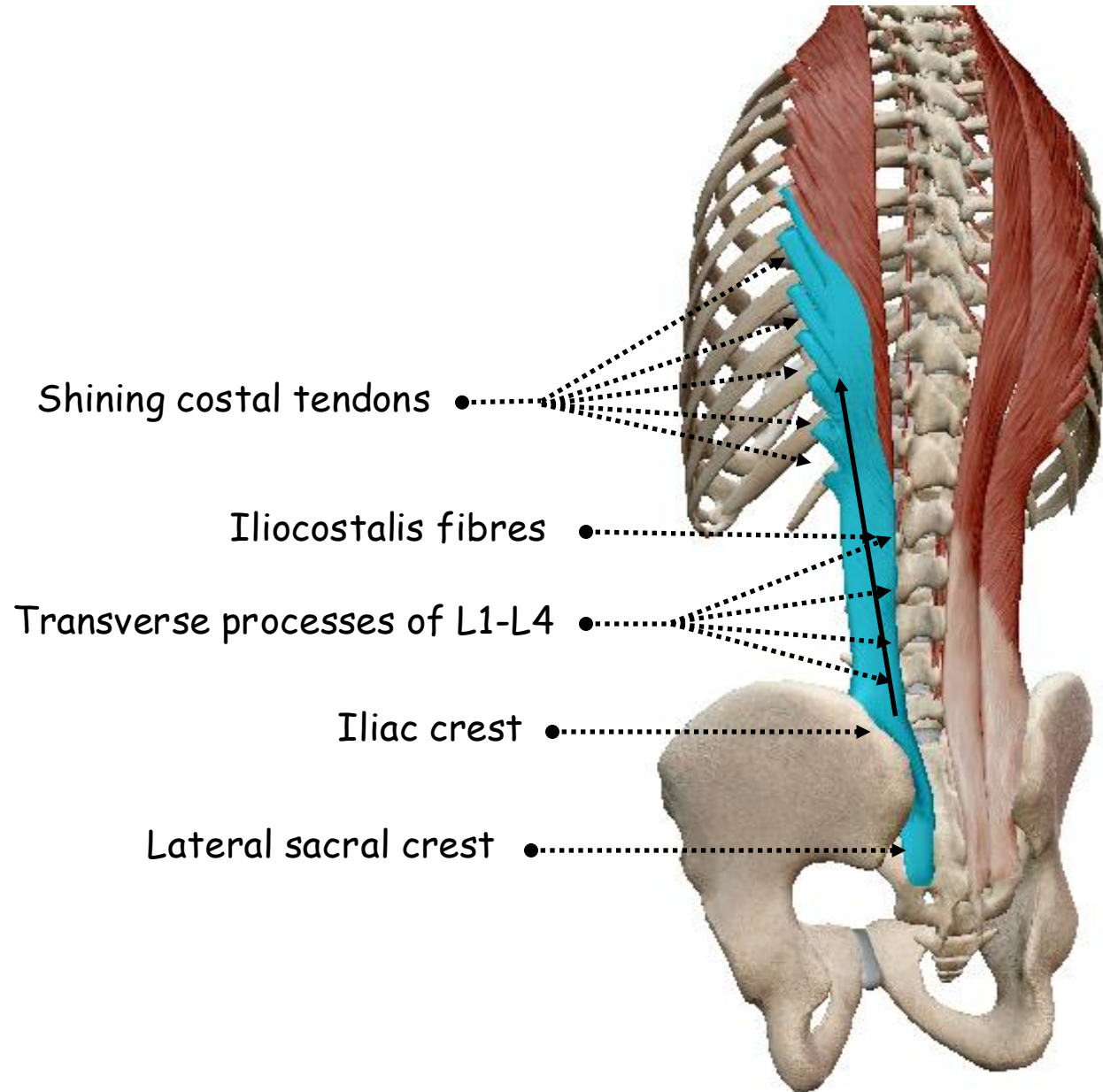
- Most powerful muscle group of the vertebral column
- Commences deep to the lumbar fascia on the back of the sacrum and the inner side of the iliac crest
- Consists of large numbers of muscle and tendon bundles
- Form a thick mass of fibres diverges upwards and divides into two main bundles
- Iliocostalis laterally and longissimus medially



POSTERIOR VIEW OF THE SKELETON OF THE TRUNK
SHOWING THE ERECTOR SPINAE MASS

5. Iliocostalis fibres:

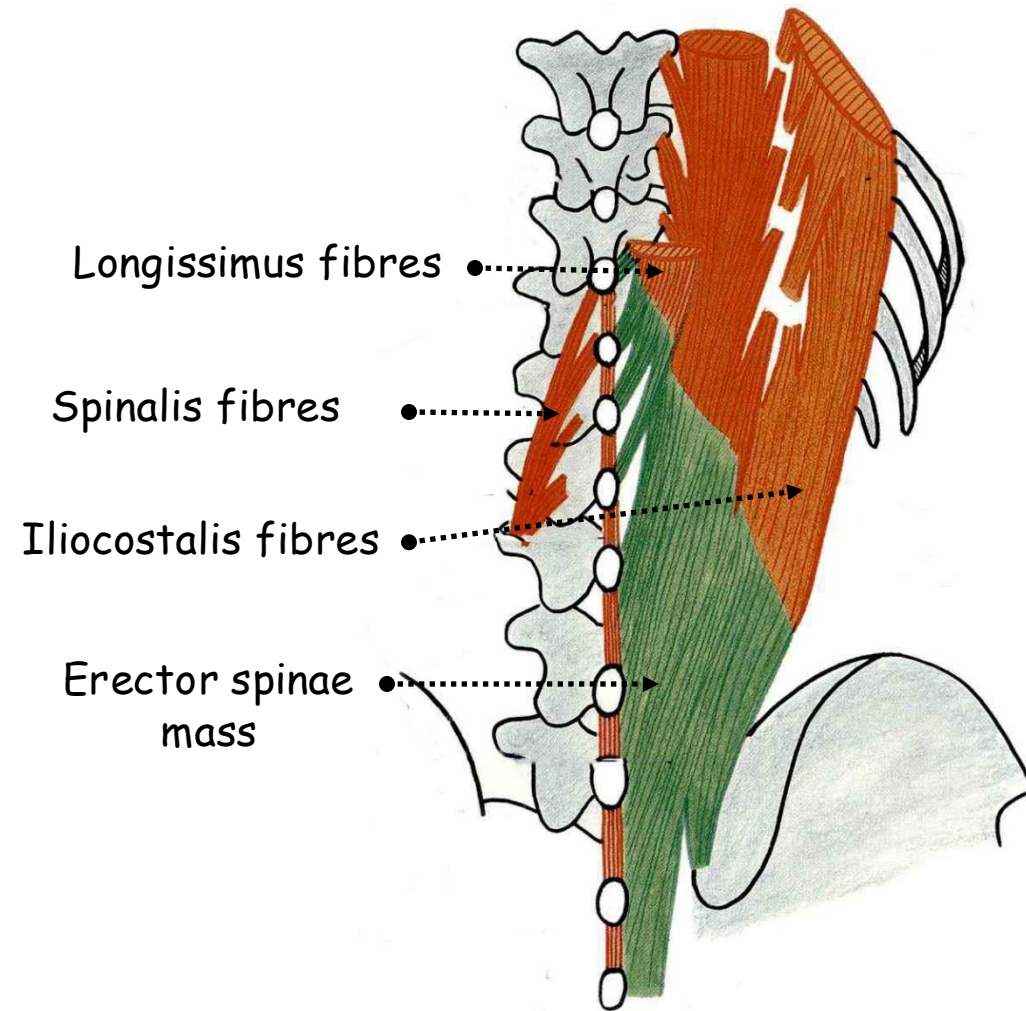
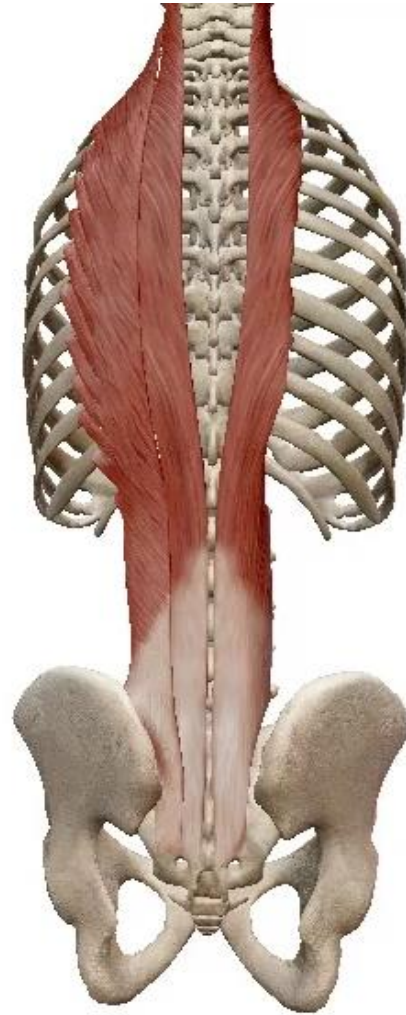
- **Shining tendons into the angles of the lower six ribs**
- From these attachments new muscle bundles arise and each runs up to be attached to the angle of the six ribs above
- From there further fibres run up to reach the transverse processes of the lower four cervical vertebrae



POSTERIOR VIEW OF THE SKELETON OF THE TRUNK
SHOWING THE ERECTOR SPINAE MASS

6. Longissimus fibres:

- More medial
- Inserted into the gutter between transverse processes and ribs
- Replaced by new fibres on the medial side that pass up to the transverse processes of the lower cervical vertebrae
- From these insertions new bundles arise and pass upwards into the mastoid process deep to splenius capitis
- Overlies the lateral border of semispinalis capitis and is covered over by splenius



POSTERIOR VIEW OF THE SKELETON OF THE TRUNK SHOWING THE ERECTOR SPINAE MASS

7. Spinalis fibres:

- Most medial part of erector spinae
- Less important part of erector spinae
- Fibres run alongside the spinous processes and are small and often indefinite, usually blending with semispinalis

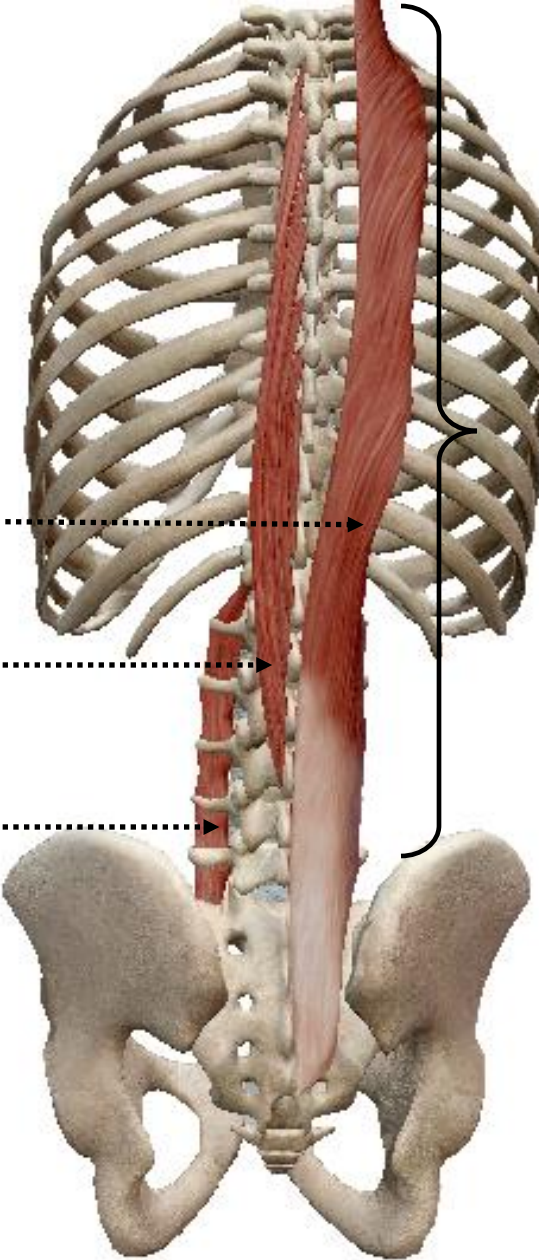
Longissimus fibres

Spinalis fibres

Intertransversales fibres

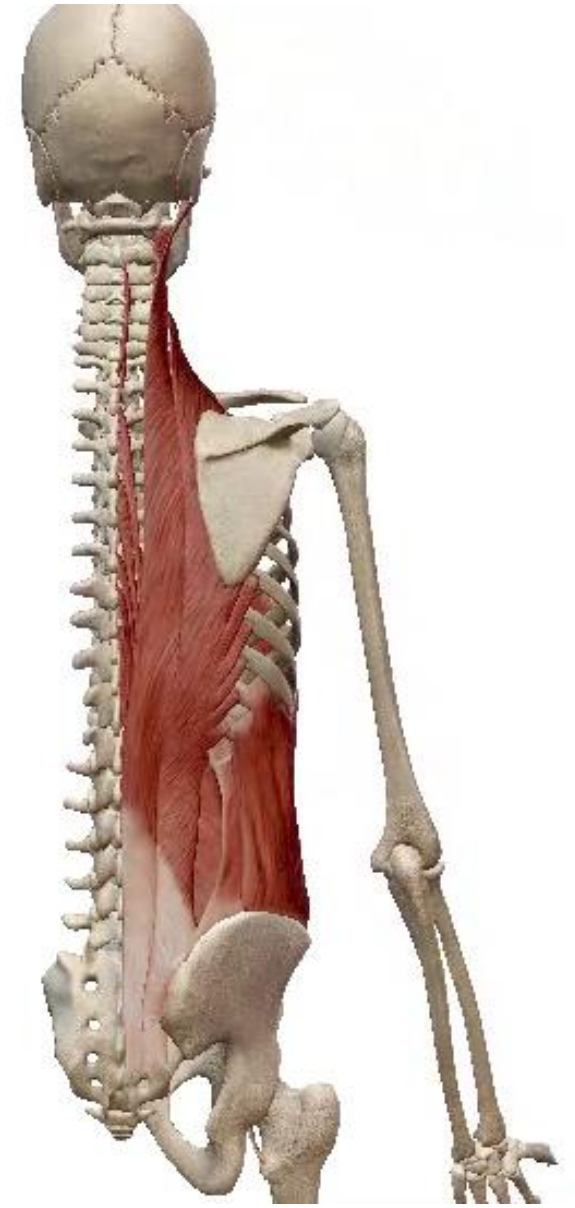
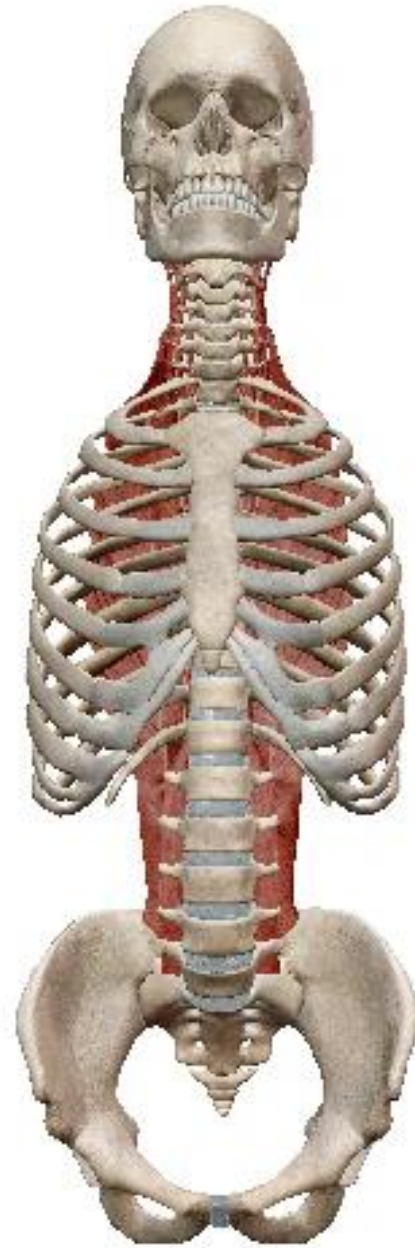
Dorsal and lumbar vertebral columns

POSTERIOR VIEW OF THE SKELETON OF THE TRUNK SHOWING THE SPINALIS FIBRES



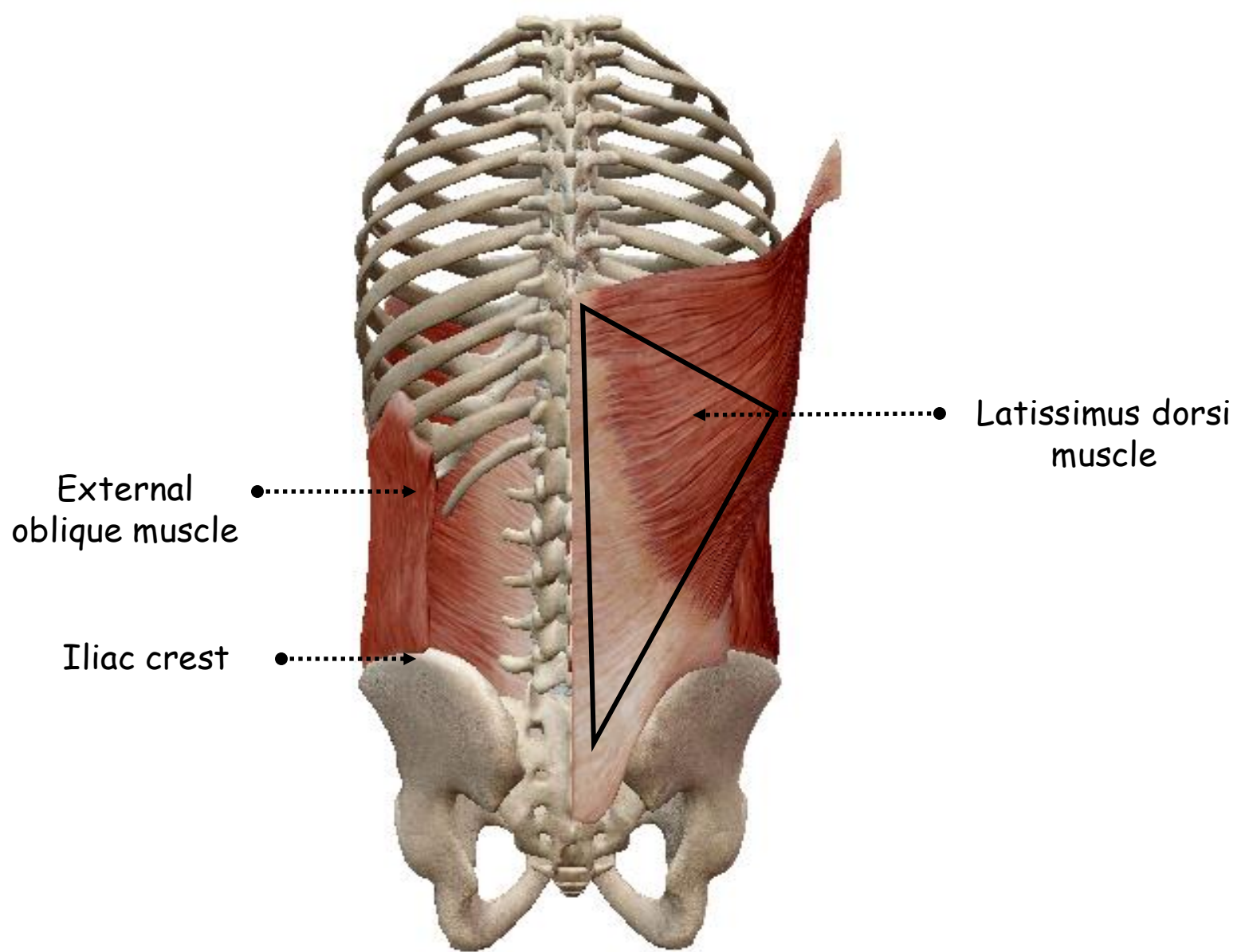
8. Action of the erector spinae mass:

- Extensors of the vertebral column
- Ipsilateral lateral flexors of the vertebral column



9. Latissimus dorsi muscle:

- Flat sheet of muscle covering such a large area of the back covered by the lower triangular part of trapezius
- Triangular with medial base and lateral apex
- **Very wide** origin and **very narrow** insertion



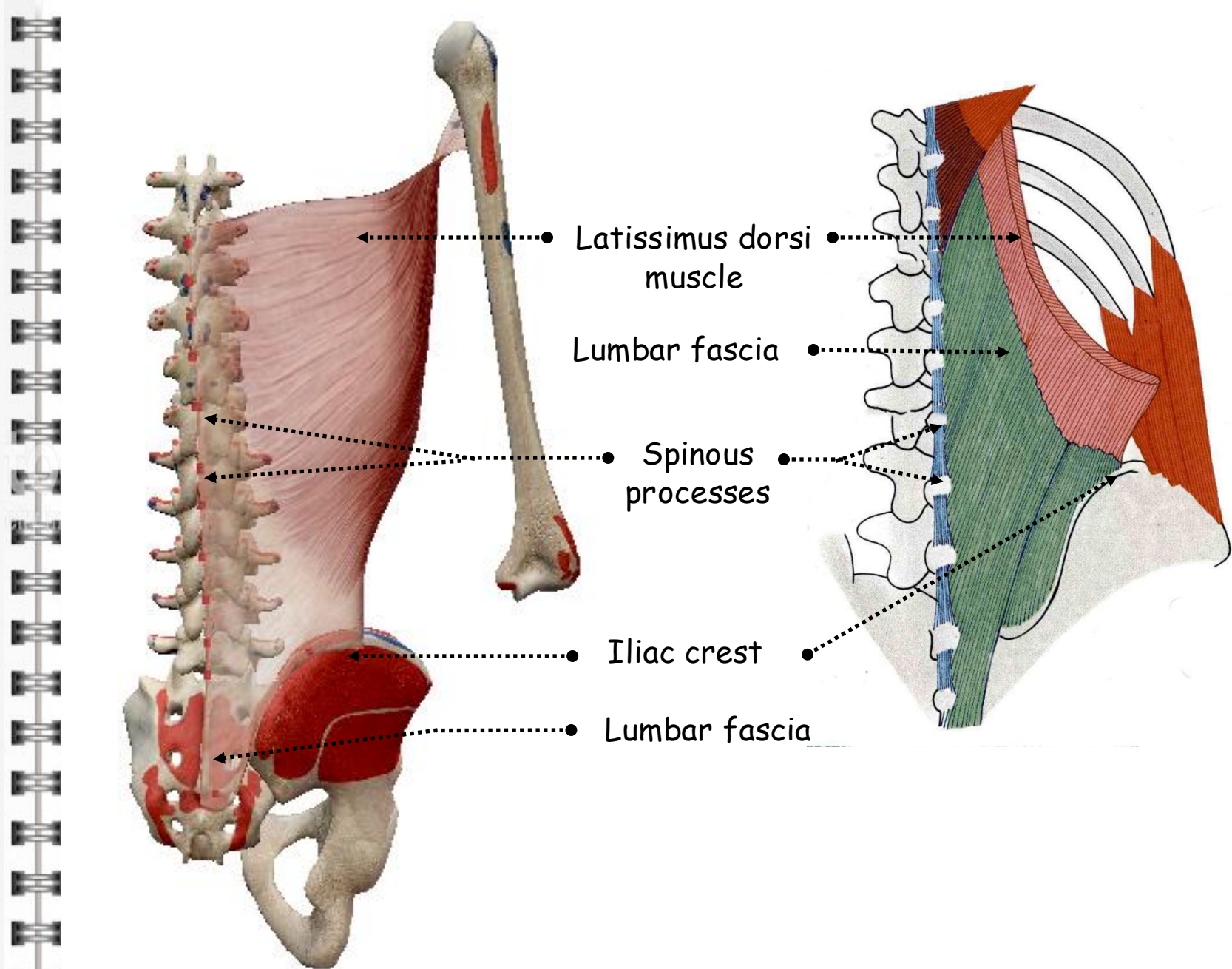
POSTERIOR VIEW OF THE SKELETON OF THE TRUNK SHOWING THE LATISSIMUS DORSI MUSCLE

• **Origin:**

-Commences above, at the spine of T7 vertebra and extends downwards along the spinous processes and supraspinous ligaments of all the lumbar and sacral vertebrae

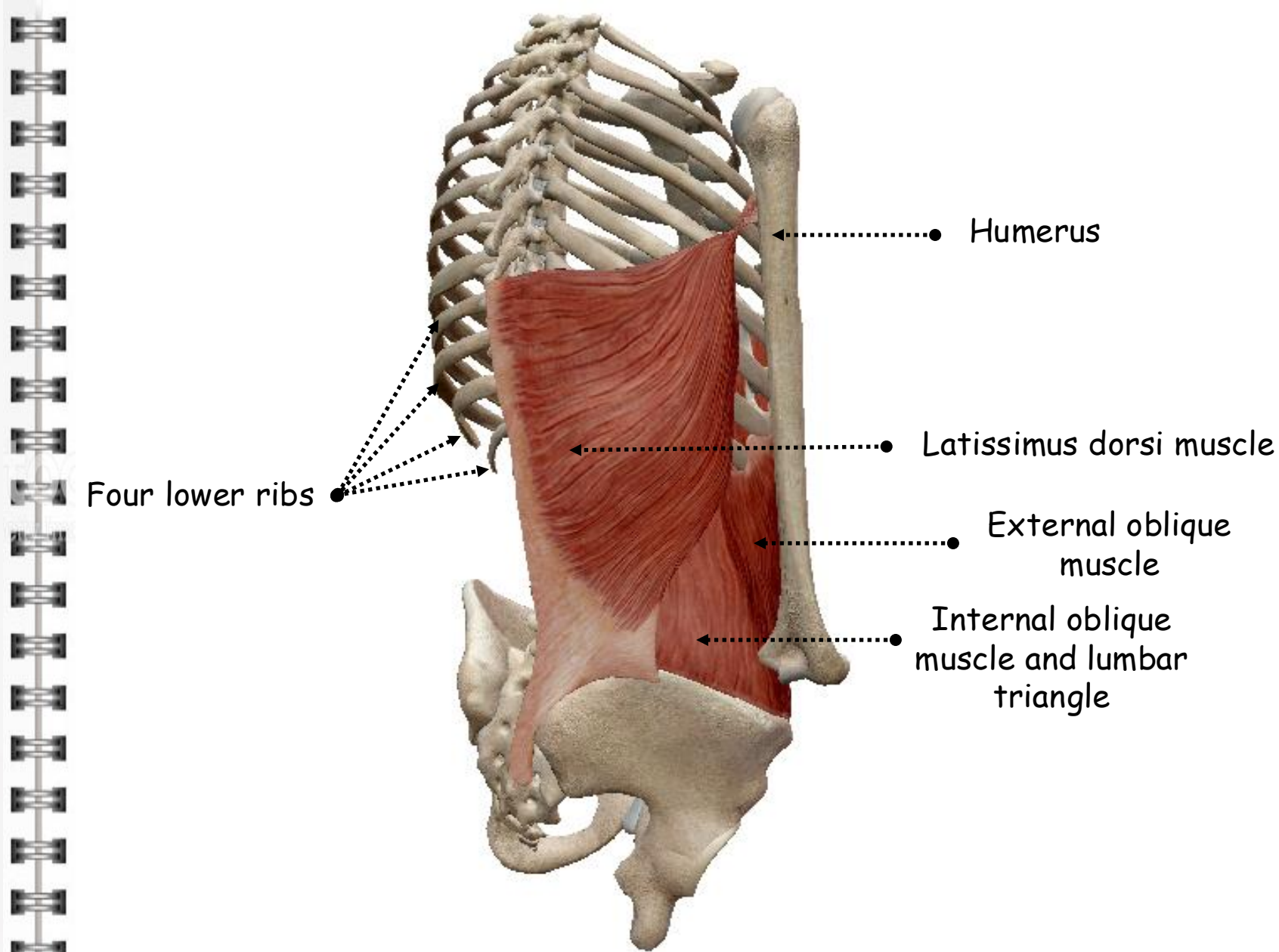
-Fleshy in the thoracic portion and aponeurotic in the lumbar and sacral fusing with the posterior layer of the lumbar fascia

-Central ridge on the posterior part of the crest of the ilium and posterior third of the outer lip of the iliac crest more laterally



POSTERIOR VIEW OF THE SKELETON OF THE TRUNK SHOWING THE LATISSIMUS DORSI MUSCLE

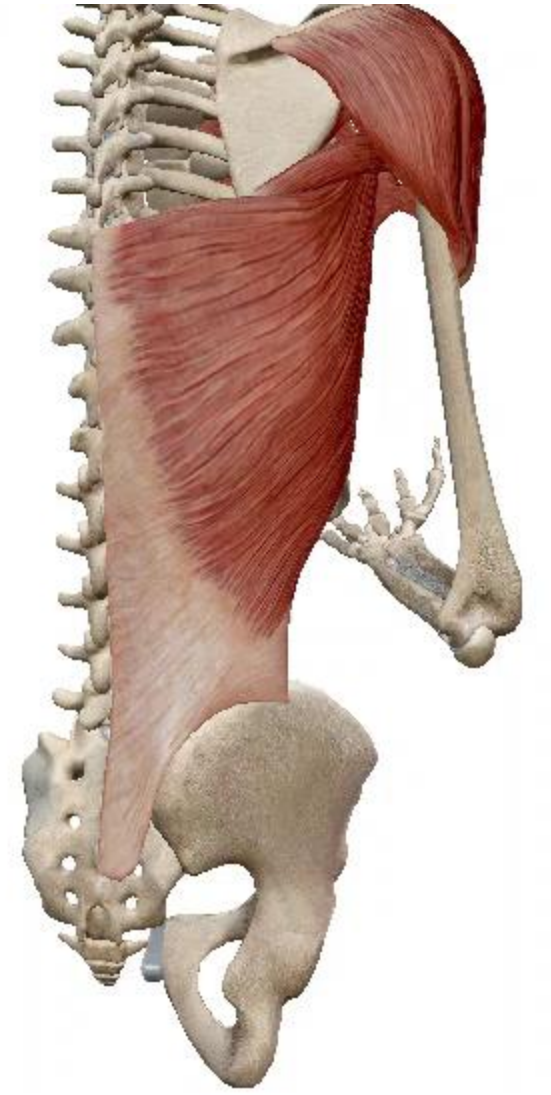
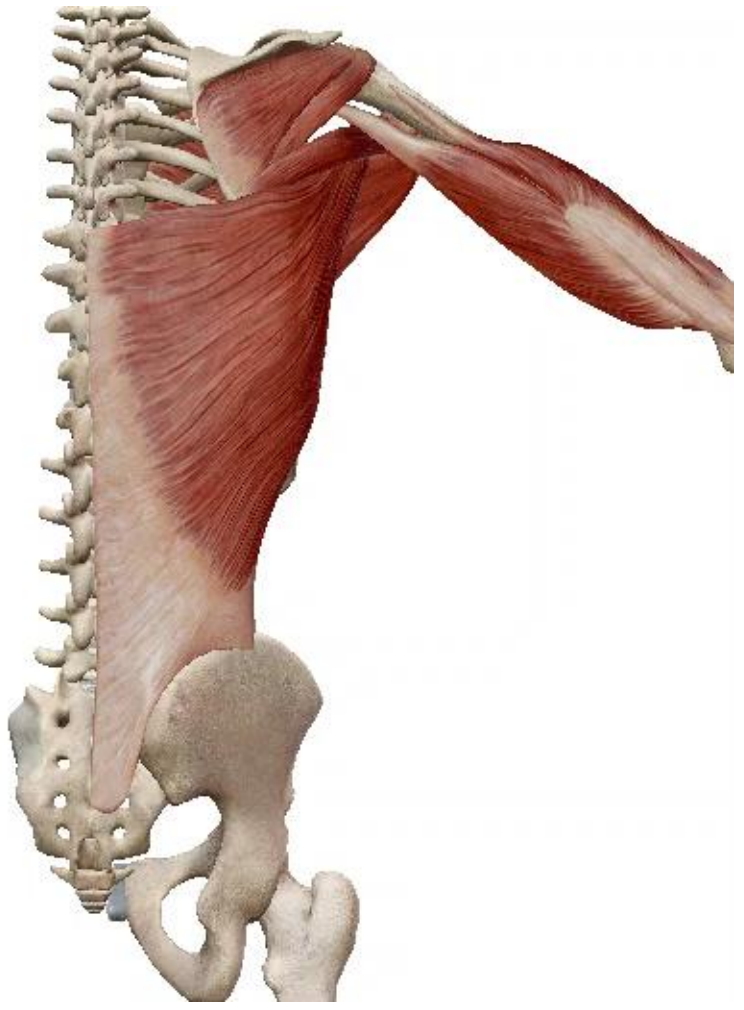
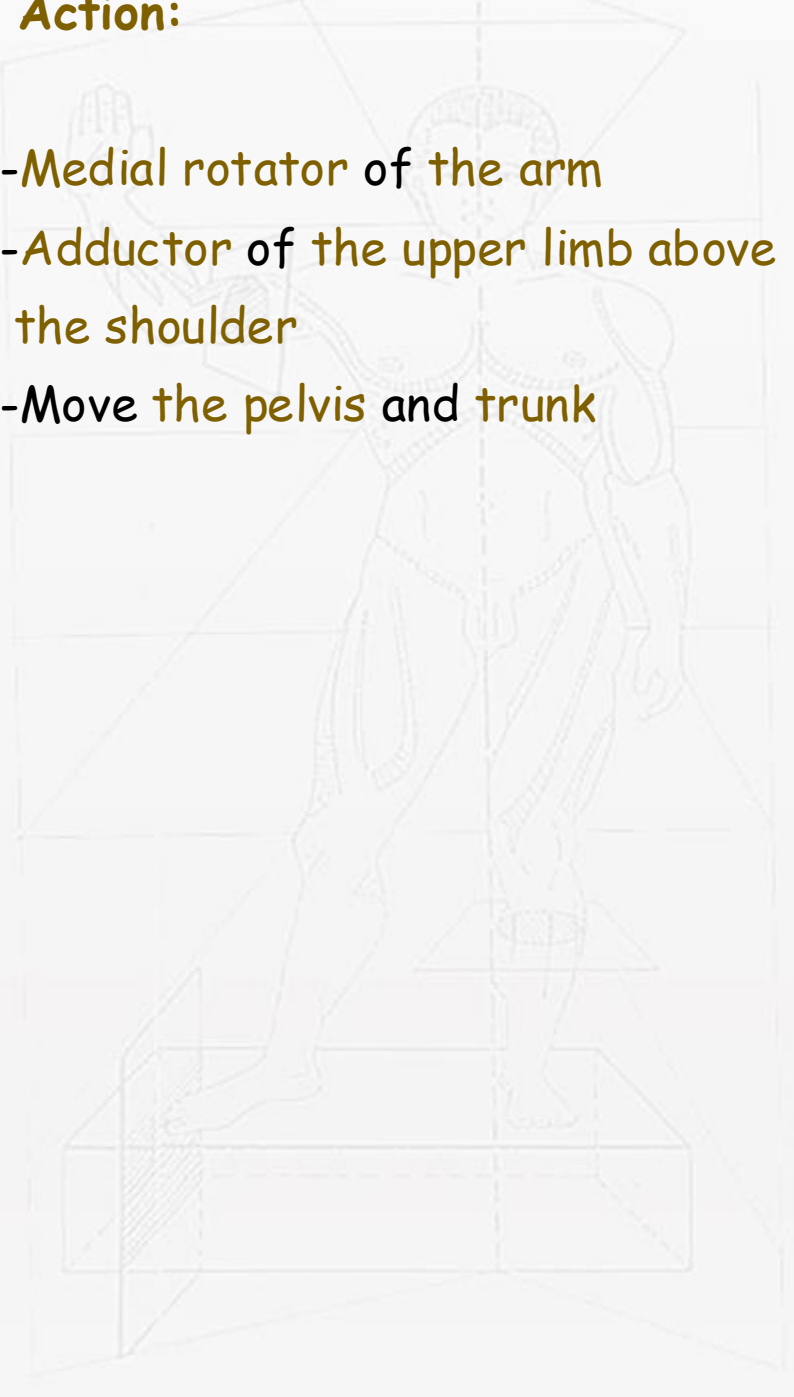
- **Upper border:** runs horizontally and is covered by the lower triangular part of trapezius and flows over the inferior angle of the scapula, from which a few fibres arise to join the muscle
- **Lateral border:** thicker and more rounded, runs vertically upwards reinforced by four slips from the lowest four ribs, whose fibres of origin interdigitate with those of the external oblique and forms a boundary of the lumbar triangle
- Converges towards the posterior axillary fold forming its lower border
- Sweeps spirally around the lower border of teres major
- **Insertion:** ends by a tendon about 2.5 cm broad inserted into the floor of the intertubercular groove of humerus



POSTERIOR LATERAL VIEW OF THE SKELETON OF THE TRUNK
SHOWING THE LATISSIMUS DORSI MUSCLE

• **Action:**

- Medial rotator of the arm
- Adductor of the upper limb above the shoulder
- Move the pelvis and trunk



10. Serratus posterior inferior:

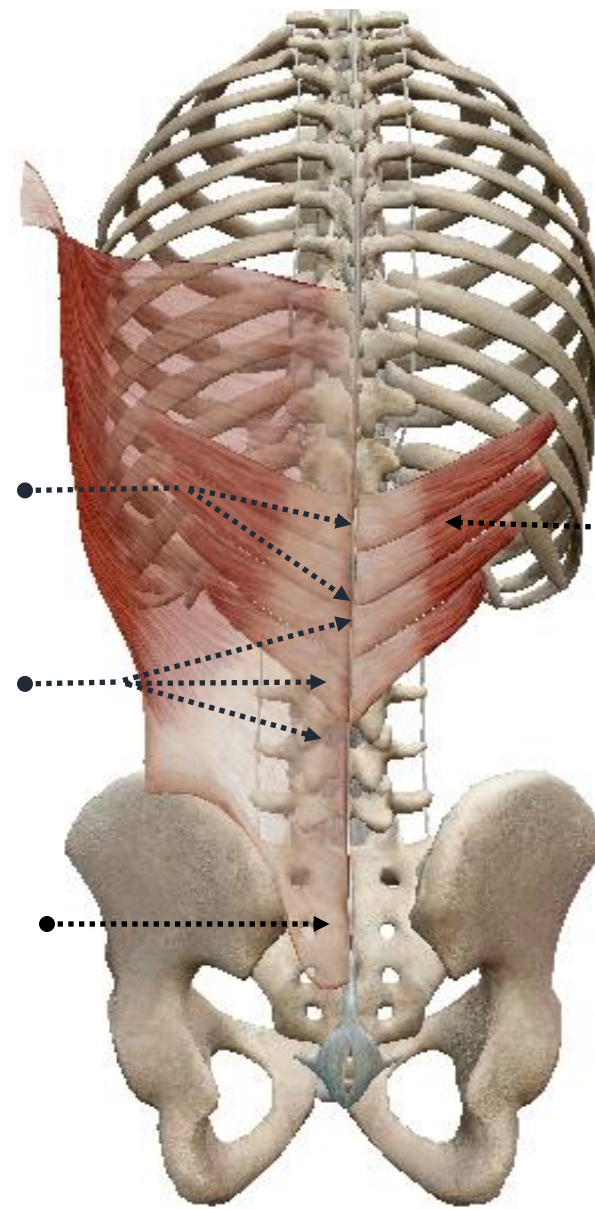
- Arises from the lower two thoracic and the upper two lumbar spinous processes and from the intervening supraspinous ligaments
- Fuses with the posterior lamella of the lumbar fascia deep to latissimus dorsi
- Flat sheet of muscle
- Slopes upwards in contact with the thoracolumbar fascia and is inserted just lateral to the angles of the lowest four ribs



Two lower thoracic vertebrae

Three upper lumbar vertebrae

Lumbar fascia

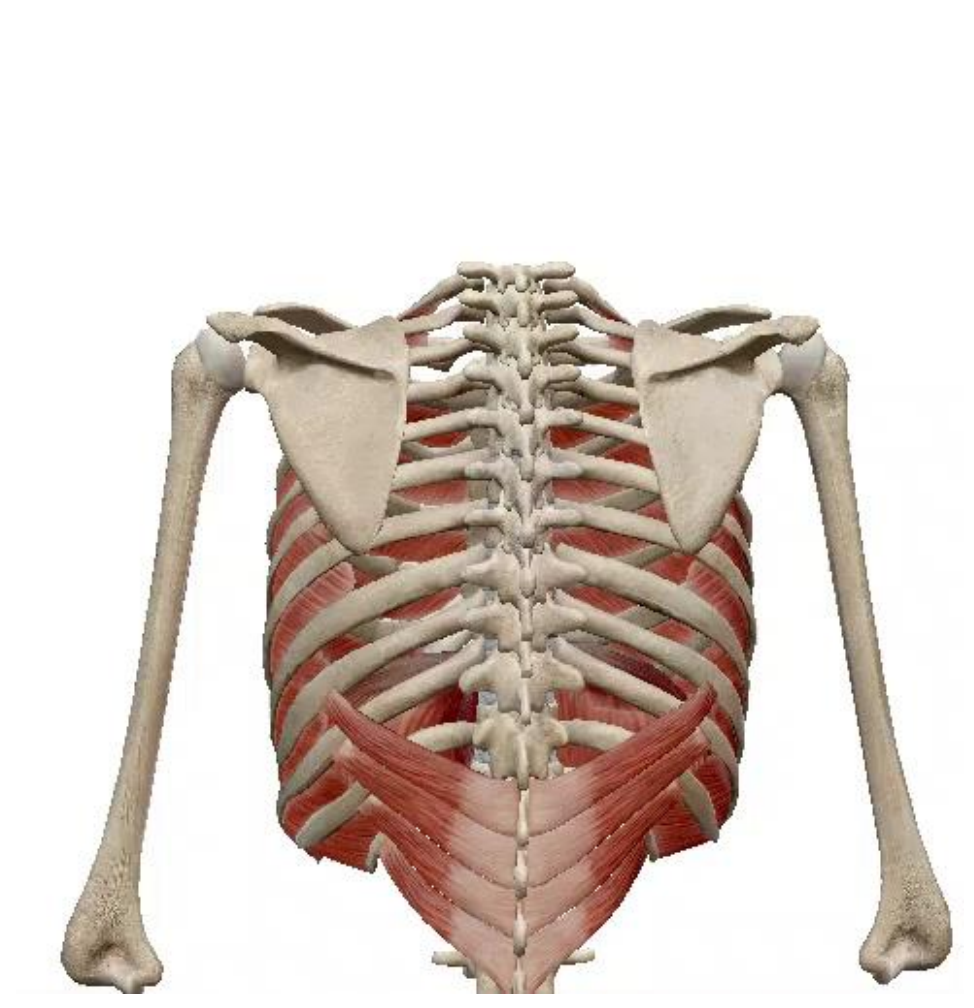


Serratus posterior inferior muscle

POSTERIOR VIEW OF THE SKELETON OF THE TRUNK SHOWING
LATISSIMUS DORSI AND SERRATUS POSTERIOR INFERIOR
MUSCLES

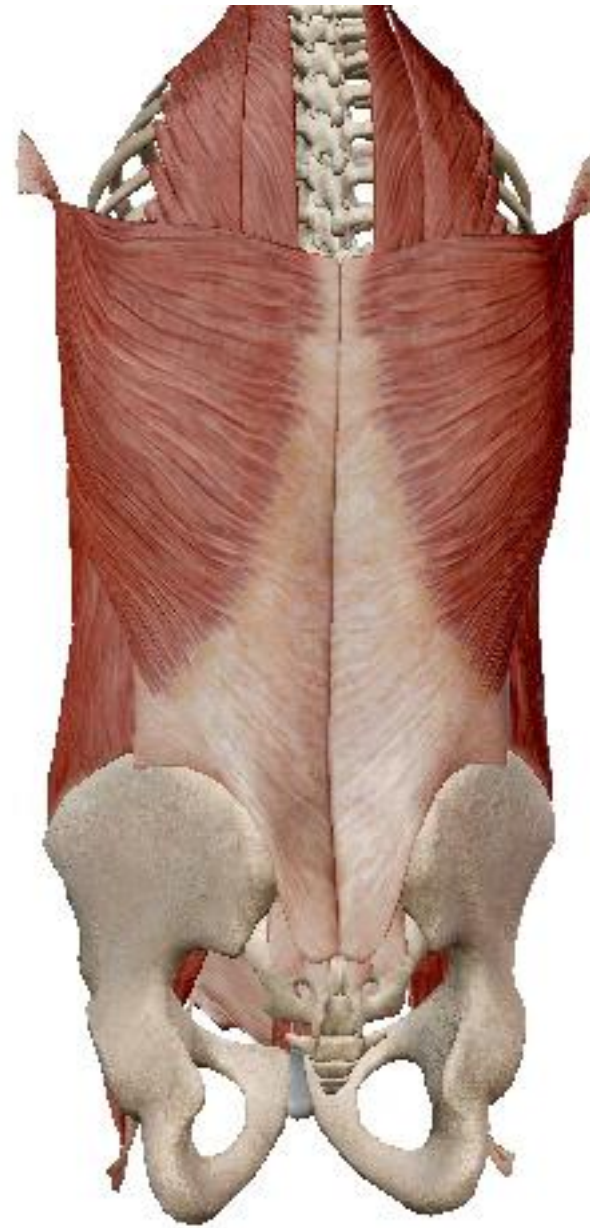• **Action:**

- **Weak** muscle of respiration
- **Depressor** of **lower ribs** during expiration



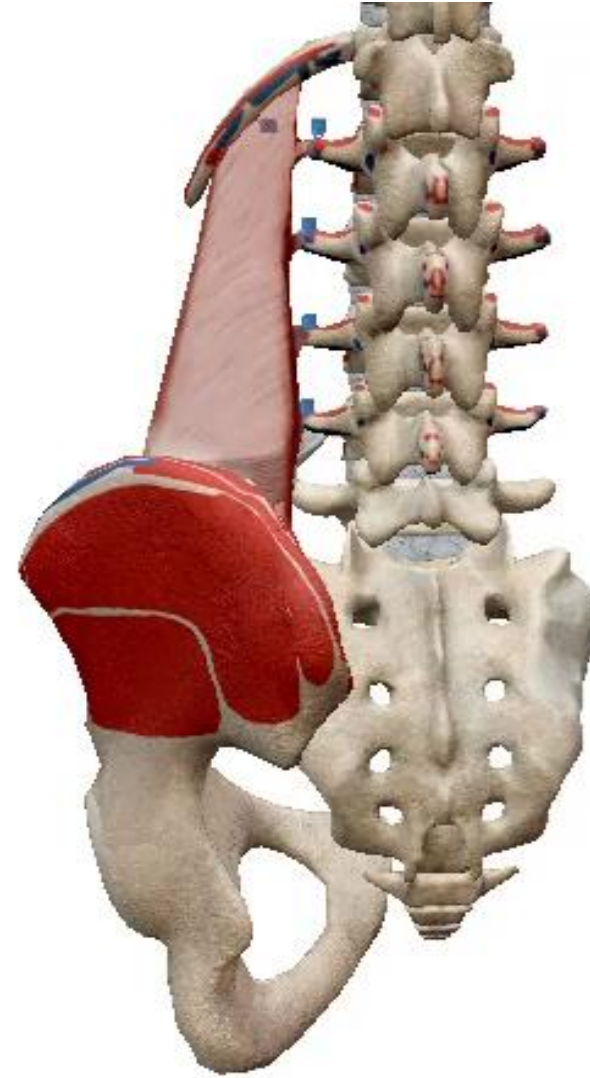11. Proper muscles of the posterior abdominal wall:

- Continuous with the anterior abdominal wall through aponeurosis of transversus abdominis
- Thickened at its upper part forming the lumbocostal triangle
- Fibrous band that crosses from the twelfth rib to the tips of the transverse processes of the first and second lumbar vertebrae
- From back to front
- **Quadratus lumborum** towards the transverse processes
- **Psoas major** in front of the transverse processes
- **Iliacus muscle** in the iliac fossa

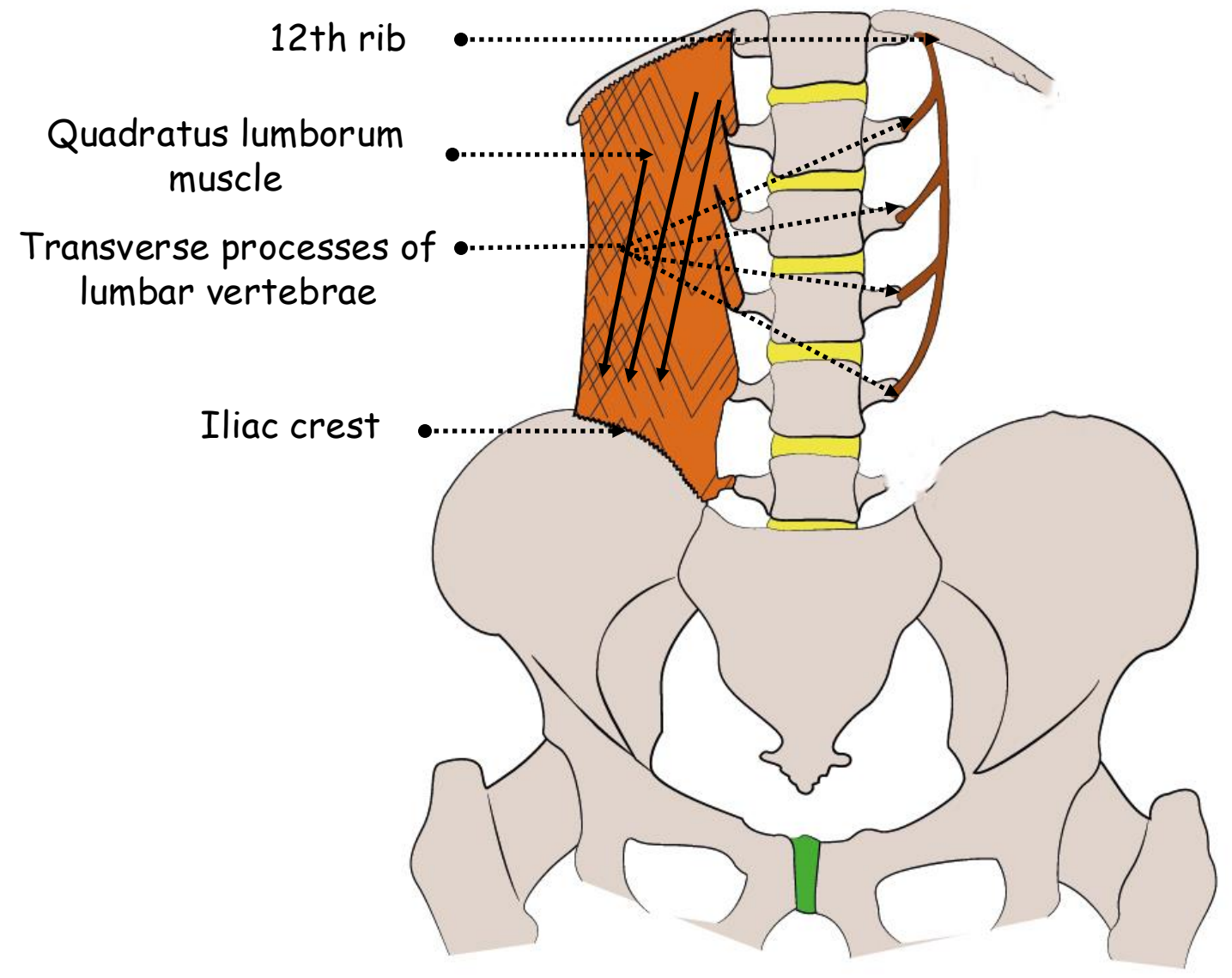


12. Quadratus lumborum muscle:

- Flat sheet lying deep in the paravertebral gutter edge to edge with psoas medially and transversus abdominis laterally
- Lies in the anterior compartment of the lumbar fascia
- Arises from the stout transverse process of L5 vertebra, from the strong iliolumbar ligament and from a short length of the adjoining iliac crest
- Passes upwards to the transverse processes of the upper four lumbar vertebrae and to the inferior border of the medial half of the twelfth rib




- **Lateral border:** slopes upwards and medially and so crosses the lateral border of iliocostalis
- **Anterior surface:** covered by the anterior layer of the lumbar fascia which thickening in front passes from the first lumbar transverse process to the outer end of the twelfth rib constitutes the lateral arcuate ligament



ANTERIOR VIEW OF THE SKELETON OF THE POSTERIOR ABDOMINAL WALL SHOWING QUADRATUS LUMBORUM MUSCLE

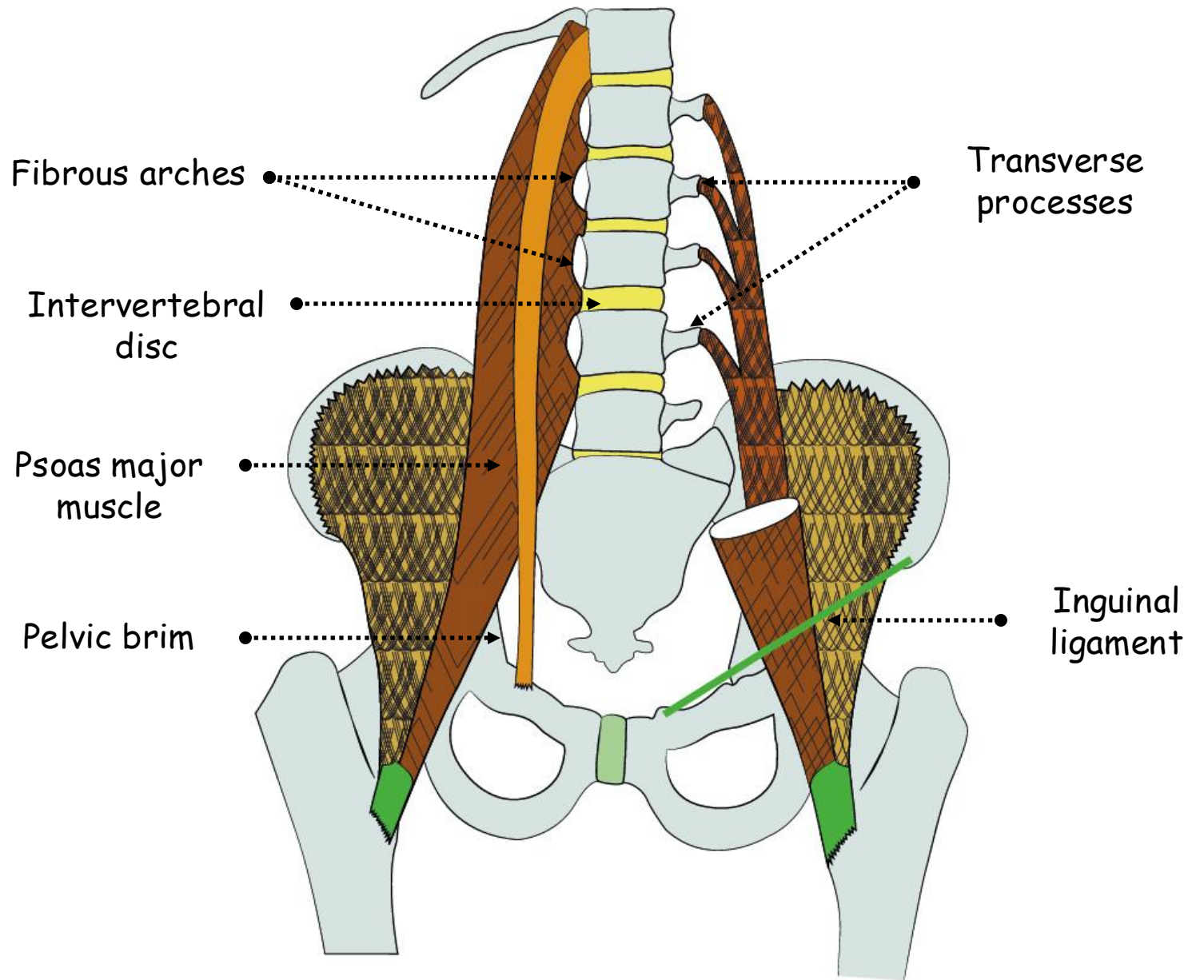
- **Action:**

- Depressor of the 12th rib
- Abductor of the lumbar spine



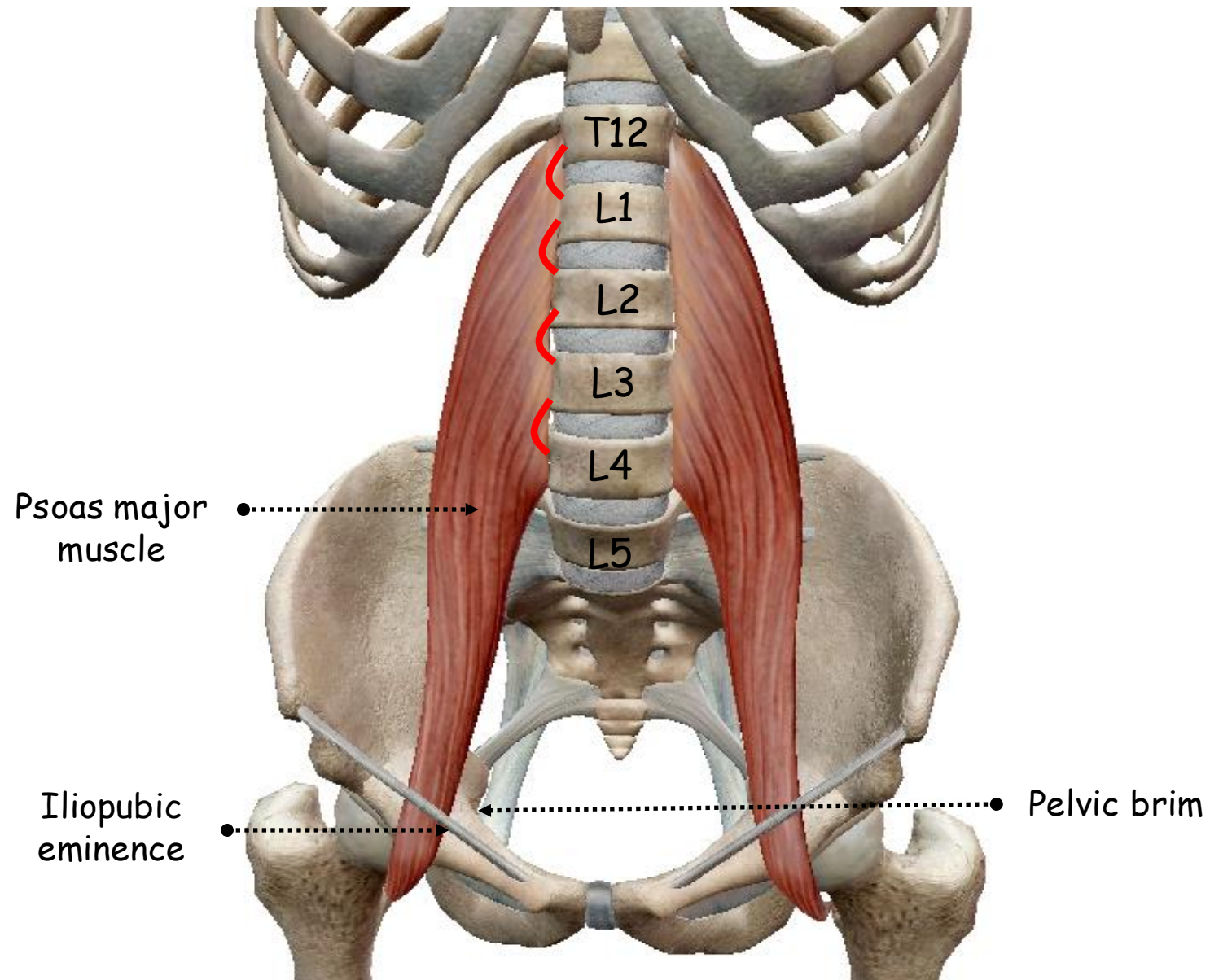
13. Psoas major muscle:

- Lies in the gutter between the bodies and transverse processes of the lumbar vertebrae
- Continuous vertebral attachment: discs above the five lumbar vertebrae, the adjoining parts of the bodies of the vertebrae and fibrous arches that span the concavities of the sides of the upper four vertebral bodies
- Lateral ends of the transverse processes of the lumbar vertebrae
- Passes downwards along the pelvic brim and then beneath the inguinal ligament into the thigh, where its tendon is attached to the lesser trochanter of the femur
- **Lateral border:** straight but oblique running downwards and somewhat laterally



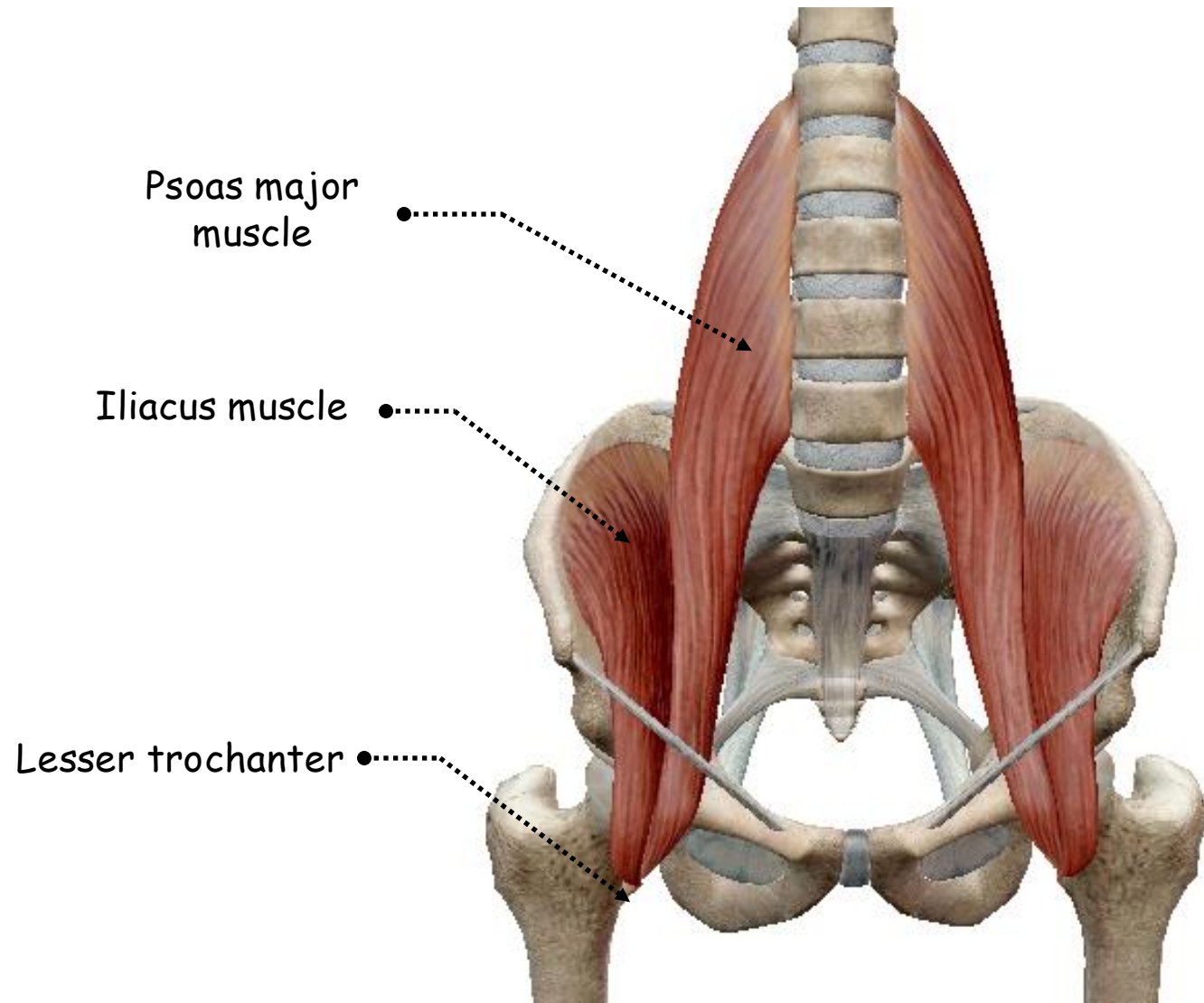
ANTERIOR VIEW OF THE SKELETON OF THE ABDOMEN SHOWING
PSOAS MAJOR MUSCLE

- **Medial border:** slightly curved and just overlaps the pelvic brim
- **Psoas fascia:**
 - Part of the **iliac fascia**
 - Same origin** as the muscle
 - Attached to the **iliopubic eminence** at the margins of the muscle
 - Not part of the lumbar fascia** but the lateral edge blends with the anterior layer of that fascia over quadratus lumborum



ANTERIOR VIEW OF THE SKELETON OF THE ABDOMEN SHOWING PSOAS MAJOR MUSCLE

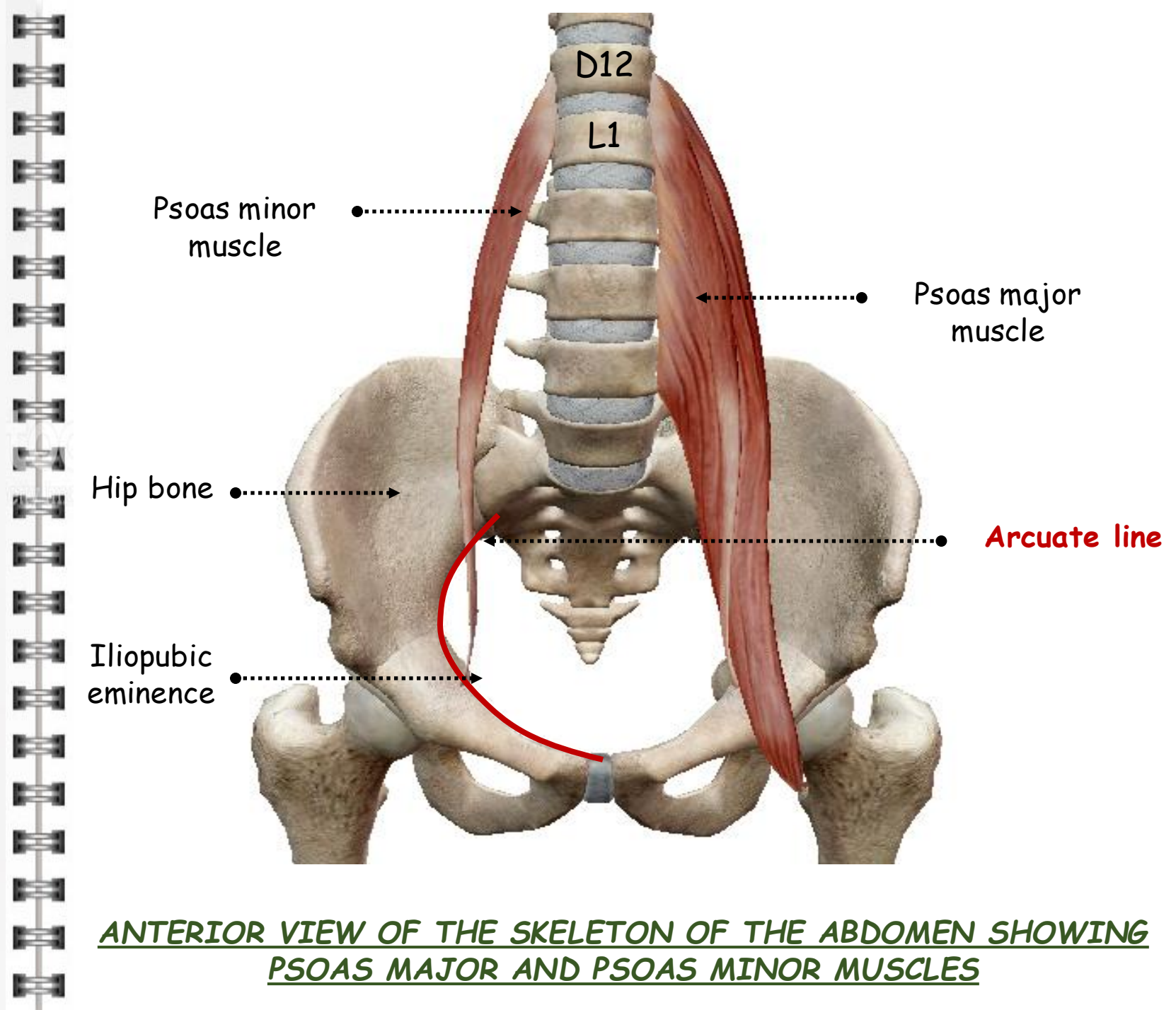
- **Medial arcuate ligament:** thickening of the psoas fascia curving obliquely from the body of L2 vertebra to the transverse process of L1, from which fibres of the diaphragm arise in continuity alongside the crus
- Part of the psoas major above this ligament is in **the thorax**
- Action:
 - Lateral flexor of the vertebral column
 - Lateral rotator of the hip
 - Simultaneous action: flexor of the trunk



ANTERIOR VIEW OF THE SKELETON OF THE ABDOMEN SHOWING
PSOAS MAJOR AND ILIACUS MUSCLES

14. Psoas minor muscle:

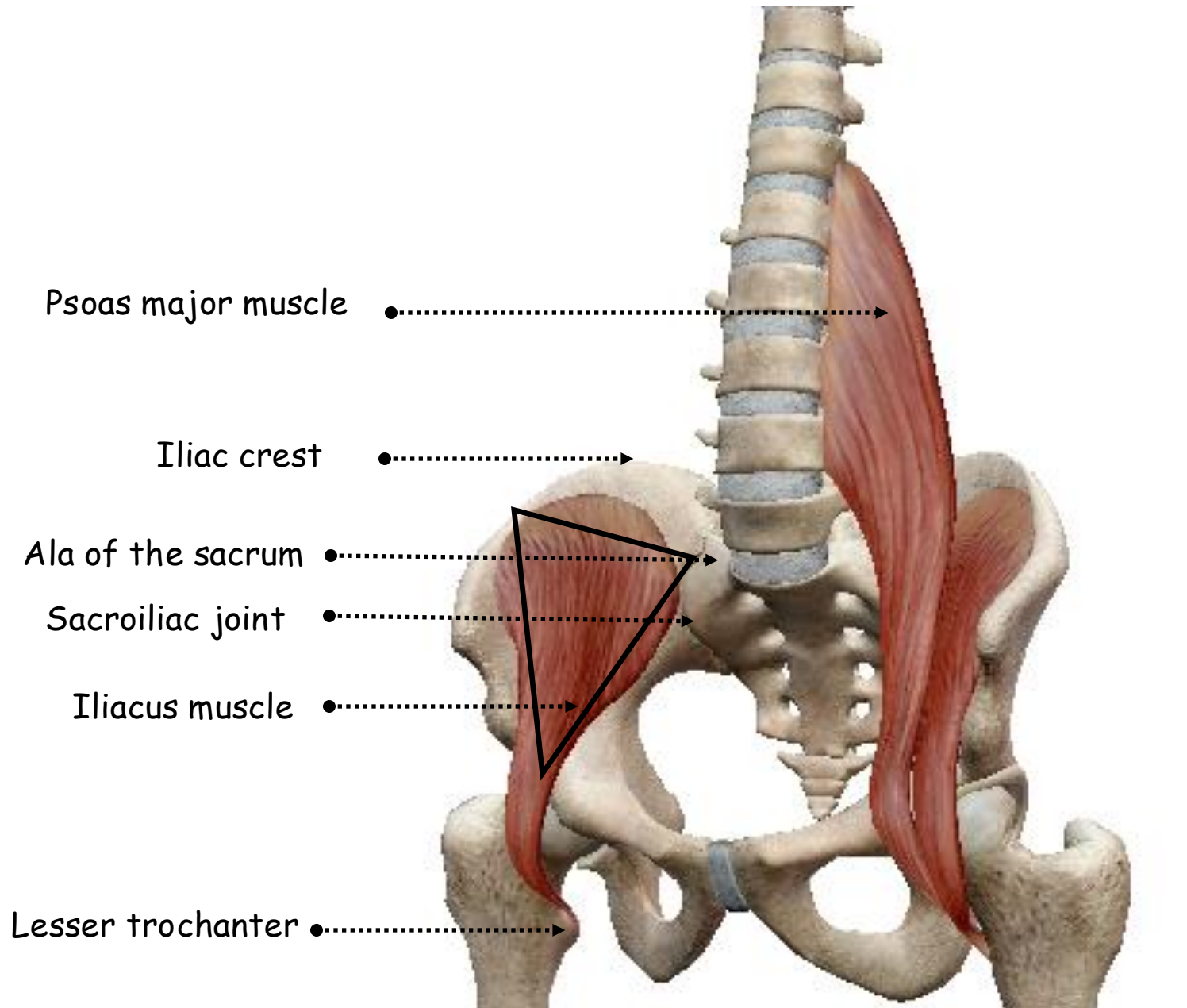
- Present in only **two** out of **every three** individuals
- **Slender** muscle lying on the surface of psoas major
- Arises from **T12** and **L1** vertebrae
- **Long tendon** flattens out to **blend with the psoas fascia** behind the inguinal ligament and thus gains a bony attachment at the **margin of psoas major** to the **arcuate line** and **iliopubic eminence**
- **Action:** weak flexor of the lumbar spine



ANTERIOR VIEW OF THE SKELETON OF THE ABDOMEN SHOWING
PSOAS MAJOR AND PSOAS MINOR MUSCLES

15. Iliacus muscle:

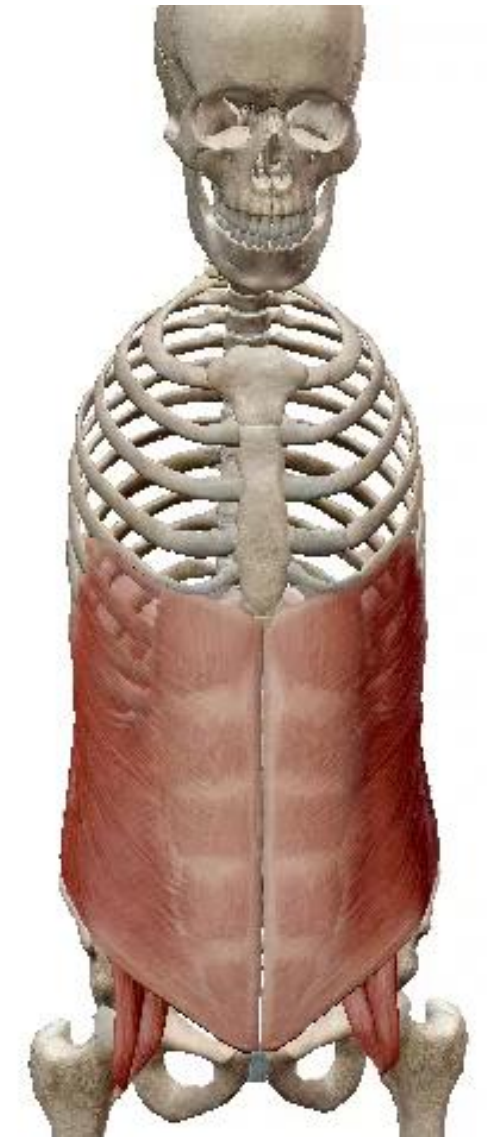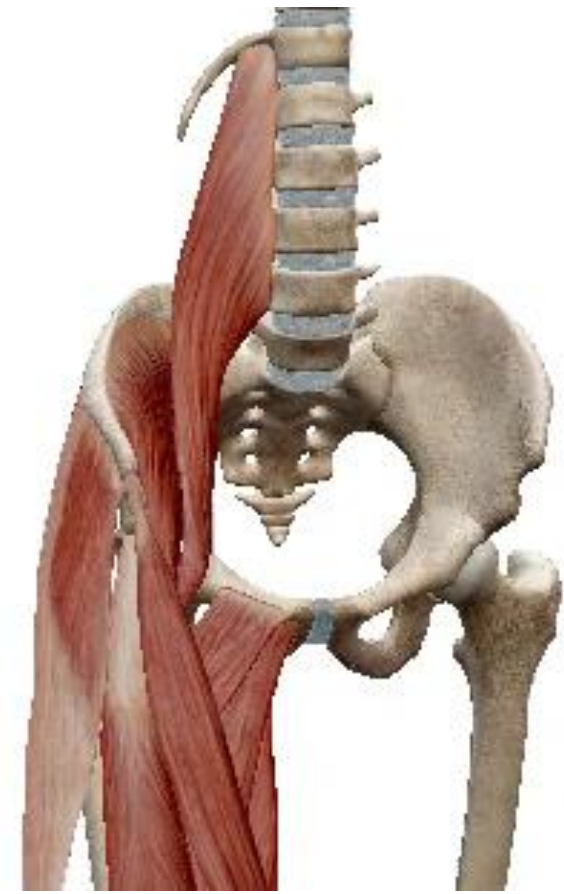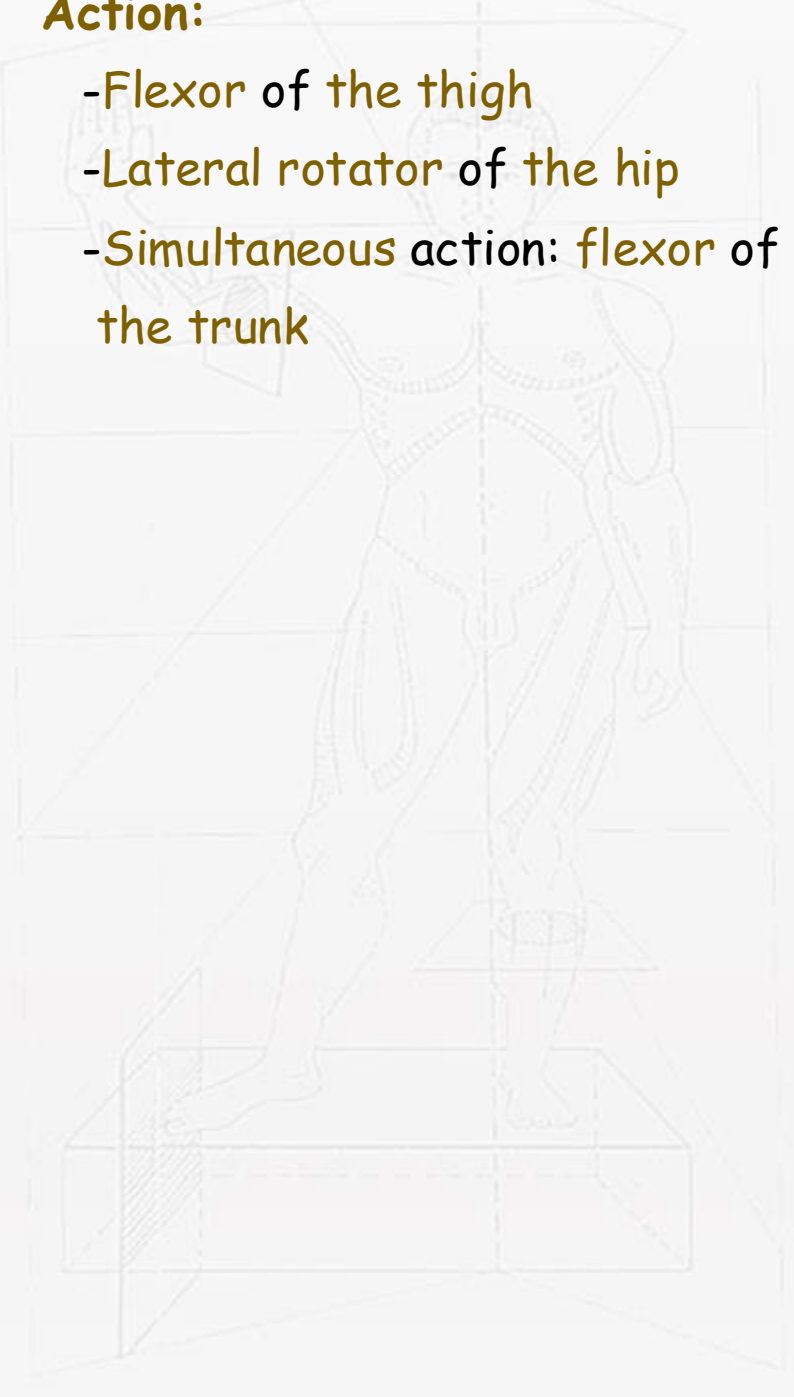- Arises from the hollow of the iliac fossa up to the inner lip of the iliac crest
- Encroaches across the sacroiliac joint to arise also from the anterior sacroiliac ligament overlying the ala of the sacrum
- Triangular
- Converges medially towards the lateral margin of psoas
- Passes out of the iliac fossa beneath the lateral part of the inguinal ligament
- Inserted into the psoas tendon and the adjacent part of the femur below the lesser trochanter



ANTERIOR VIEW OF THE SKELETON OF THE ABDOMEN SHOWING
PSOAS MAJOR AND PSOAS MINOR MUSCLES

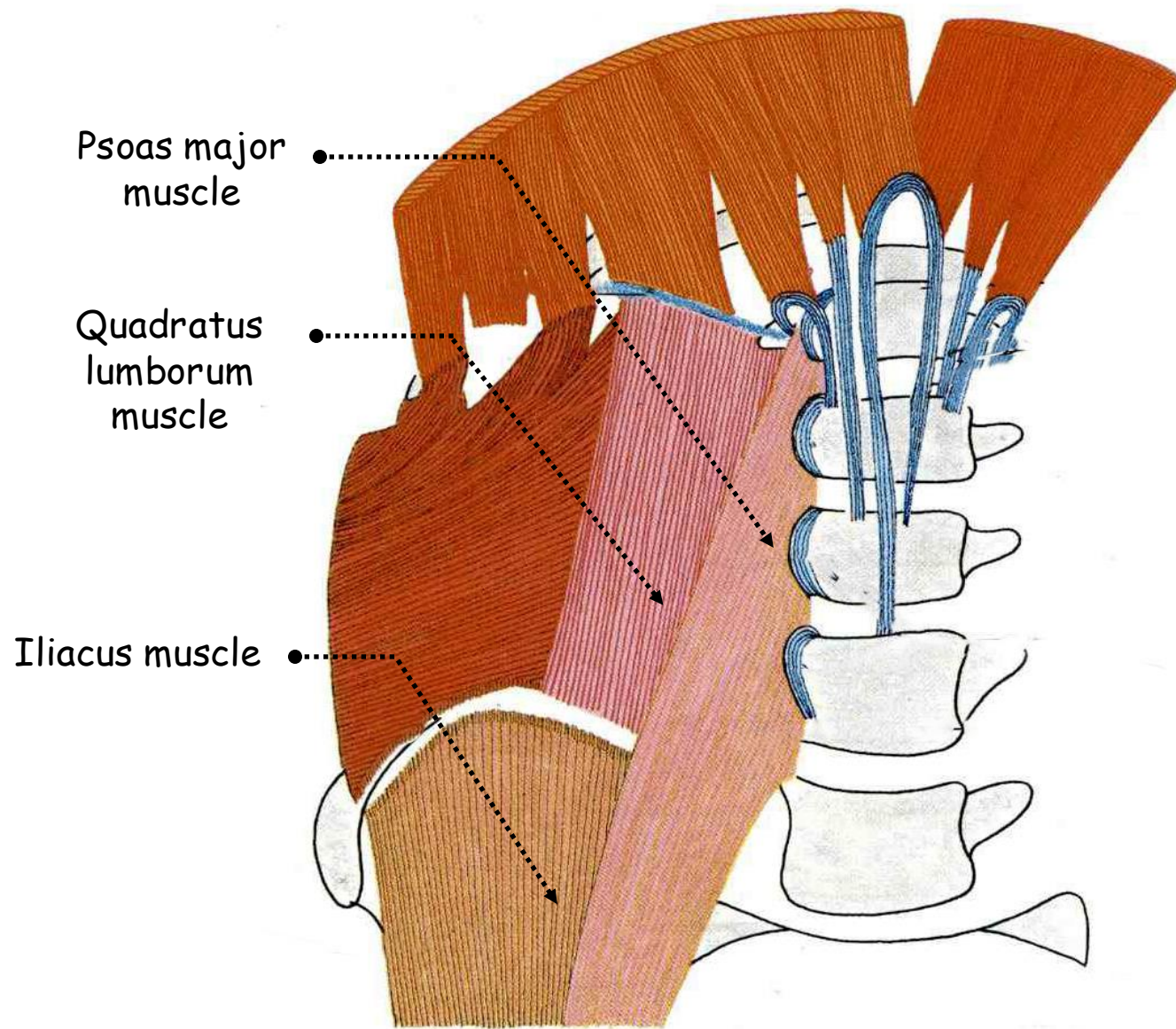
• **Action:**

- Flexor of the thigh
- Lateral rotator of the hip
- Simultaneous action: flexor of the trunk



16. Iliac fascia:

- Each muscle of the posterior abdominal wall is covered with a dense and unyielding fascia
- Strong
- Attached to bone at the margins of the muscle and to the inguinal ligament
- Floor to the abdominal cavity
- Serves for the attachment of parietal peritoneum
- Prolongation into the femoral sheath



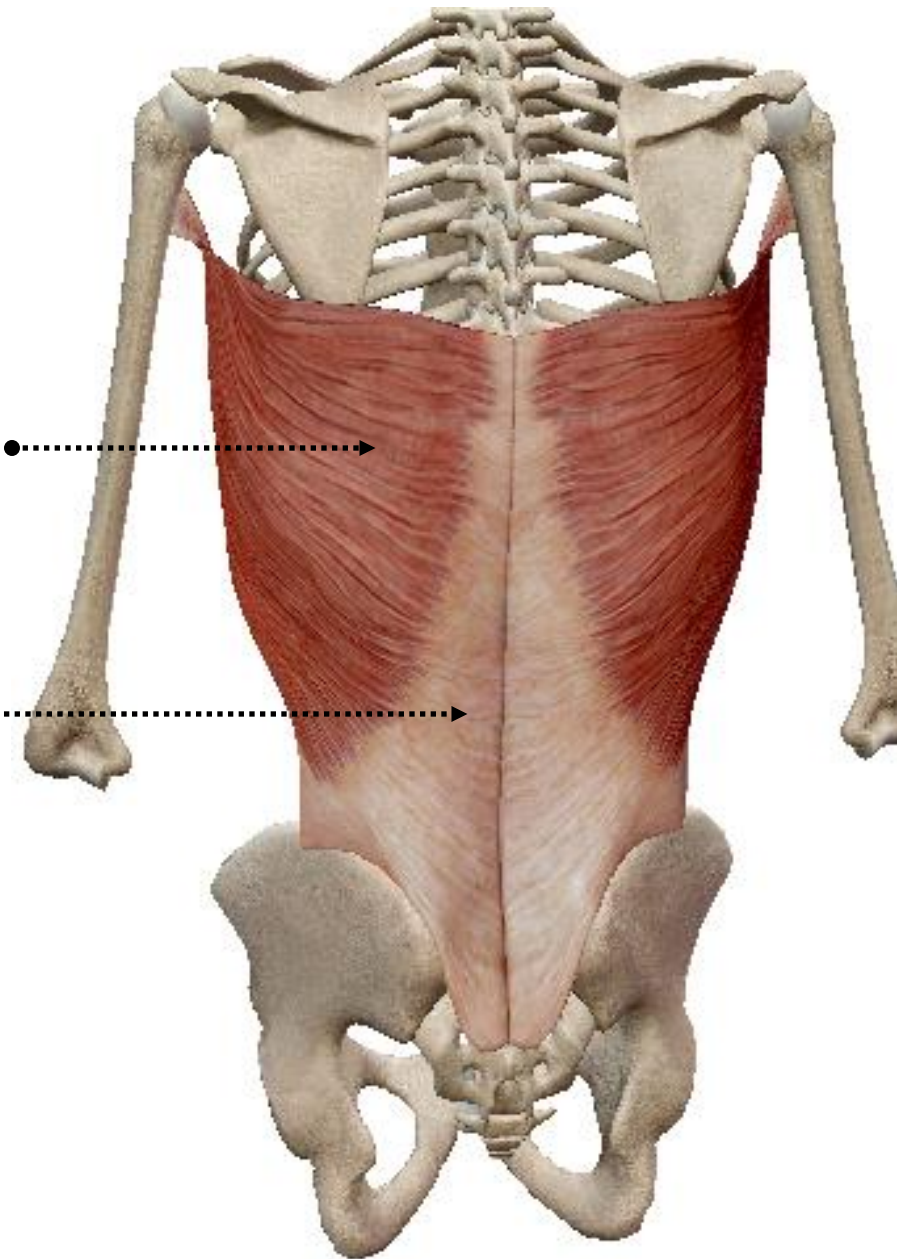
ANTERIOR VIEW OF THE SKELETON OF THE ABDOMEN SHOWING THE MUSCLES OF THE POSTERIOR ABDOMINAL WALL

17. Lumbar fascia:

- Lumbar part of the thoracolumbar fascia
- Three layers of tough fibrous tissue enclose two muscular compartments
- Anterior and middle layers occupy only the lumbar region
- Posterior layer extends above this to the lower part of the neck as the thoracic part of the thoracolumbar fascia and below to the dorsal surface of the sacrum
- Anterior compartment: quadratus lumborum
- Posterior compartment: erector spinae

Latissimus dorsi muscle

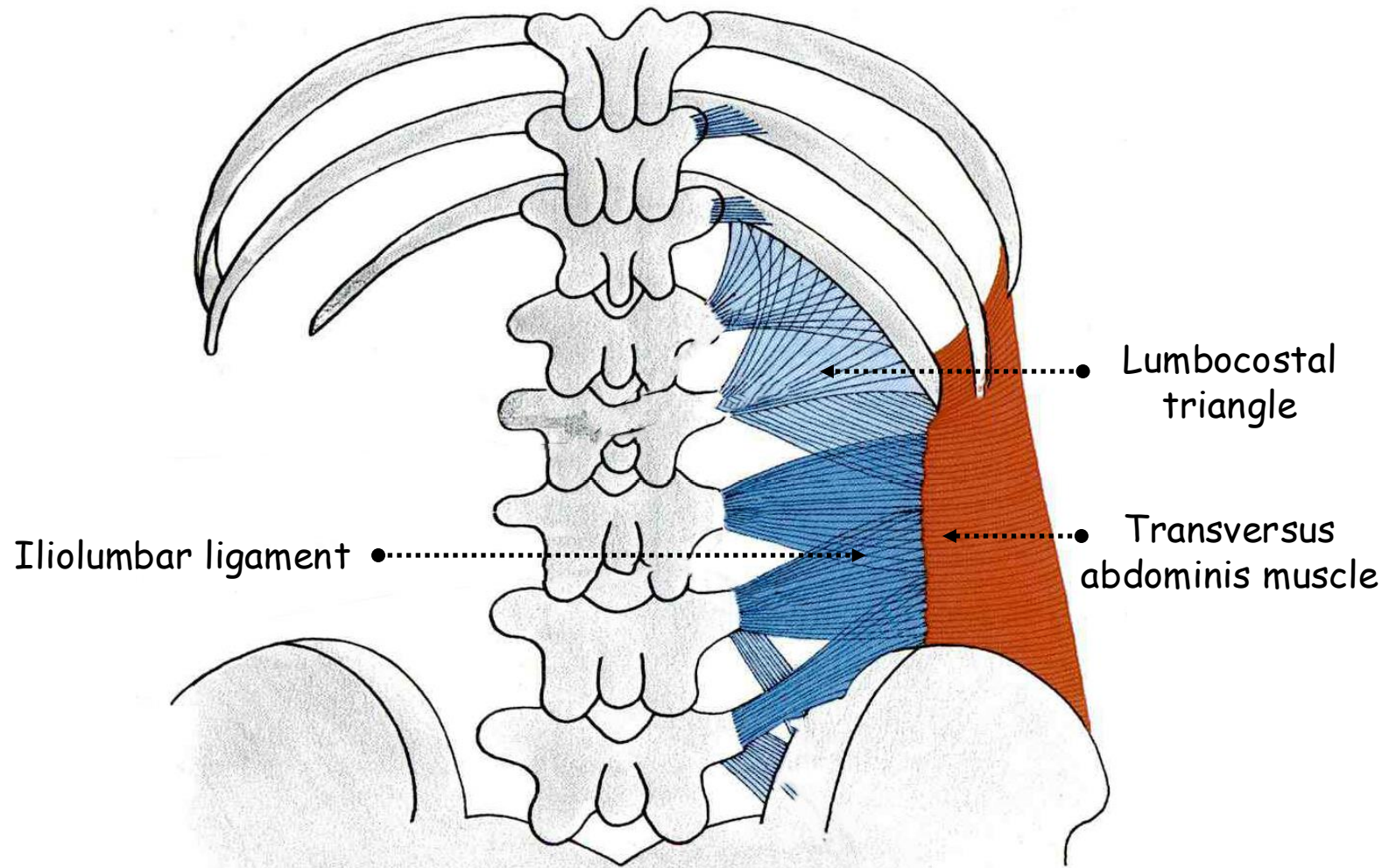
Lumbar fascia



POSTERIOR VIEW OF THE SKELETON OF THE TRUNK SHOWING LATISSIMUS DORSI MUSCLE AND LUMBAR FASCIA

- **Anterior layer:**

- Extends from the front of the iliolumbar ligament and adjoining iliac crest to the lower border of the twelfth rib
- Medially:** attached to the front of each lumbar transverse process near its root adjoining the attachment of the psoas fascia
- Laterally:** blends with the middle layer along the lateral border of quadratus lumborum; here transversus abdominis and internal oblique take origin



DEEP POSTERIOR VIEW OF THE SKELETON OF THE ABDOMEN
SHOWING THE ILIOLUMBAR LIGAMENT

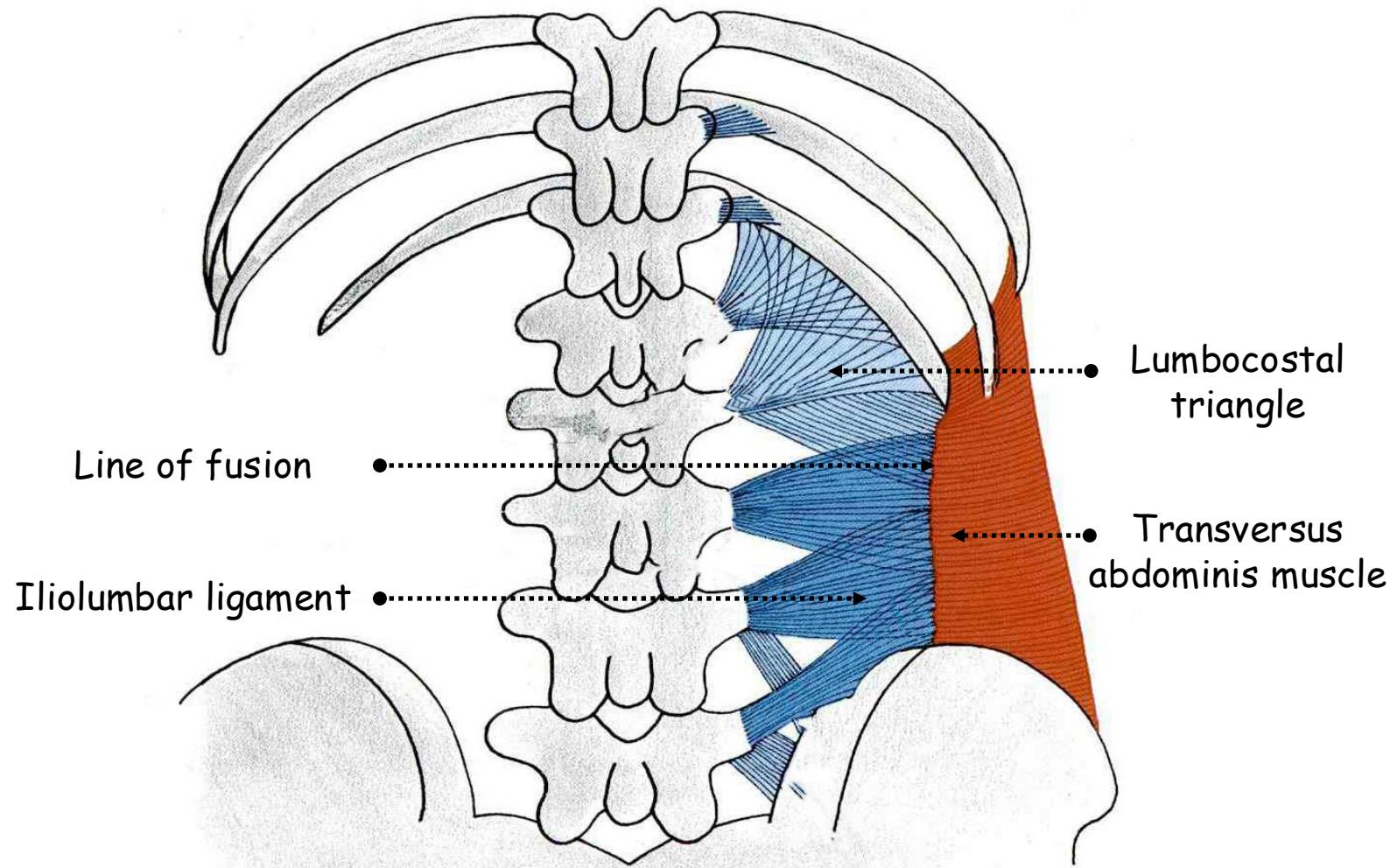
- **Middle layer:**

- Extends from the back of the iliolumbar ligament and adjoining iliac crest up to the twelfth rib

- Medially:** attached to the tips of the lumbar transverse processes

- Laterally:** blends with both anterior and posterior layers

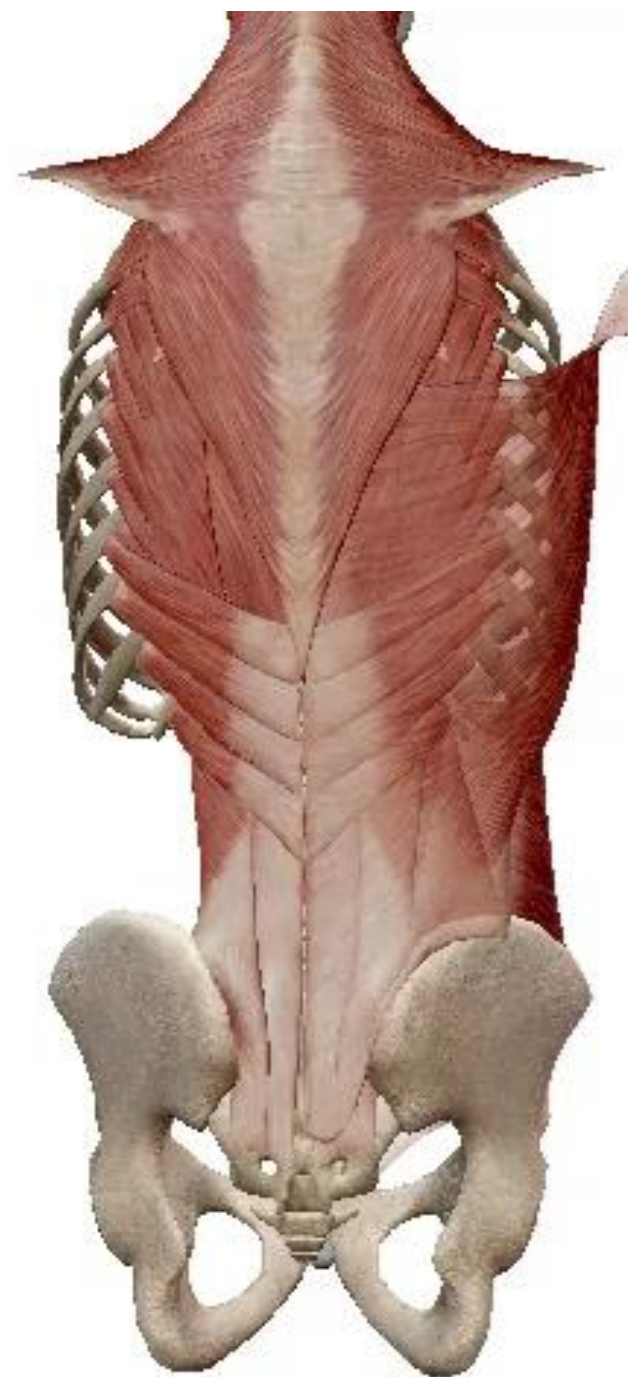- Line of fusion:** along the lateral borders of quadratus lumborum and erector spinae sloping in opposite obliquities crossing each other like the limbs of a very narrow X



DEEP POSTERIOR VIEW OF THE SKELETON OF THE ABDOMEN
SHOWING THE ILIOLUMBAR LIGAMENT

- **Posterior layer:**

- Lies over the whole erector spinae mass of muscle
- Medially: attached to the spinous processes and supraspinous ligaments of all the sacral, lumbar and thoracic vertebrae
- Laterally: extends along the transverse tubercles of the sacrum to the ridge on the posterior part of the iliac crest sloping outwards to the twelfth rib being attached across the lumbar region to the middle layer along the lateral border of iliocostalis
- Thick and reinforced by fusion of the aponeurotic origin of latissimus dorsi
- Thoracic part: above 12th rib



18. Lumbar triangle of Petit:

- Floored in by the internal oblique muscle
- Lower base and upper apex
- Bounded by:
 - Forwards: posterior border of external oblique muscle
 - Backwards: anterior border of latissimus dorsi muscle
 - Downwards: iliac crest
- Weakness zone

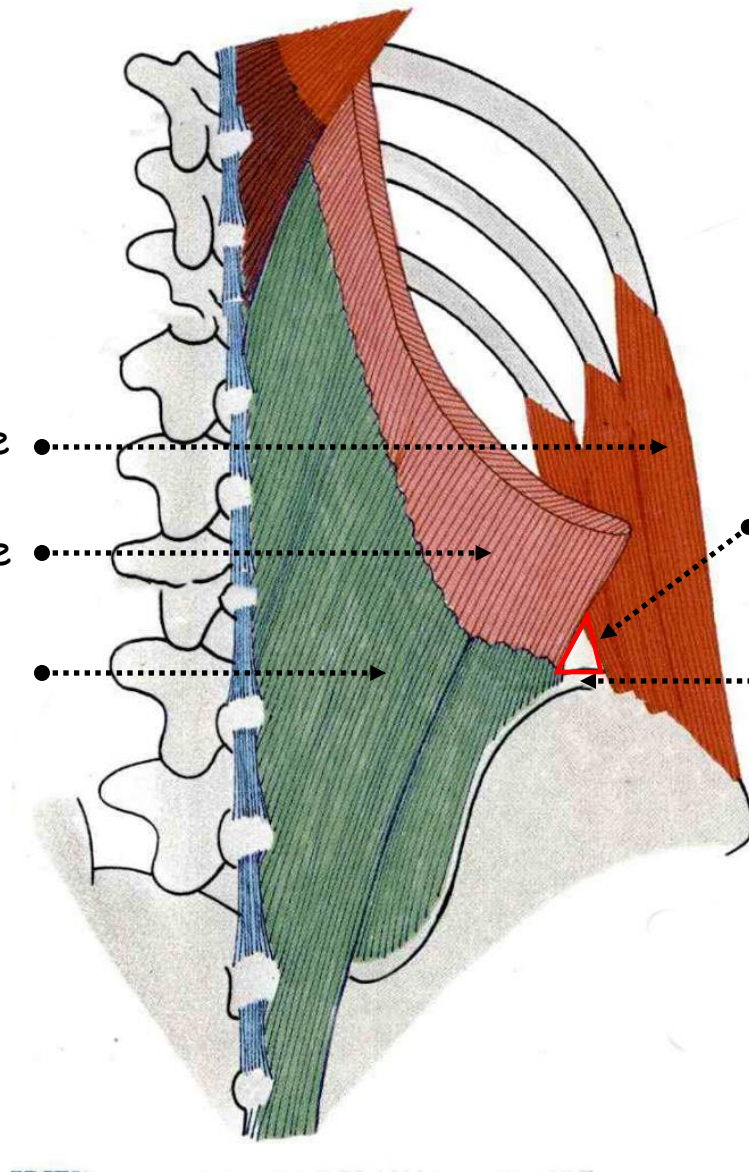
External oblique muscle

Latissimus dorsi muscle

Lumbar fascia

Lumbar triangle of Jean-Louis Petit

Iliac crest

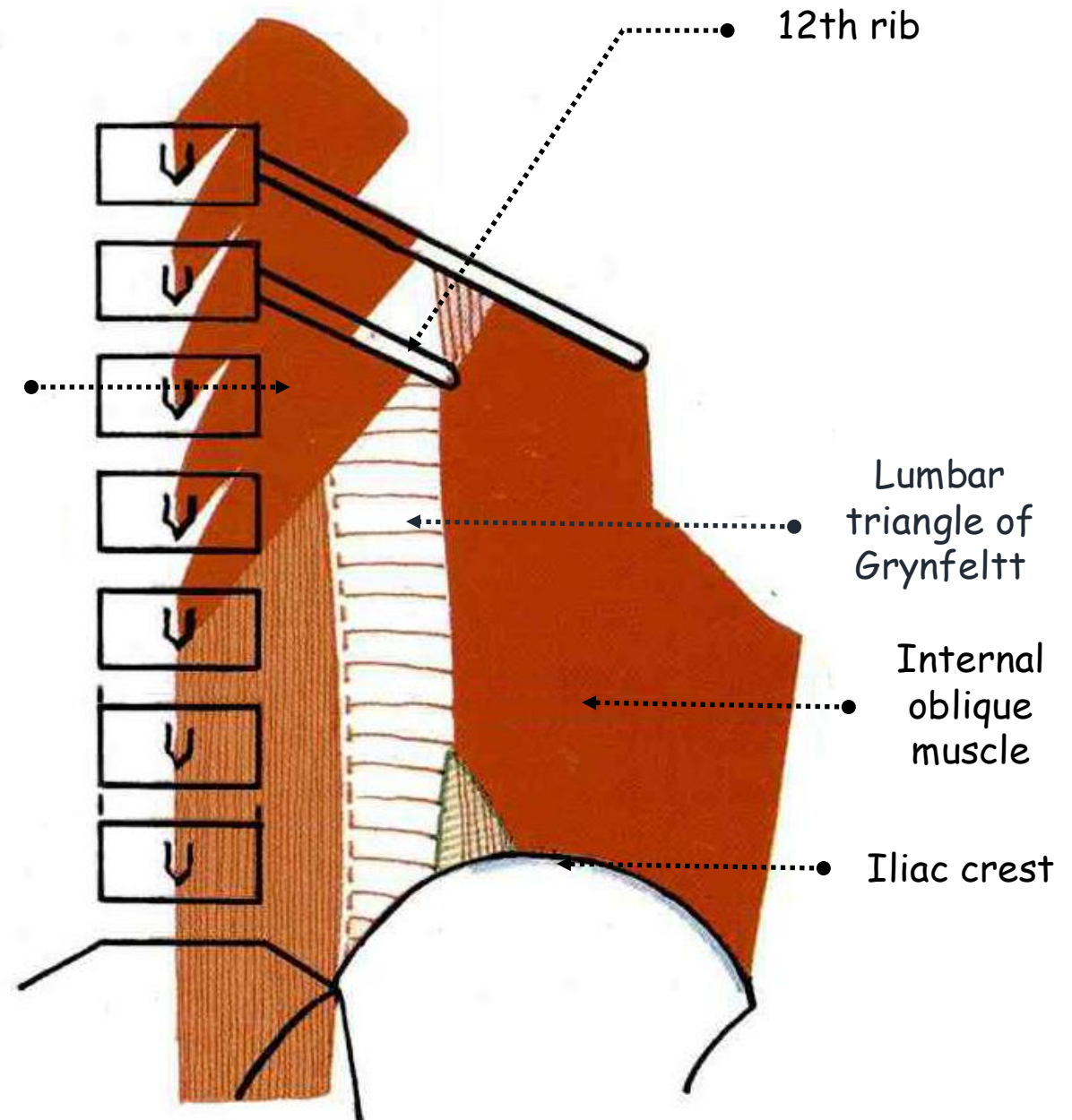


POSTERIOR VIEW OF THE SKELETON OF THE ABDOMEN SHOWING THE LUMBAR TRIANGLE OF PETIT

18. Lumbar triangle of Grynfeltt:

- Variable shape
- Floored by iliolumbar ligament and aponeurosis of transversus abdominis muscle
- Roofed by external oblique and latissimus dorsi muscles
- Bounded by:
 - Medially: lateral border of quadratus lumborum muscle
 - Upwards: tip of the 12th rib
 - Laterally: internal oblique muscle
- Weakness zone

Quadratus lumborum muscle



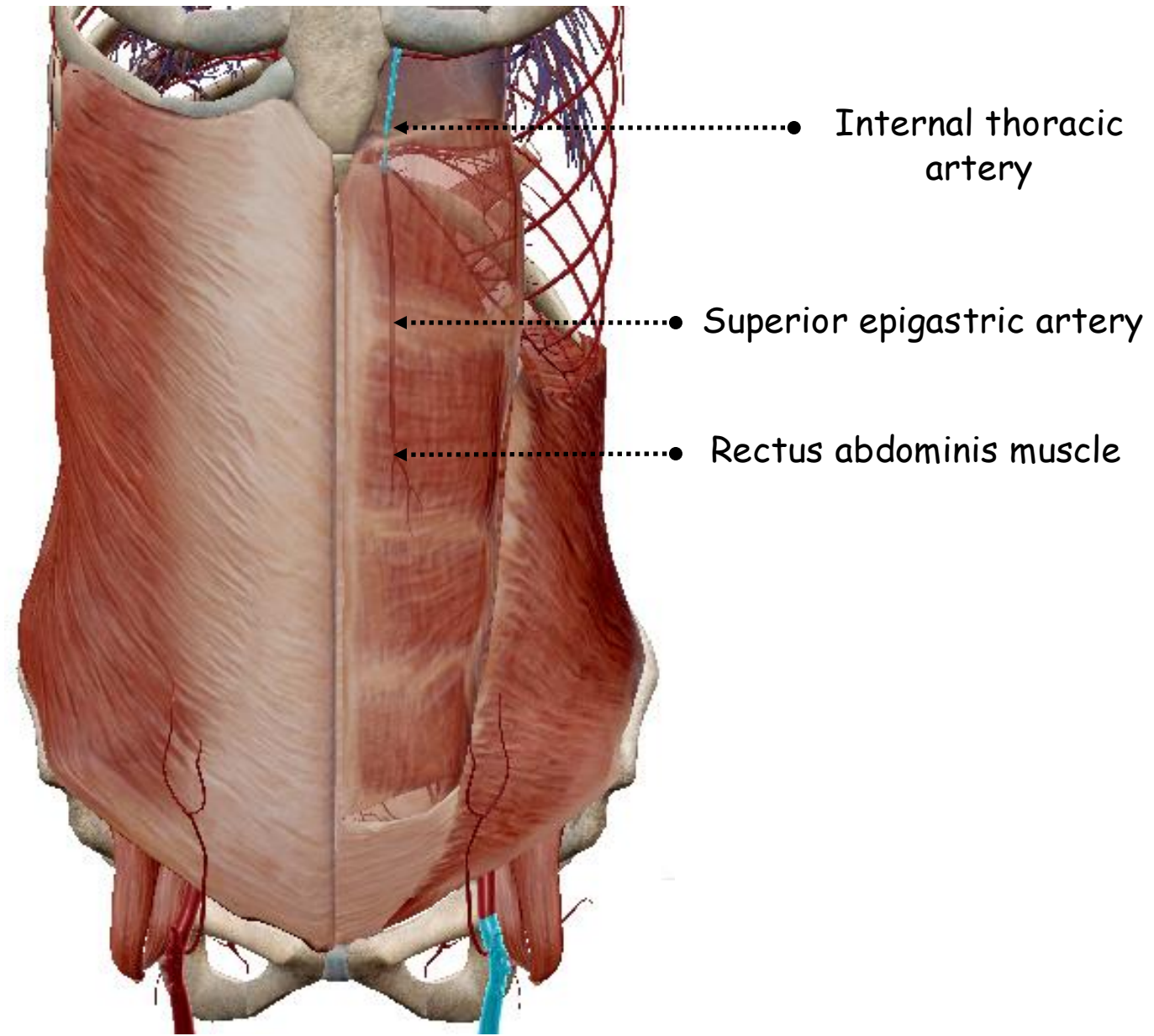
POSTERIOR VIEW OF THE SKELETON OF THE ABDOMEN SHOWING THE LUMBAR TRIANGLE OF GRYNFELTT

III. BLOOD SUPPLY; LYMPH DRAINAGE AND NERVE SUPPLY

A. ANTERIOR ABDOMINAL WALL

1. Arteries:

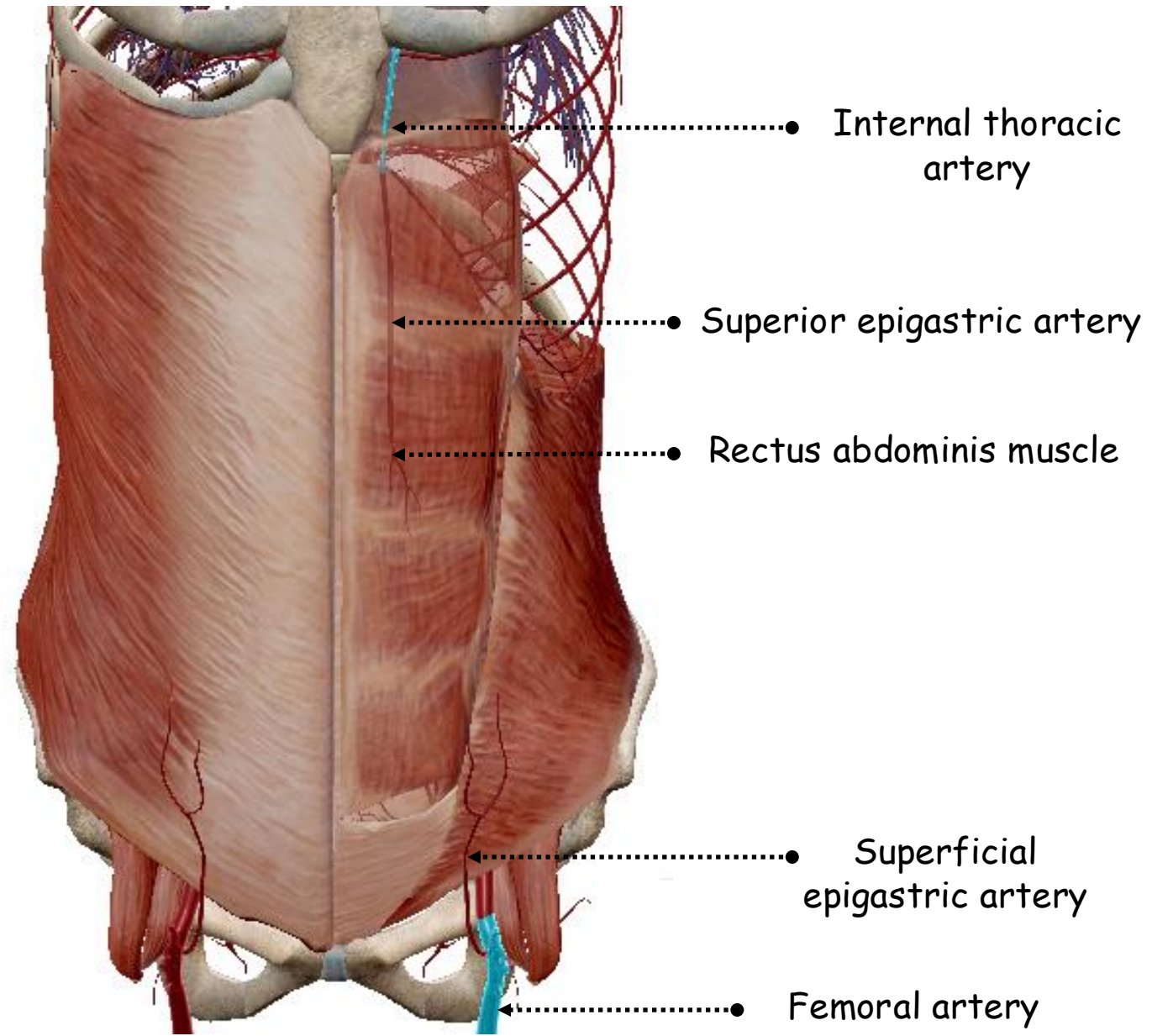
- Rich
- **Superior epigastric artery:**
 - Terminal branch of the internal thoracic
 - Enters the rectus sheath by passing between the **sternal** and **highest costal** fibres of the diaphragm
 - Supplies the **rectus muscle** and **anastomoses** within it with the **inferior epigastric artery**



ANTERIOR VIEW OF THE ANTERIOR ABDOMINAL WALL SHOWING ITS ARTERIES

• **Superficial epigastric artery:**

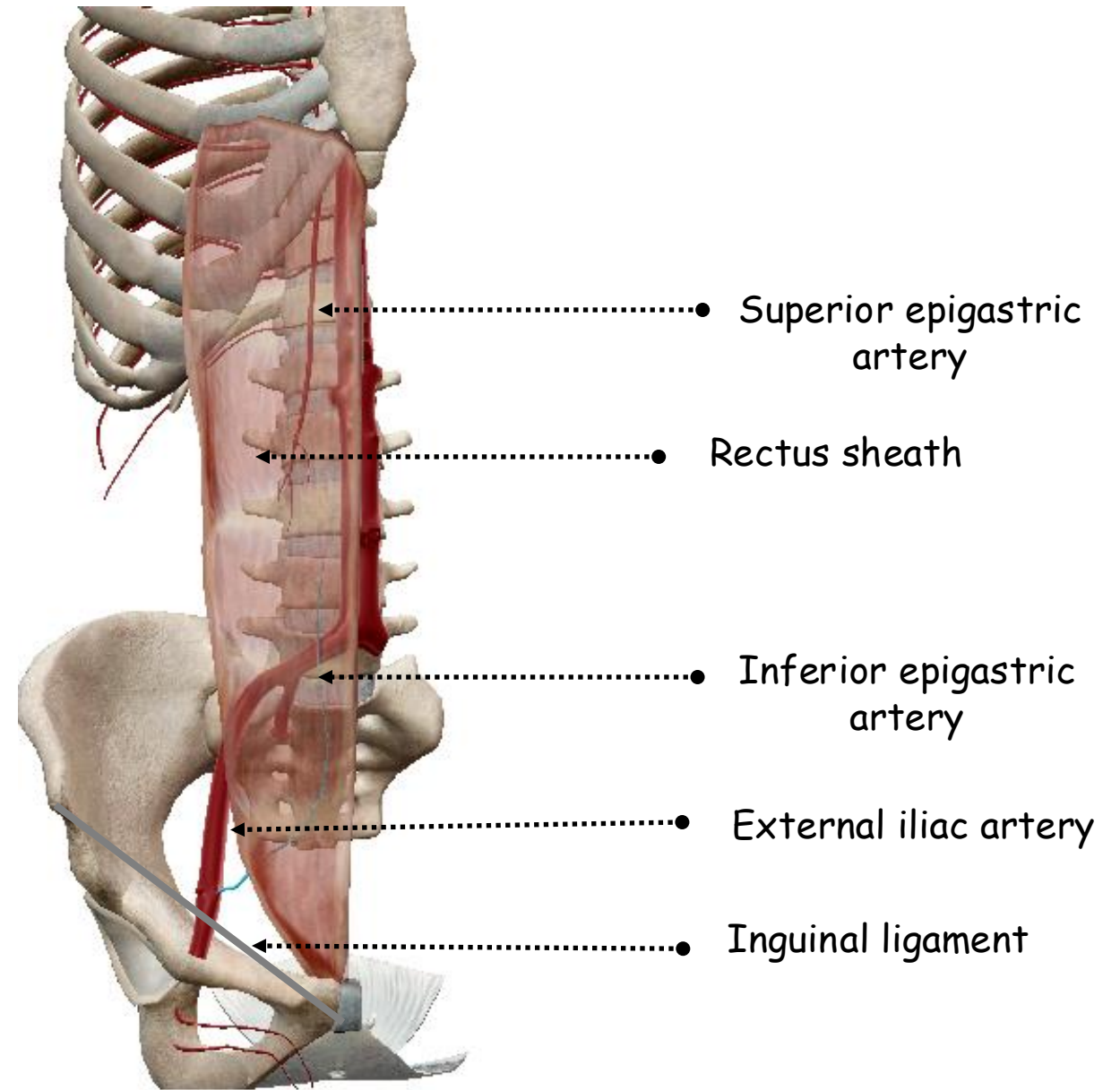
- Cutaneous branch of the femoral artery
- May pierce the fascia lata or emerge through the saphenous opening
- Crosses the inguinal ligament and is distributed towards the umbilicus to the skin and fat of the lower abdominal wall



ANTERIOR VIEW OF THE ANTERIOR ABDOMINAL WALL SHOWING ITS ARTERIES

- **Inferior epigastric artery:**

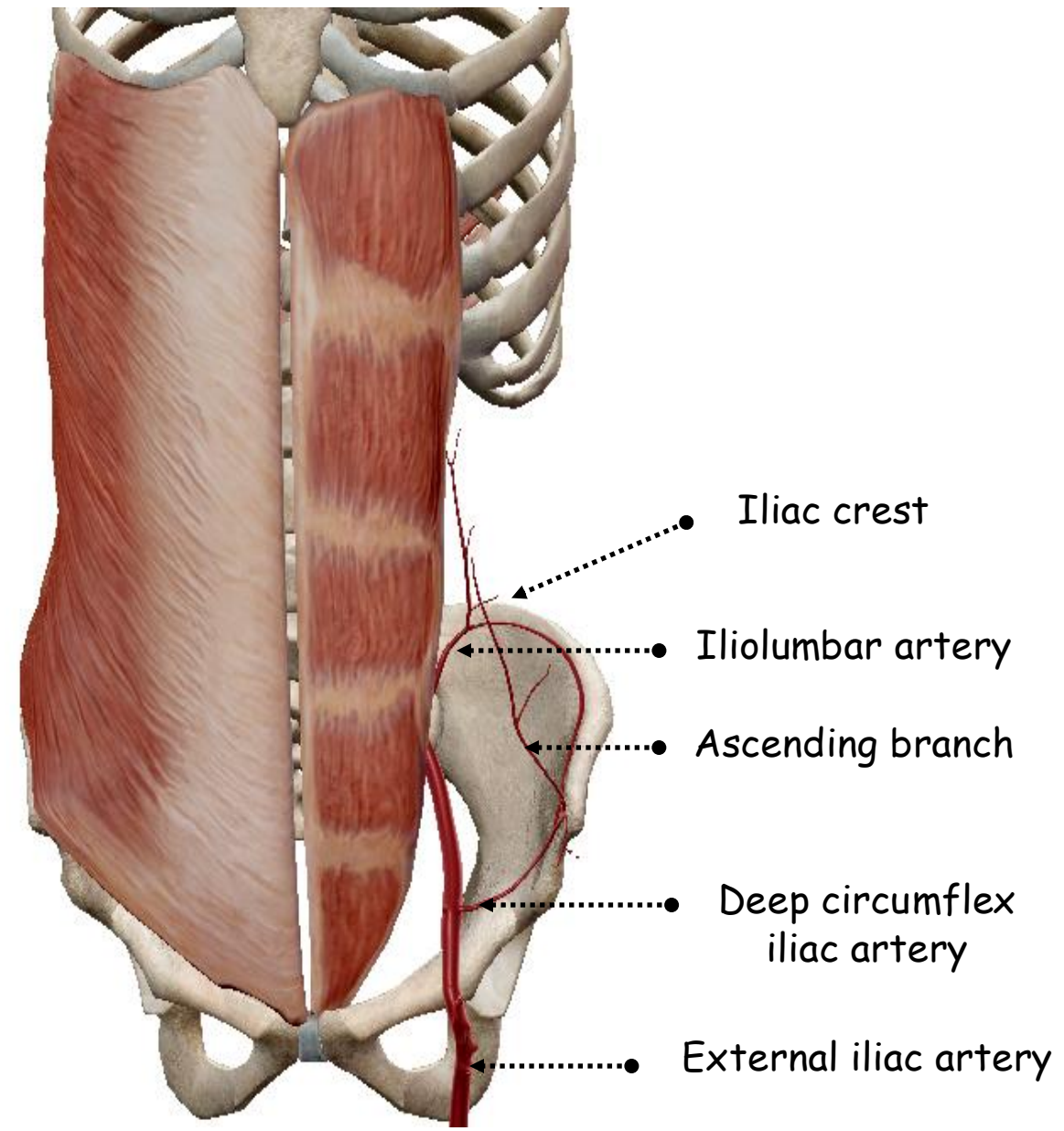
- Leaves the external iliac at the inguinal ligament
- Passes upwards behind the conjoint tendon
- Slips over the semicircular fold and so enters the sheath



ANTERIOR VIEW OF THE SKELETON OF THE TRUNK SHOWING THE ARTERIES OF THE ANTERIOR ABDOMINAL WALL

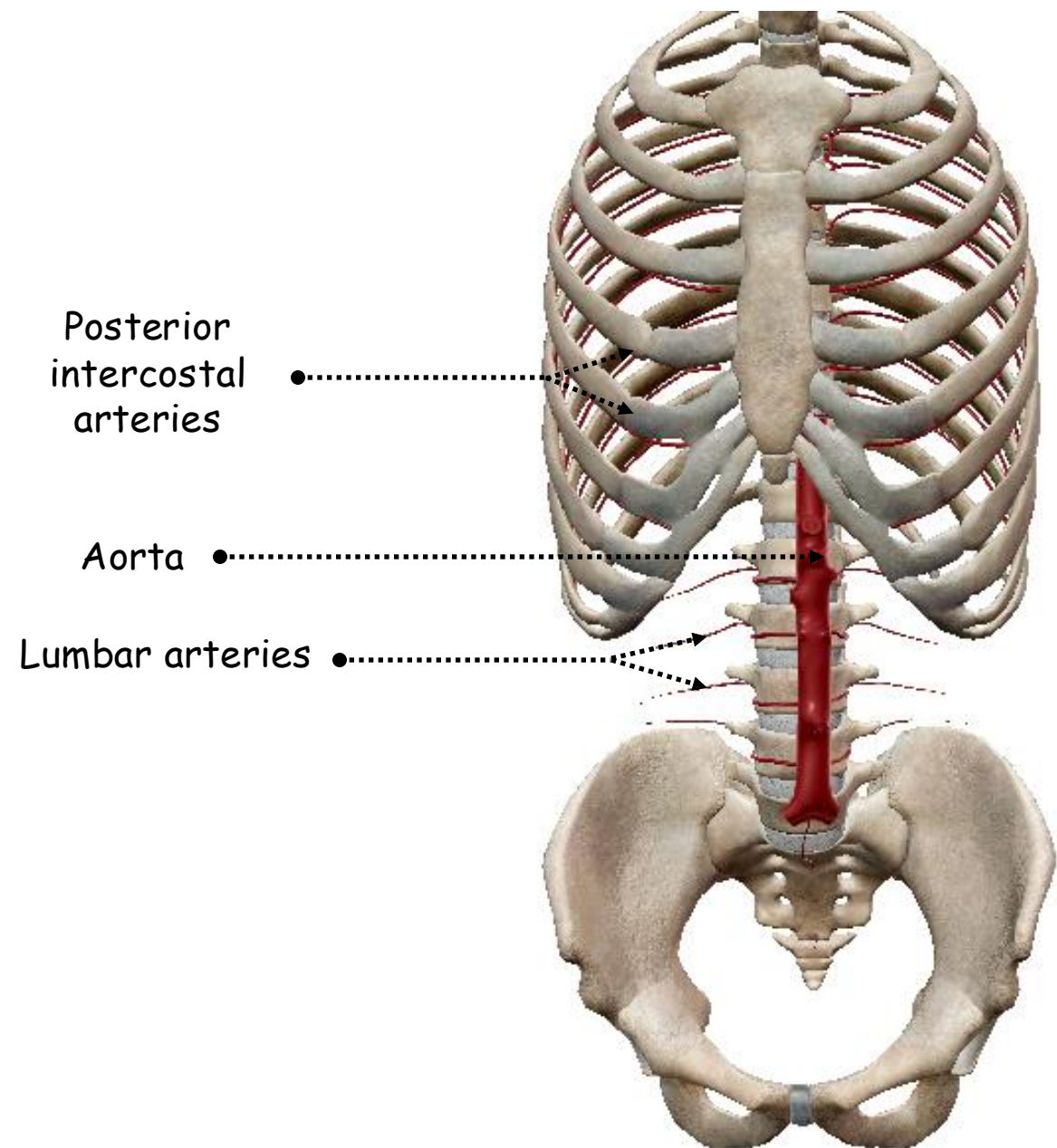
• **Deep circumflex iliac artery:**

- Arises from the external iliac behind the inguinal ligament
- Runs laterally towards the anterior superior iliac spine in a canal of tissue where the transversalis and iliac fasciae meet
- Continues along the inner lip of the iliac crest anastomoses with branch of the iliolumbar
- At the anterior superior iliac spine it gives off an ascending branch which enters the neurovascular plane to anastomose with the inferior epigastric



ANTERIOR VIEW OF THE SKELETON OF THE TRUNK SHOWING THE ARTERIES OF THE ANTERIOR ABDOMINAL WALL

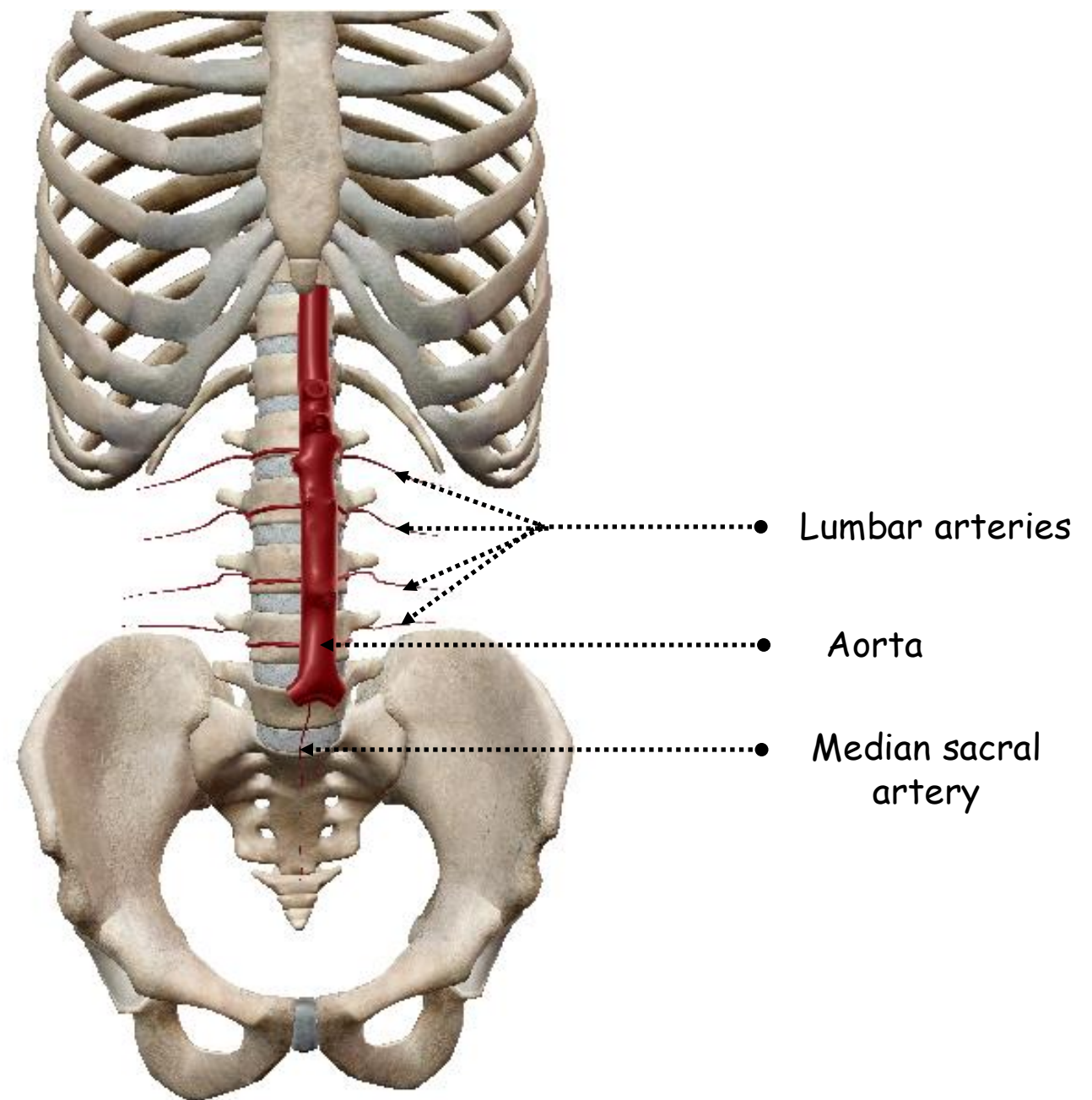
- **7 lower intercostal arteries:**
 - Arise from descending thoracic aorta
 - Each gives off a **small collateral branch**, which passes around in **the neurovascular plane** at a lower level than the main trunk



ANTERIOR VIEW OF THE SKELETON OF THE TRUNK SHOWING THE ARTERIES OF THE POSTERIOR ABDOMINAL WALL

• Lumbar arteries:

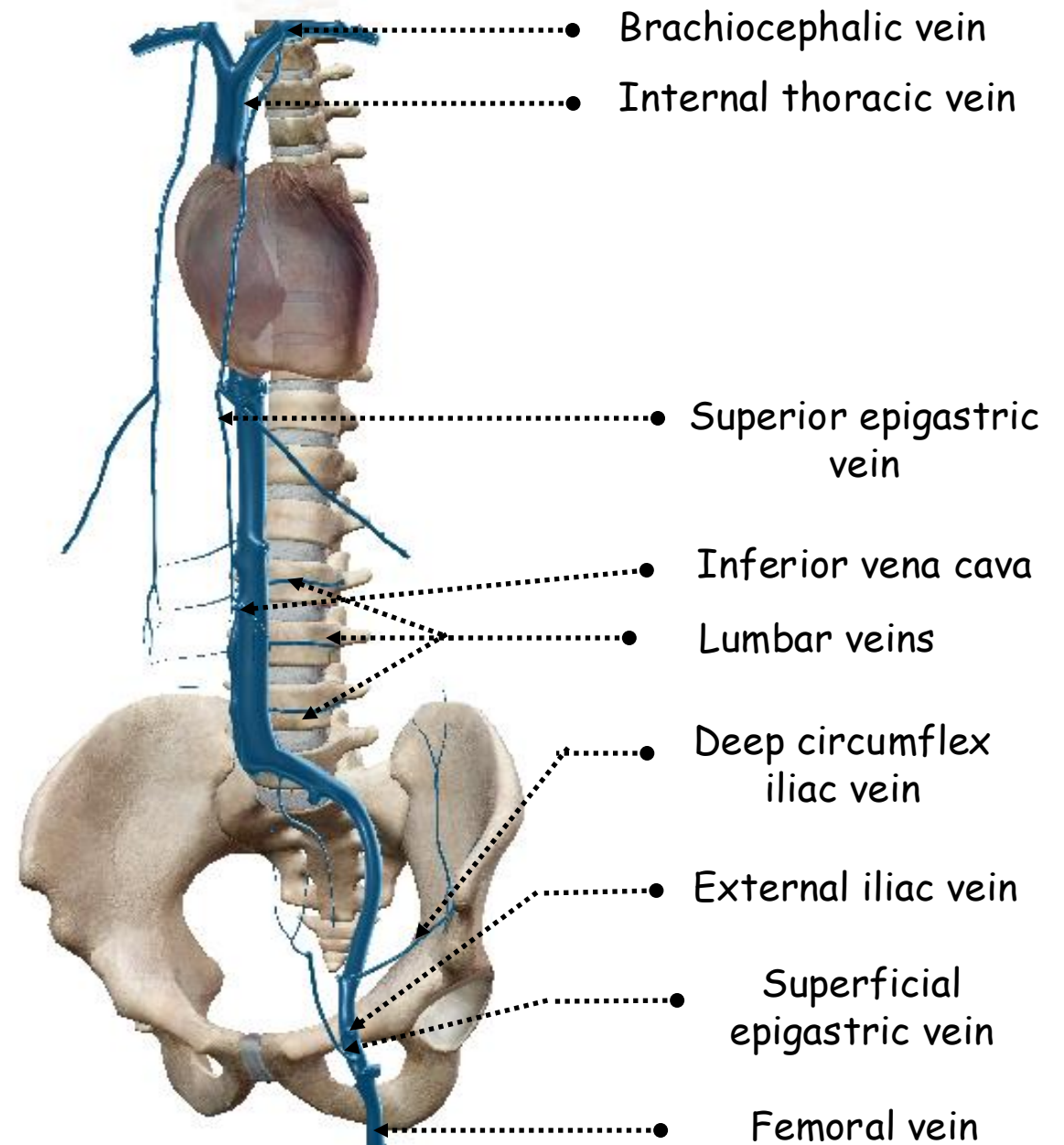
- Four in number
- Leave the abdominal aorta opposite the bodies of the upper four vertebrae
- Pass beneath the lumbar sympathetic trunks and the fibrous arches in the psoas
- Overlaid on the right side by the inferior vena cava
- Each artery gives off posterior and spinal branches
- 3 upper pass laterally behind quadratus lumborum muscle into the neurovascular plane between transversus abdominis and internal oblique
- 4th passes in front of the lower border of quadratus lumborum, along the upper margin of the iliolumbar ligament



ANTERIOR VIEW OF THE SKELETON OF THE TRUNK SHOWING THE LUMBAR ARTERIES

2. Veins:

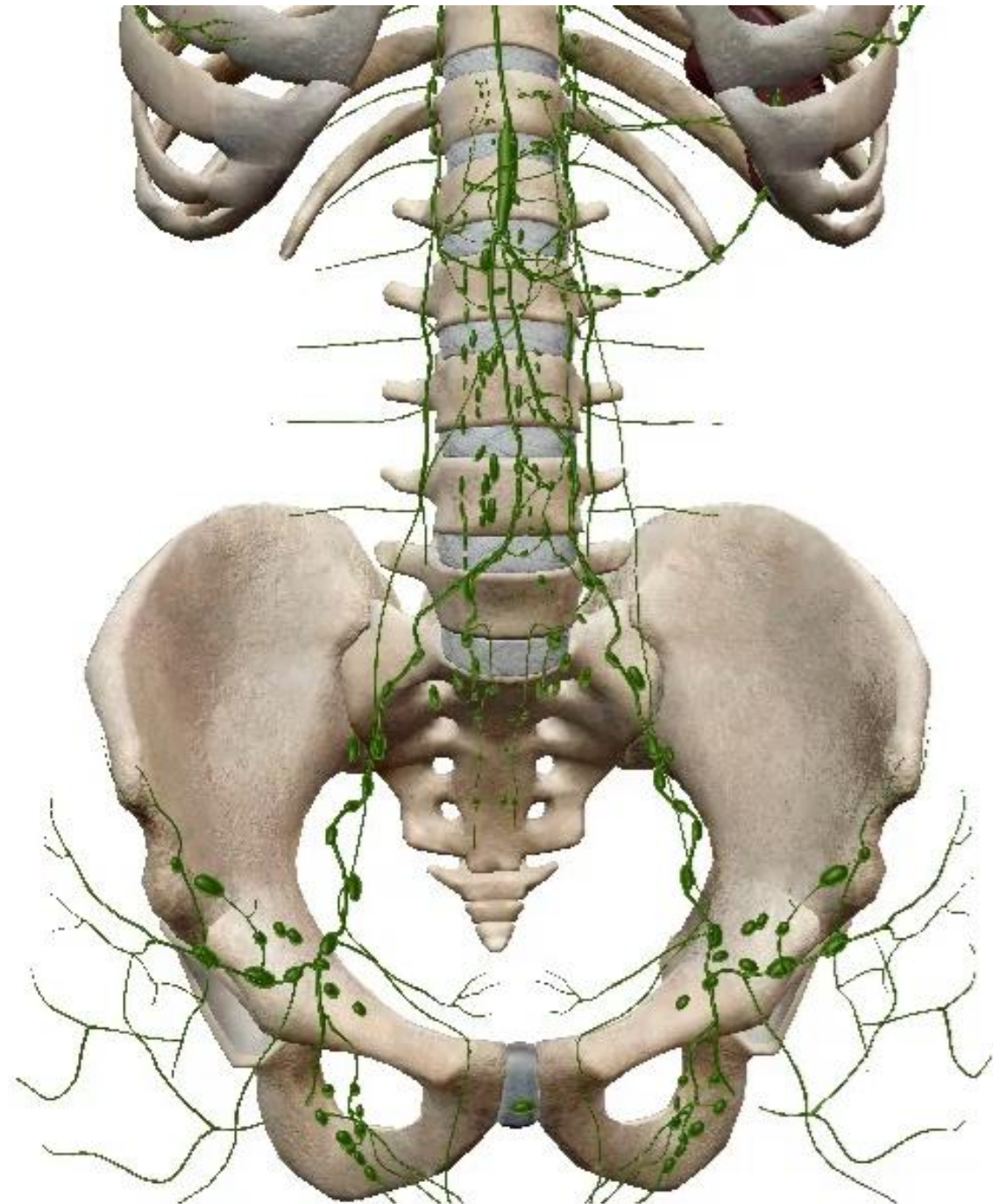
- Follow the arteries
- Flow into:
 - Brachiocephalic vein: through internal thoracic vein
 - Inferior vena cava: lumbar veins
 - Femoral vein: superficial epigastric vein
 - External iliac vein: inferior epigastric and deep circumflex iliac
 - Azygos system: the azygos vein on the right and the hemiazygos and accessory hemiazygos on the left through posterior intercostal
- Portosystemic anastomosis: between paraumbilical veins in the ligamentum teres and inferior epigastric vein



ANTERIOR VIEW OF THE SKELETON OF THE TRUNK SHOWING THE VEINS OF THE ABDOMINAL WALL

3. Lymph drainage:

- Drain in quadrants
- 2 levels: superficial and deep
- **Deep:**
 - Above the umbilicus: pierce the diaphragm to reach mediastinal nodes
 - Below: external iliac and para-aortic nodes
- **Superficial:**
 - Above the umbilicus on each side: pectoral group of axillary nodes
 - Below that level: superficial inguinal nodes
- Surprisingly not draining to intercostal nodes



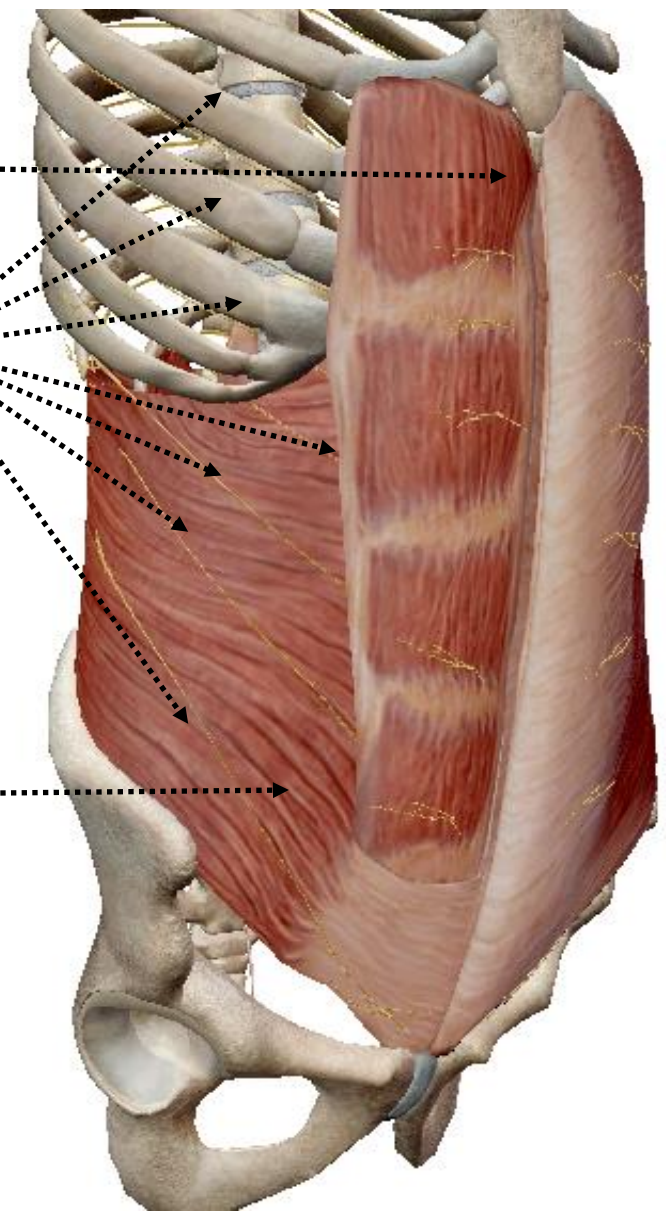
4. Nerves:

- Rectus and external oblique muscles: lower intercostal and subcostal nerves T7-T12
- Internal oblique and transversus abdominis muscles: same nerves added to ilioinguinal and iliohypogastric nerves
- Pyramidalis muscle: subcostal nerve

Rectus abdominis muscle

Lower intercostal nerves

External oblique muscle



ANTERIOR LATERAL VIEW OF THE SKELETON OF THE ANTEROLATERAL ABDOMINAL WALL SHOWING ITS NERVES

• **Lower intercostal and subcostal nerves T7-T12:**

- Pass from their **intercostal spaces** into the abdominal wall through the **neurovascular plane** between the internal oblique and transversus abdominis muscles
- Enter the **rectus sheath** by piercing the **posterior layer of the internal oblique aponeurosis**
- Proceed **behind the rectus muscle** to about its **midline**
- Pierce** the muscle, **supply** it, and pass through the **anterior layer of the sheath** to become the **anterior cutaneous nerves**
- T7** runs **upwards** just below the costal margin, **T8** transversely and the others **obliquely downwards**



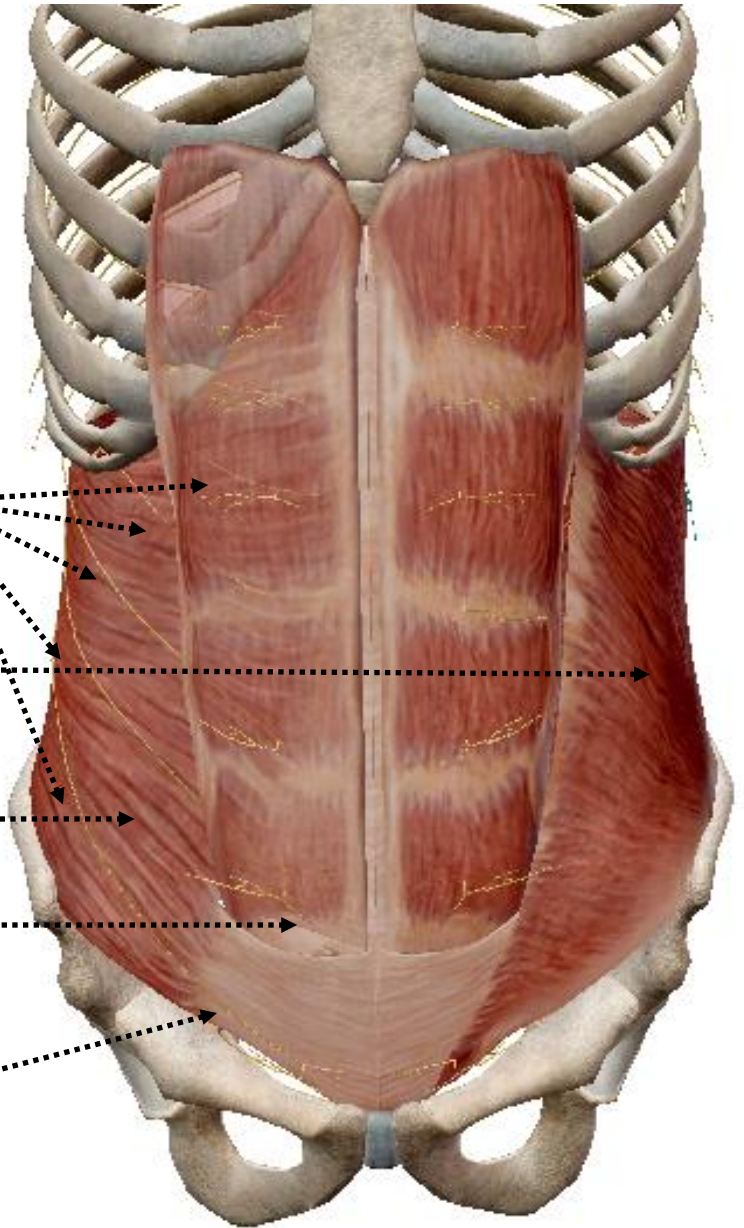
Lower intercostal nerves

Internal oblique muscle

Transversus abdominis muscle

Rectus sheath

Anterior cutaneous nerves



ANTERIOR VIEW OF THE SKELETON OF THE TRUNK SHOWING THE LOWER INTERCOSTAL NERVES

-Before they reach the sheath the nerves have given off their lateral cutaneous branches, which pierce the internal and external obliques to the skin supplying the external oblique muscle

-Subcostal nerve: passes from the thorax behind the lateral arcuate ligament, slopes down below the vein and artery lying parallel to the twelfth rib across the front of the anterior layer of the lumbar fascia, disappears by passing through transversus abdominis to reach the neurovascular plane, slopes down again around the anterior abdominal wall



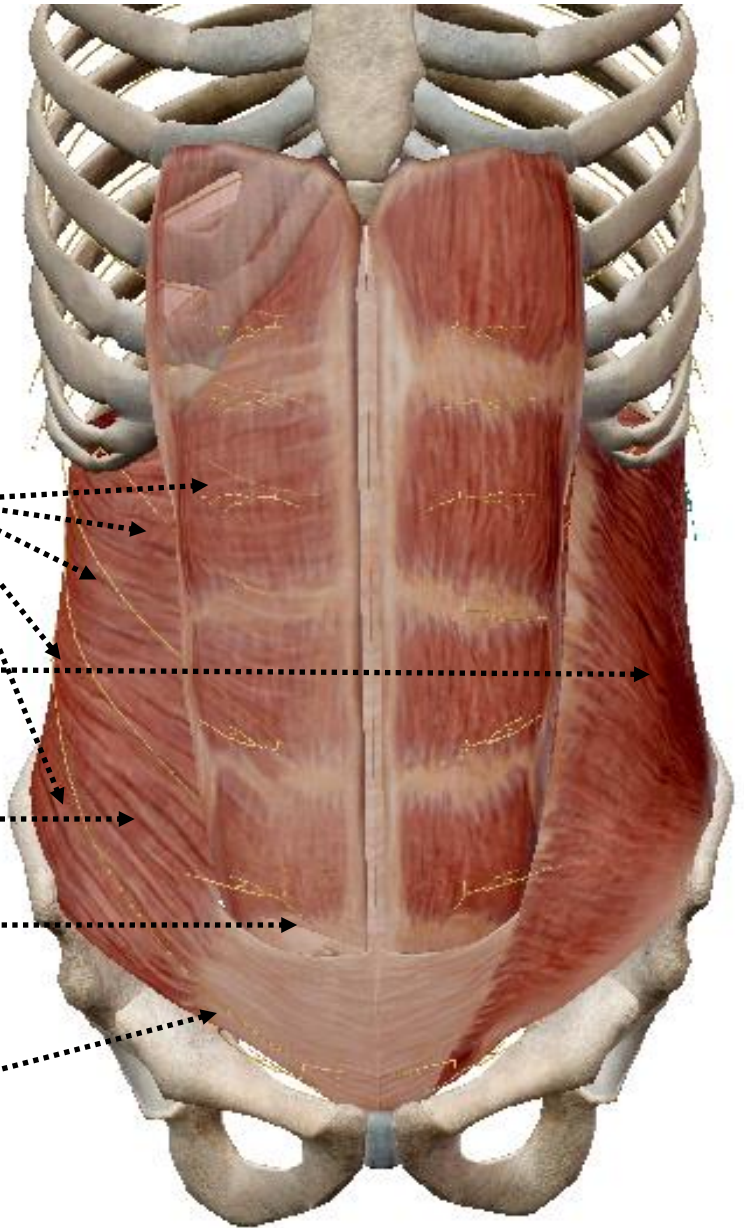
Lower intercostal nerves

Internal oblique muscle

Transversus abdominis muscle


Rectus sheath

Anterior cutaneous nerves



ANTERIOR VIEW OF THE SKELETON OF THE TRUNK SHOWING THE LOWER INTERCOSTAL NERVES

- Supplies the lower part of the anterior abdominal wall muscles and skin
- Lateral cutaneous branch: pierces the oblique muscles and descends over the iliac crest to supply the skin of the anterior part of the buttock



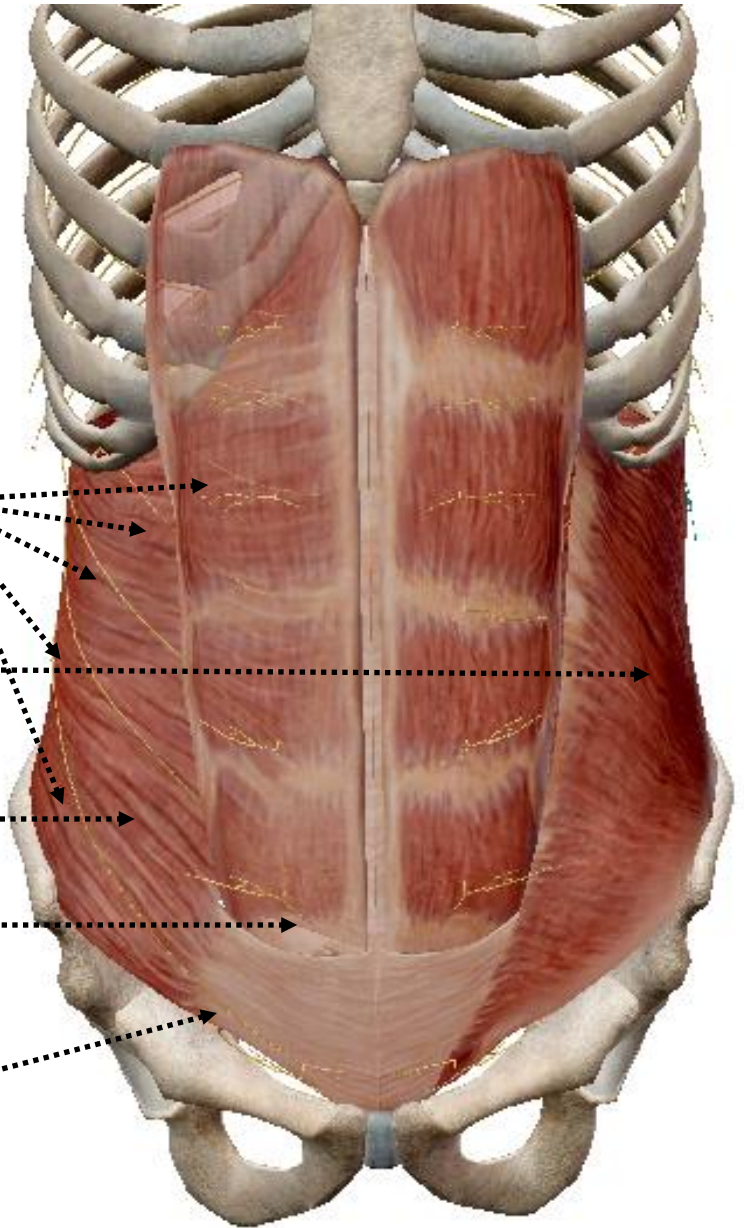
Lower intercostal nerves

Internal oblique muscle

Transversus abdominis muscle

Rectus sheath

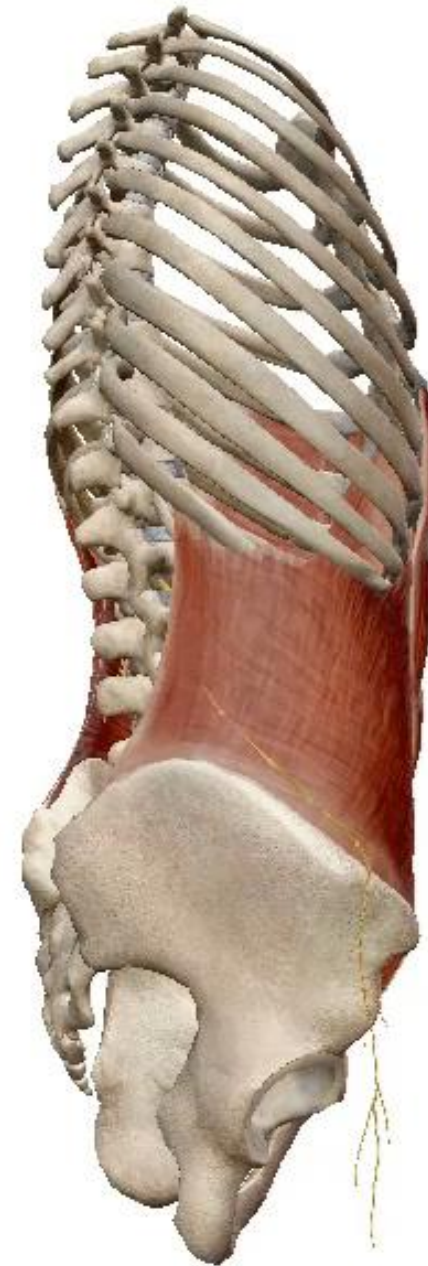Anterior cutaneous nerves



ANTERIOR VIEW OF THE SKELETON OF THE TRUNK SHOWING THE LOWER INTERCOSTAL NERVES

- **Iliohypogastric nerve:**

- Lies in front of quadratus lumborum at a lower level
- Arises from the anterior ramus of L1 dividing from a common stem with ilioinguinal lateral to psoas major muscle and in front of quadratus lumborum behind the anterior layer of the lumbar fascia
- Gives a lateral cutaneous branch which sinks below the iliac crest to supply skin of the upper part of the buttock behind the area supplied by the subcostal nerve

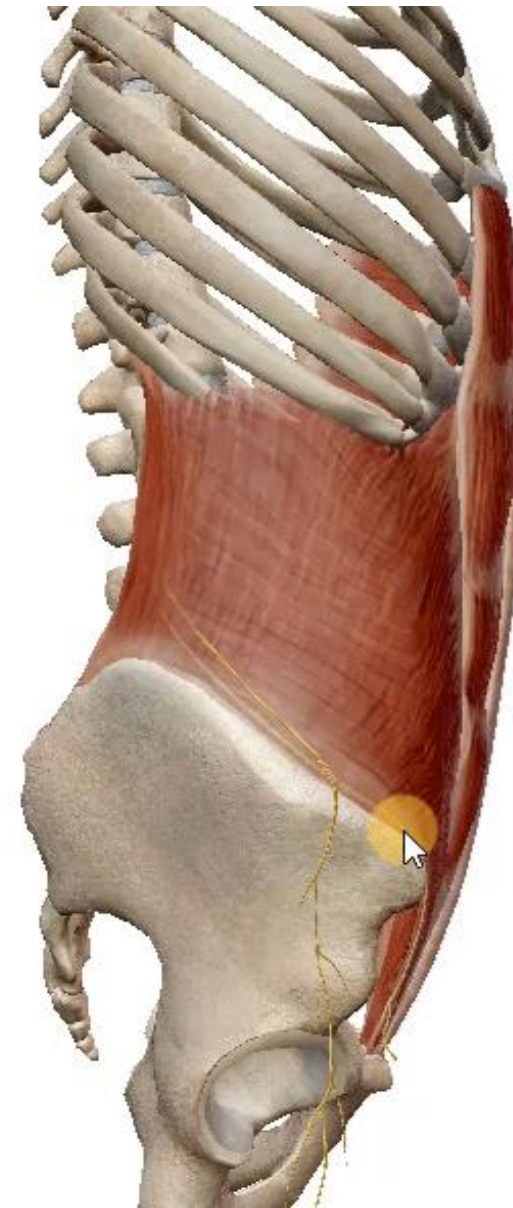

- Slopes downwards in the neurovascular plane and pierces the internal oblique above the anterior superior iliac spine
- Slopes down again between external and internal obliques and pierces the aponeurosis of the external oblique about 2.5 cm above the superficial inguinal ring and ends by supplying the skin over the lower part of rectus abdominis and the mons pubis

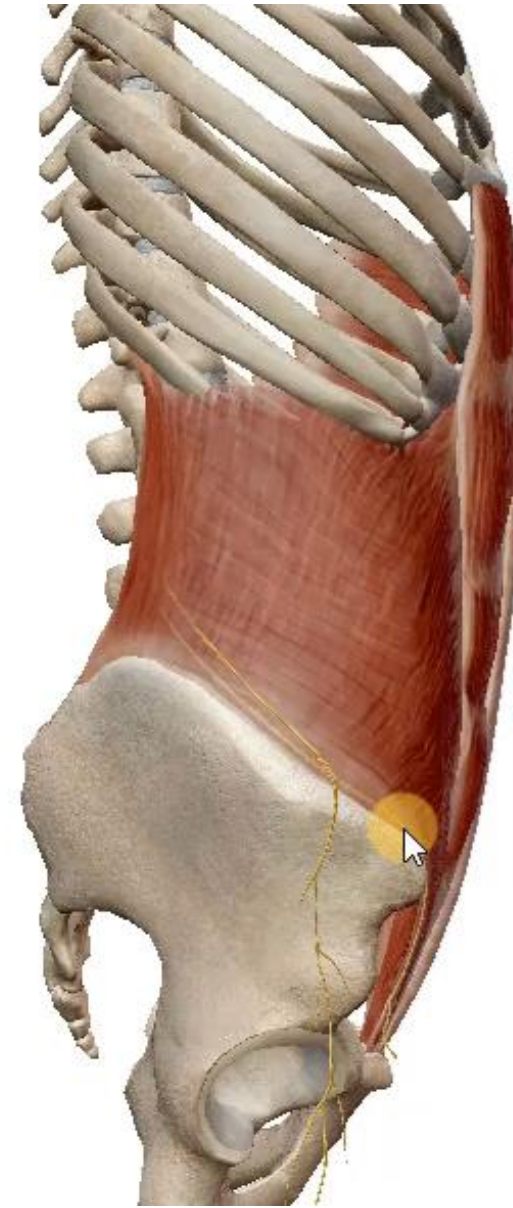

- **Ilioinguinal nerve:**

- Lies in front of quadratus lumborum at a lower level
- Arises from the anterior ramus of L1 dividing from a common stem with iliohypogastric lateral to psoas major muscle and in front of quadratus lumborum behind the anterior layer of the lumbar fascia
- Represents the collateral branch of the iliohypogastric and, consequently, has no lateral cutaneous branch
- Pierces the fascia and passes laterally to sink into transversus abdominis and run downwards and forwards, above the iliac crest, in the neurovascular plane parallel to and above iliohypogastric



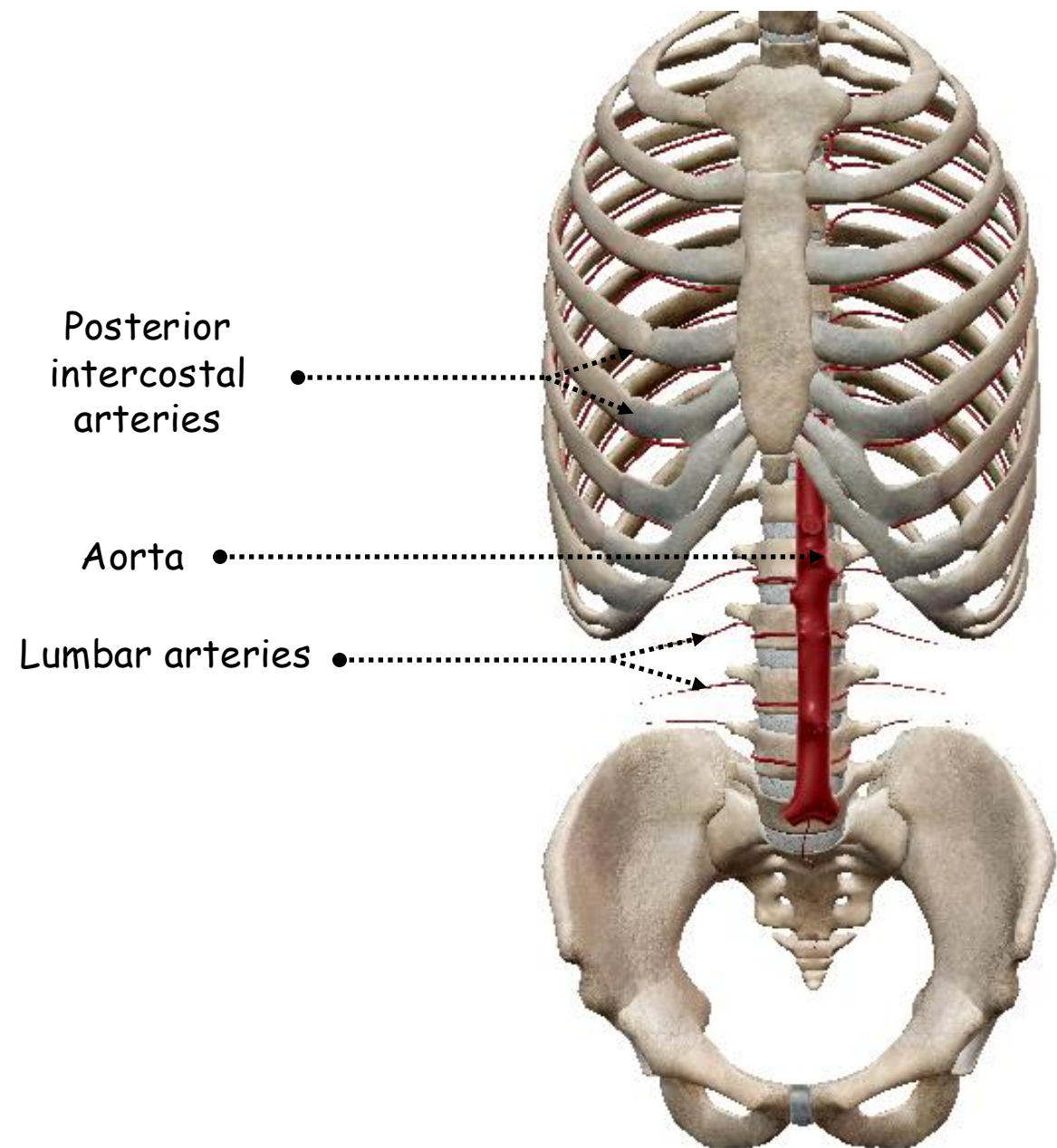

- Gives motor branches to those muscle fibres of internal oblique and transversus which are inserted into the free edge of the conjoint tendon before piercing the lower border of internal oblique, runs downwards and medially and so enters the inguinal canal from the side, continuing behind the external oblique aponeurosis
- Pierces the external spermatic fascia at the superficial inguinal ring to become subcutaneous
- Supplies the anterior one-third of the scrotum and the upper and medial part of the groin, down to the anterior axial line



B. POSTERIOR ABDOMINAL WALL

1. Arteries:

- Lumbar arteries
- Iliolumbar artery



Posterior
intercostal
arteries

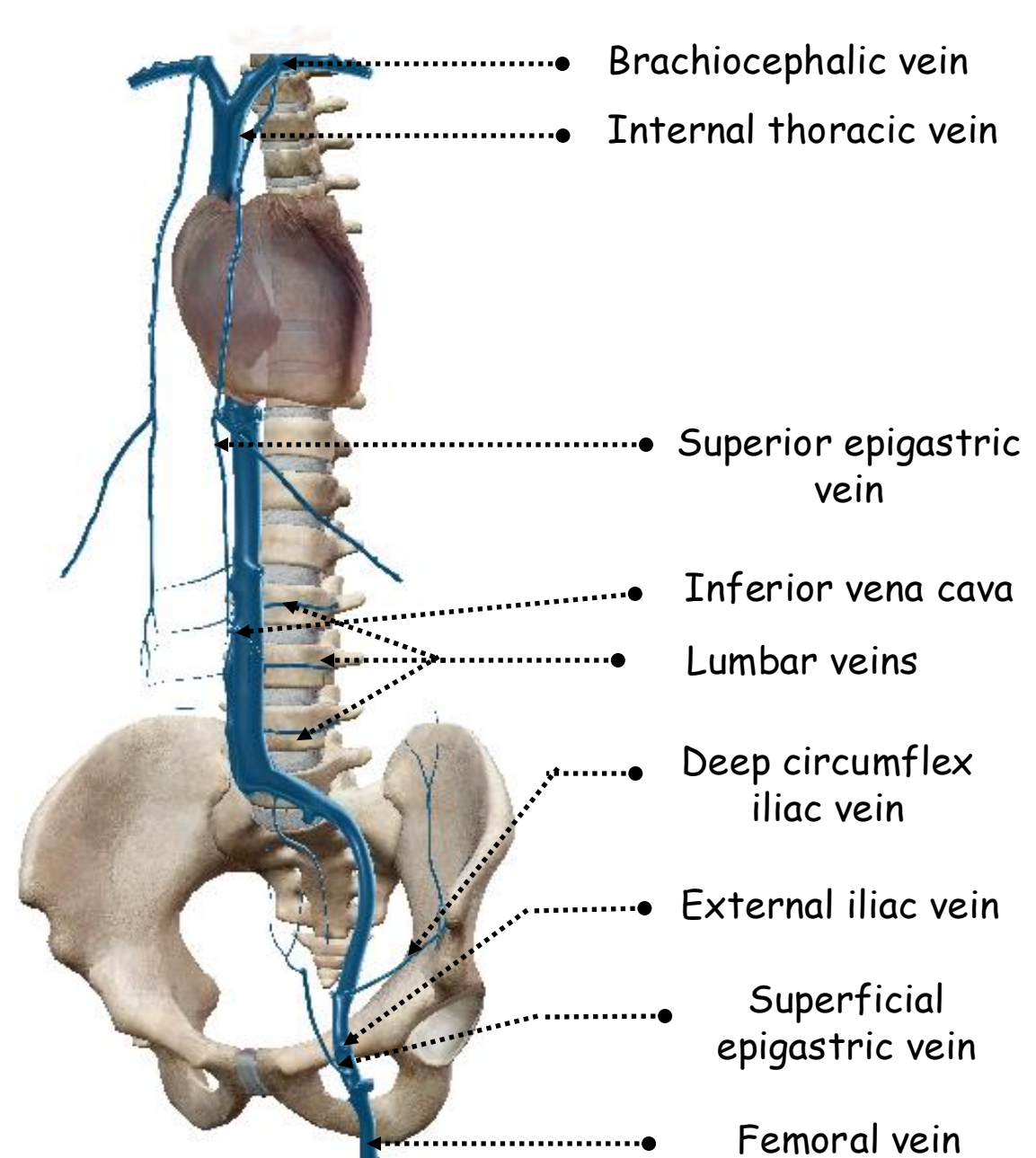
Aorta

Lumbar arteries

ANTERIOR VIEW OF THE SKELETON OF THE TRUNK SHOWING THE
ARTERIES OF THE POSTERIOR ABDOMINAL WALL

2. Veins:

- Lumbar veins
- Follow the arteries



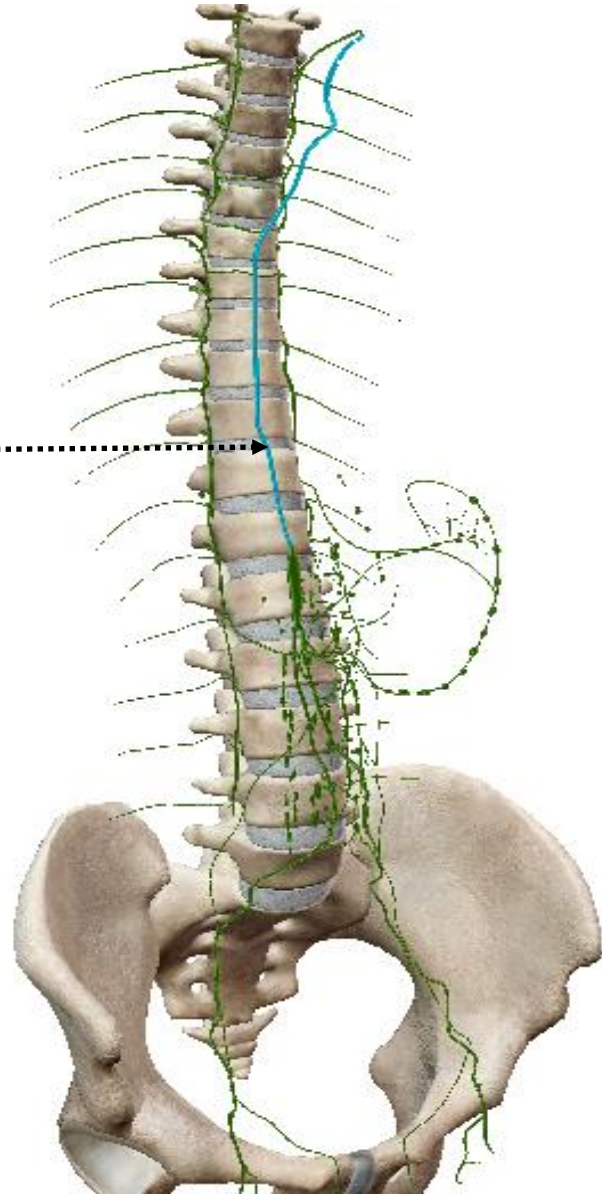
ANTERIOR VIEW OF THE SKELETON OF THE TRUNK SHOWING THE VEINS OF THE ABDOMINAL WALL

3. Lymph drainage:

- Direct to the thoracic duct



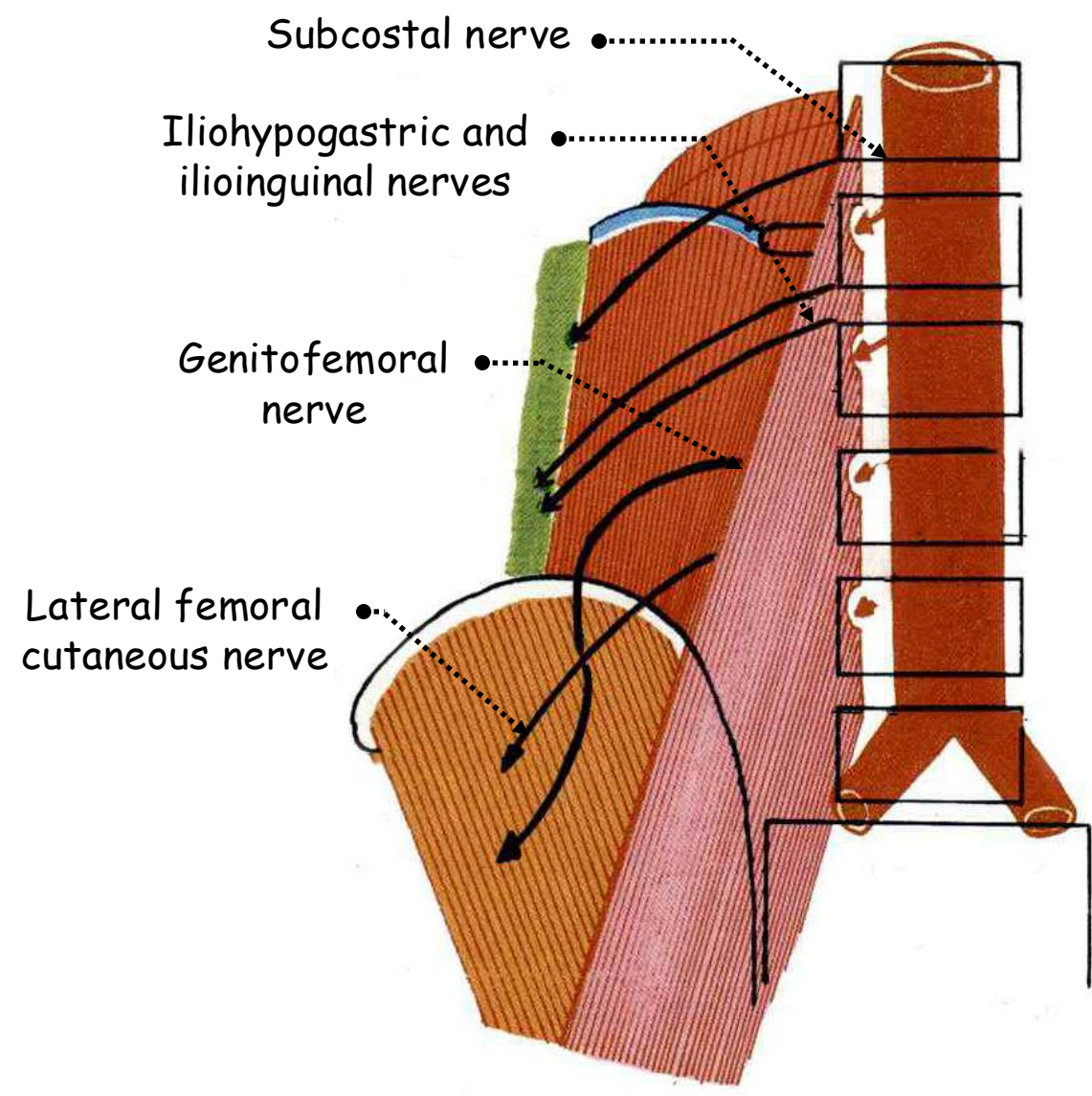

Thoracic duct



ANTERIOR LATERAL VIEW OF THE SKELETON OF THE TRUNK
SHOWING THE LYMPH DRAINAGE OF THE POSTERIOR ABDOMINAL
WALL

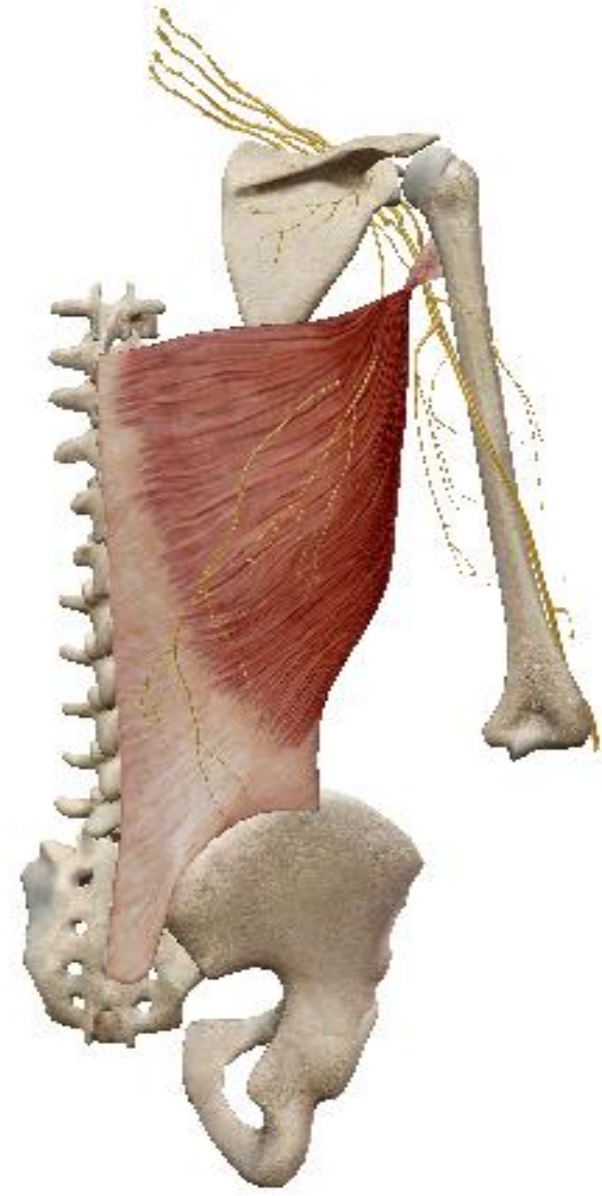

4. Nerves:

- Lumbar nerves



ANTERIOR VIEW OF THE POSTERIOR ABDOMINAL WALL SHOWING THE LUMBAR NERVES

- Rami of the brachial plexus



POSTERIOR VIEW OF THE SKELETON OF THE TRUNK SHOWING THE LATISSIMUS DORSI MUSCLE

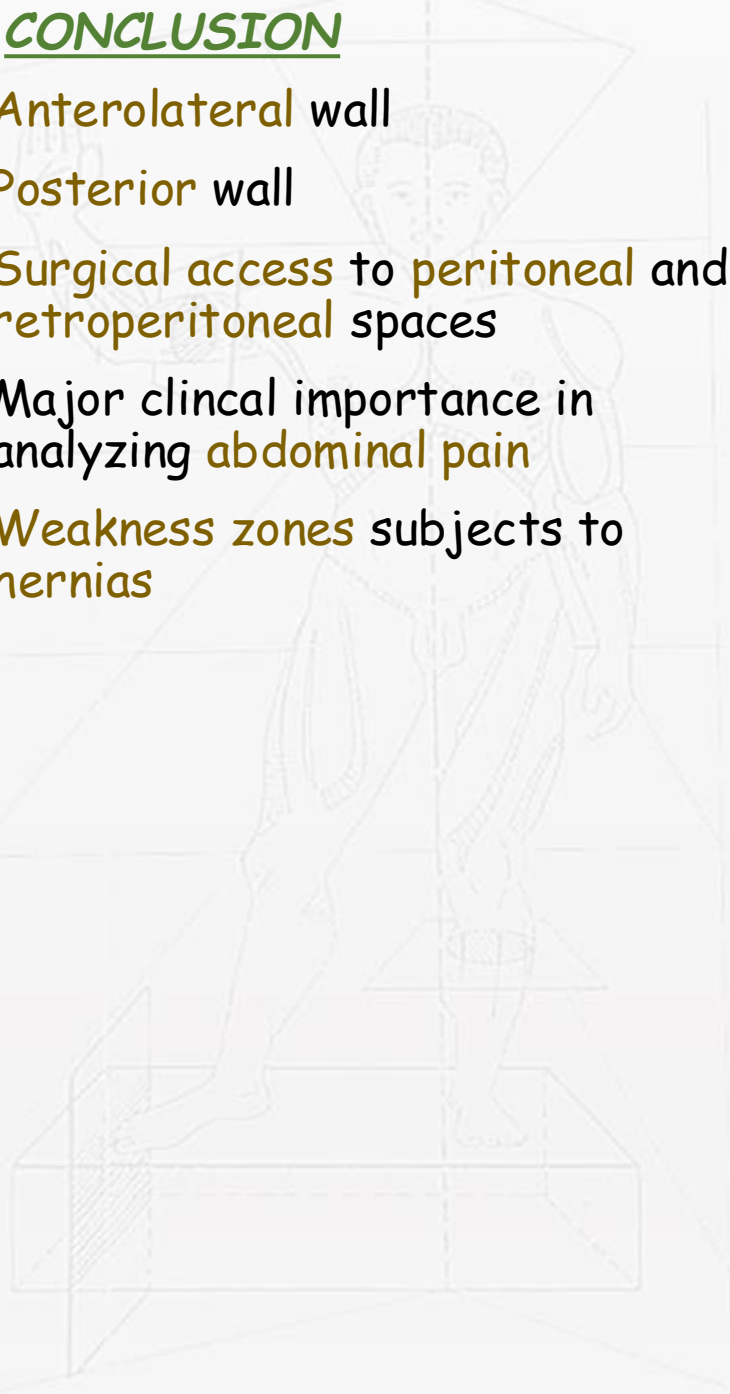
IV. SURGICAL APPROACH

- Midline incision
- Paramedian incision
- Right subcostal Kocher's incision
- Double Kocher rooftop incision
- Gridirion McBurney's incision
- Transverse muscle splitting incision
- Transverse muscle-cutting incisions
- Oblique muscle-cutting Rutherford Morison's incision
- Transverse Pfannenstiel's incision
- Lumbar incision



V. CONCLUSION

- Anterolateral wall
- Posterior wall
- Surgical access to peritoneal and retroperitoneal spaces
- Major clinical importance in analyzing abdominal pain
- Weakness zones subjects to hernias





كلية الطب
والصيدلة - مراكش
FACULTÉ DE MÉDECINE
ET DE PHARMACIE - MARRAKECH

